

Technical Support Center: Managing Asoprisnil-Induced Endometrial Changes in Long-Term Studies

Author: BenchChem Technical Support Team. **Date:** December 2025

Compound of Interest

Compound Name: *Asoprisnil*

Cat. No.: *B1665293*

[Get Quote](#)

This technical support center provides guidance for researchers, scientists, and drug development professionals on managing endometrial changes observed during long-term studies with **Asoprisnil**, a selective progesterone receptor modulator (SPRM).

Frequently Asked Questions (FAQs)

Q1: What is **Asoprisnil** and how does it affect the endometrium?

Asoprisnil is a selective progesterone receptor modulator (SPRM) with partial agonist and antagonist effects on the progesterone receptor (PR).[1][2] In the endometrium, it primarily exerts an antagonistic, antiproliferative effect.[1][3] This action inhibits the normal proliferative changes directed by estrogen, leading to a unique set of histological features.[1] While it suppresses menstruation, it does so without causing estrogen deprivation.

Q2: What are the typical endometrial changes observed in long-term **Asoprisnil** studies?

Long-term, uninterrupted treatment with **Asoprisnil** is associated with a class effect of SPRMs known as Progesterone Receptor Modulator Associated Endometrial Changes (PAEC). These changes are characterized by:

- Increased endometrial thickness: A dose- and time-dependent increase in endometrial thickness is a common finding.

- Cystic changes: Imaging studies often reveal cystic dilation of the endometrial glands.
- Histological features: PAEC is histologically distinct from endometrial hyperplasia and is characterized by cystically dilated glands, inactive-appearing epithelium with few mitotic figures, and a compact, non-decidualized stroma.

Q3: Are the **Asoprisnil**-induced endometrial changes reversible?

Yes, the endometrial changes associated with **Asoprisnil**, including increased thickness and PAEC, appear to be reversible upon discontinuation of treatment. Studies have shown a trend of regression toward the baseline endometrial pattern after stopping the drug.

Q4: What are the potential risks associated with long-term **Asoprisnil** treatment regarding the endometrium?

While PAEC is generally considered benign, long-term uninterrupted use of **Asoprisnil** has raised endometrial safety concerns. An extension study reported a progressive increase in endometrial thickness and cystic changes, which prompted invasive diagnostic procedures. Importantly, two cases of endometrial cancer were diagnosed during this long-term extension study, leading to the recommendation to avoid uninterrupted long-term treatment. The clinical development of **Asoprisnil** was ultimately halted due to these safety concerns.

Q5: How should endometrial changes be monitored during **Asoprisnil** clinical trials?

A multi-modal approach to endometrial monitoring is crucial. This should include:

- Transvaginal Ultrasound (TVU): For regular assessment of endometrial thickness.
- Magnetic Resonance Imaging (MRI): Can provide more detailed imaging of endometrial morphology, including cystic changes.
- Endometrial Biopsy with Histopathological Evaluation: This is essential for differentiating PAEC from endometrial hyperplasia or malignancy.

Troubleshooting Guide

Observed Issue	Potential Cause	Recommended Action
Significant increase in endometrial thickness on TVU	Asoprisnil-induced PAEC	- Correlate with clinical symptoms.- Proceed with endometrial biopsy for histological confirmation.
Cystic appearance of the endometrium on imaging	Characteristic feature of PAEC	- Document findings.- An endometrial biopsy is recommended to rule out other pathologies.
Histopathology report mentions "Progesterone Receptor Modulator Associated Endometrial Changes (PAEC)"	Expected class effect of Asoprisnil	- This is an anticipated finding and is considered benign.- Continue monitoring as per protocol.
Histopathology report is inconclusive or suggests endometrial hyperplasia	Potential for atypical changes	- An expert gynecologic pathologist should review the biopsy.- Consider a repeat biopsy or hysteroscopy with directed biopsy.
Patient develops unscheduled uterine bleeding	While Asoprisnil typically induces amenorrhea, breakthrough bleeding can occur.	- Rule out other causes of bleeding.- Perform a TVU and consider an endometrial biopsy to assess the endometrium.

Quantitative Data Summary

Table 1: Mean Change in Endometrial Thickness (mm) from Baseline in a 12-Month Placebo-Controlled Study

Treatment Group	Month 6	Month 12
Placebo	Not Statistically Significant	-
Asoprisnil 10 mg	Not Statistically Significant	~2 mm increase (P<0.01 vs placebo)
Asoprisnil 25 mg	Not Statistically Significant	~2 mm increase (P<0.01 vs placebo)

Data from pooled analysis of two 12-month randomized controlled trials.

Table 2: Mean Endometrial Thickness (mm) in a 12-Month Extension Study (Total 24 Months of Treatment)

Treatment Group	Day 1 of Extension Study (Month 12 of initial study)	Month 12 of Extension Study (Month 24 total)	Mean Increase from Initial Baseline at Month 24
Asoprisnil 10 mg	9.4 (SD 8.8)	10.9 (SD 9.3)	3.4 (SD 9.8)
Asoprisnil 25 mg	9.7 (SD 8.1)	13.9 (SD 13.2)	6.2 (SD 12.8)

Data from a 12-month extension study.

Experimental Protocols

Protocol 1: Endometrial Biopsy Procedure

Objective: To obtain a tissue sample of the endometrium for histopathological evaluation.

Materials:

- Speculum
- Antiseptic solution
- Tenaculum

- Uterine sound
- Endometrial suction catheter (e.g., Pipelle)
- Formalin-filled specimen container
- Sterile gloves and drapes

Procedure:

- Ensure informed consent is obtained from the participant.
- Position the patient in the dorsal lithotomy position.
- Insert a speculum to visualize the cervix.
- Cleanse the cervix with an antiseptic solution.
- If necessary, apply a tenaculum to the anterior lip of the cervix to stabilize the uterus.
- Gently introduce a uterine sound to determine the depth and direction of the uterine cavity.
- Insert the endometrial suction catheter through the cervical os into the uterine cavity until the fundus is reached.
- Withdraw the inner plunger of the catheter to create suction.
- Move the catheter in a rotating and back-and-forth motion to sample all areas of the endometrium.
- Withdraw the catheter and expel the collected tissue into a formalin-filled specimen container.
- Label the container appropriately and send it for histopathological analysis.

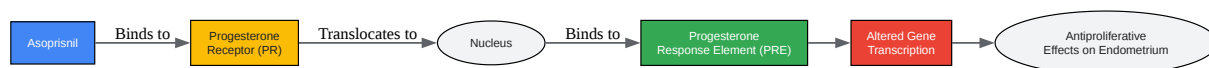
Protocol 2: Histopathological Evaluation of Endometrial Biopsies

Objective: To differentiate **Asoprisnil**-induced PAEC from other endometrial pathologies, such as hyperplasia or carcinoma.

Procedure:

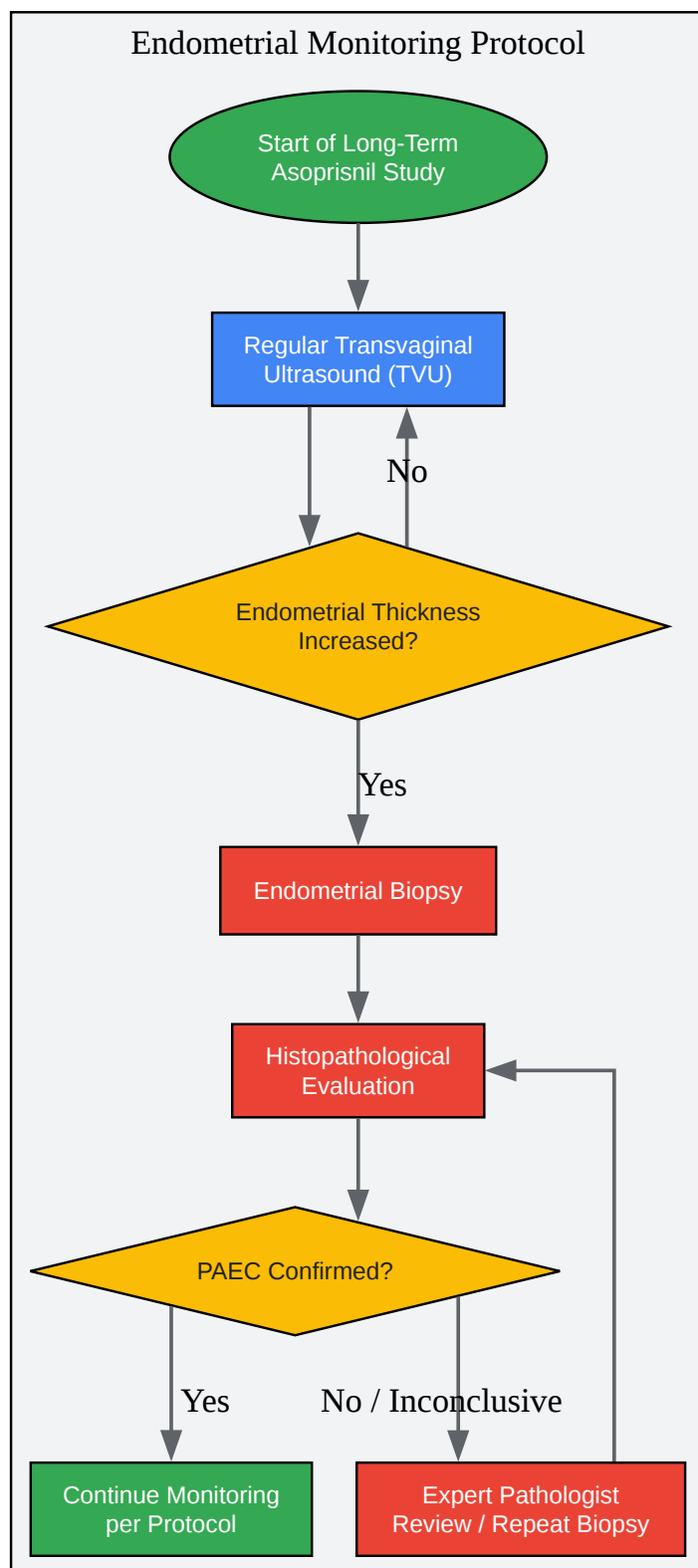
- Gross Examination: Document the aggregate volume and appearance of the tissue fragments.
- Tissue Processing: Dehydrate, clear, and embed the tissue in paraffin wax.
- Sectioning: Cut thin sections (4-5 μ m) from the paraffin block and mount them on glass slides.
- Staining: Stain the sections with Hematoxylin and Eosin (H&E).
- Microscopic Examination: A qualified pathologist should examine the slides, paying close attention to the following features:
 - Glandular architecture: Look for cystic dilation, which is characteristic of PAEC. Note the gland-to-stroma ratio.
 - Glandular epithelium: Assess for cellular stratification, nuclear atypia, and mitotic activity. In PAEC, the epithelium is typically inactive or shows non-physiologic secretory effects with rare mitoses.
 - Stroma: Evaluate the stromal cellularity and for the presence of decidualization. PAEC is associated with a compact, non-decidualized stroma.
 - Vessels: Note any changes in the stromal vessels.
- Immunohistochemistry (Optional): In cases where the diagnosis is uncertain, immunohistochemical staining for markers like Ki-67 (proliferation marker) and PTEN (tumor suppressor) may be considered.
- Reporting: The final report should clearly state the presence or absence of PAEC, endometrial hyperplasia, or malignancy.

Visualizations



[Click to download full resolution via product page](#)

Caption: **Asoprisnil's** mechanism of action on the endometrium.



[Click to download full resolution via product page](#)

Caption: Workflow for monitoring endometrial changes.

Need Custom Synthesis?

BenchChem offers custom synthesis for rare earth carbides and specific isotopic labeling.

Email: info@benchchem.com or [Request Quote Online](#).

References

- 1. ovid.com [ovid.com]
- 2. Asoprisnil (J867): a selective progesterone receptor modulator for gynecological therapy - PubMed [pubmed.ncbi.nlm.nih.gov]
- 3. academic.oup.com [academic.oup.com]
- To cite this document: BenchChem. [Technical Support Center: Managing Asoprisnil-Induced Endometrial Changes in Long-Term Studies]. BenchChem, [2025]. [Online PDF]. Available at: [https://www.benchchem.com/product/b1665293#managing-asoprisnil-induced-endometrial-changes-in-long-term-studies]

Disclaimer & Data Validity:

The information provided in this document is for Research Use Only (RUO) and is strictly not intended for diagnostic or therapeutic procedures. While BenchChem strives to provide accurate protocols, we make no warranties, express or implied, regarding the fitness of this product for every specific experimental setup.

Technical Support: The protocols provided are for reference purposes. Unsure if this reagent suits your experiment? [[Contact our Ph.D. Support Team for a compatibility check](#)]

Need Industrial/Bulk Grade? [Request Custom Synthesis Quote](#)

BenchChem

Our mission is to be the trusted global source of essential and advanced chemicals, empowering scientists and researchers to drive progress in science and industry.

Contact

Address: 3281 E Guasti Rd

Ontario, CA 91761, United States

Phone: (601) 213-4426

Email: info@benchchem.com