

Technical Support Center: Management of Post-DALK Infections

Author: BenchChem Technical Support Team. **Date:** December 2025

Compound of Interest

Compound Name: dALK-3

Cat. No.: B15575147

[Get Quote](#)

This technical support center provides troubleshooting guides and frequently asked questions (FAQs) for researchers, scientists, and drug development professionals managing infectious complications following Deep Anterior Lamellar Keratoplasty (DALK).

Frequently Asked Questions (FAQs)

Q1: What are the most common pathogens causing infections after DALK?

A1: Post-DALK infections are predominantly fungal, with *Candida* species being the most frequently isolated pathogen.[1][2][3][4] Bacterial infections are less common but can also occur, with reported cases including *Klebsiella pneumoniae* and mycobacteria.[5] The sequestered graft-host interface may create a hypoxic environment conducive to fungal growth.[1][4]

Q2: When do infections typically present after DALK surgery?

A2: Infections can present from a few days to several months post-surgery.[5] A review of literature found that the majority of cases (87%) occurred within the first 3 months after the procedure.[6] Early-onset cases (within days) may have a more rapid progression.[5]

Q3: What are the typical clinical signs of a post-DALK interface infection?

A3: Interface infectious keratitis (IIK) is a unique complication of lamellar procedures.[7] It is often characterized by white or cream-colored deposits scattered at the graft-host interface with

minimal overlying inflammation.[5] Other signs can include conjunctival injection, stromal edema, and endothelial plaques in fungal cases.[6] In some instances, it might be misdiagnosed as non-infectious inflammation or graft rejection.[5]

Q4: What are the primary risk factors for developing an infection after DALK?

A4: Risk factors can be categorized into host status, surgical factors, and post-operative management.[8] Key factors include pre-existing ocular surface disease, persistent epithelial defects, and long-term use of topical corticosteroids.[8][9][10] Donor-to-host transmission is also a significant concern, with a number of cases linked to positive donor rim cultures, especially for fungal infections.[1][2][5]

Q5: Are topical antimicrobials effective for treating post-DALK interface infections?

A5: The effectiveness of topical antimicrobials is often limited due to the deep, sequestered location of the infection at the graft-host interface, which impairs drug penetration.[2][3][4][5] While they are a mainstay of initial treatment, many cases of interface keratitis do not respond to topical therapy alone and require more invasive interventions.[3][5]

Q6: What are the surgical options if medical therapy fails?

A6: If medical therapy is unsuccessful, surgical intervention is often necessary.[5] Options include:

- Interface Irrigation/Wash: Antimicrobial agents are injected directly into the interface.[5][9]
- Graft Removal/Exchange: The infected lamellar graft can be removed, allowing the surface to heal with antimicrobial treatment, followed by a secondary DALK or a penetrating keratoplasty (PKP).[5][9] Recurrences have been reported after repeat DALK, sometimes necessitating a PKP.[7][9]
- Therapeutic Penetrating Keratoplasty (PKP): In cases with non-responding infiltrates or corneal perforation, a full-thickness graft (PKP) may be required.[7][9] Early excisional PKP has shown high therapeutic efficacy and good visual outcomes.[2][4]

Troubleshooting Guides

Guide 1: Initial Management of a Suspected Post-DALK Infection

Problem: A patient presents with signs of inflammation or infiltration at the graft-host interface post-DALK.

Steps:

- **Clinical Examination:** Perform a thorough slit-lamp examination to assess the location, depth, and characteristics of the infiltrate. Note any signs of anterior chamber reaction.
- **Discontinue Corticosteroids:** Immediately stop all topical corticosteroid treatments to avoid worsening a potential infection.[3]
- **Attempt Microbiological Sampling:** Due to the deep location, standard corneal scraping is often not possible. Consider the following:
 - **Confocal Microscopy:** Can help visualize fungal hyphae or other microorganisms in vivo, aiding in a presumptive diagnosis.[5]
 - **Localized Biopsy:** For paracentral infiltrates, localized removal of the overlying epithelium and debulking of the infiltrate with forceps can provide a sample for microbiological analysis.[3]
- **Initiate Empirical Therapy:** While awaiting diagnostic results, start empirical broad-spectrum antimicrobial therapy. This typically includes intensive topical fortified antibiotics and antifungals (e.g., voriconazole).[3][4]
- **Monitor Closely:** Re-evaluate the patient frequently (e.g., every 24-48 hours) to assess the response to treatment.

Guide 2: Non-Responsive Interface Infiltrate After 72 Hours of Topical Therapy

Problem: The interface infiltrate is worsening or showing no improvement despite intensive topical antimicrobial therapy.

Steps:

- Re-evaluate Diagnosis: Use confocal microscopy if not already performed to confirm the presence of infectious organisms and rule out non-infectious causes.
- Consider Intrastromal/Interface Injections: For deep-seated infections, targeted delivery of antimicrobials can be more effective. Intrastromal or interface injections of agents like voriconazole have been shown to resolve recalcitrant fungal keratitis.[9]
- Prepare for Surgical Intervention: If the infection continues to progress, medical therapy is likely to fail. Counsel the patient on the need for surgery.
- Choose Surgical Approach:
 - Less Invasive: Attempting a graft lift and interface wash/irrigation with antimicrobial agents. [5]
 - More Definitive: Proceed with the removal of the DALK graft (keratectomy) followed by a therapeutic penetrating keratoplasty (PKP).[2][5] This is often the most effective treatment for eradicating the infection.[2][4]

Quantitative Data Summary

Table 1: Causative Organisms in Post-Lamellar Keratoplasty Interface Infections

Organism Type	Most Common Genera/Species	Reference
Fungi	Candida spp. (C. albicans, C. glabrata)	[1][2][4]
Aspergillus spp.	[5]	
Bacteria	Gram-positives (S. pneumoniae, S. aureus)	[11]
Gram-negatives (K. pneumoniae, Rhodococcus equi)	[5]	
Mycobacteria, Nocardia	[5]	
Protozoa	Acanthamoeba	[12][13]

Table 2: Treatment Outcomes for Post-DALK Interface Infectious Keratitis (IIK)

Treatment Modality	Success Rate / Outcome	Notes	Reference
Topical & Systemic Medical Therapy Alone	Generally low efficacy for deep interface infections.	Often requires adjunct surgical intervention.	[2][4]
Intrastromal Voriconazole Injection	Resolved 72% of deep recalcitrant fungal keratitis in one study.	Useful for non-responding deep infections.	[9]
Graft Removal / Exchange	Variable success; recurrences have been reported.	May be followed by a secondary DALK or PKP.	[5][7][9]
Therapeutic Penetrating Keratoplasty (PKP)	High success in eradicating infection; considered the most effective treatment.	A clear graft was achieved in 23-81% of eyes post-PKIK treatment.	[2][4][9]

Experimental Protocols

Protocol 1: Corneal Scraping and Microbiological Workup

- Objective: To obtain a sample from a corneal infiltrate for microbiological identification.
- Methodology:
 - Anesthesia: Instill a topical anesthetic (e.g., proparacaine hydrochloride 0.5%).
 - Sampling: For interface keratitis, if the infiltrate is accessible (e.g., paracentral), gently remove the overlying epithelium with a sterile blade. Use a sterile spatula or forceps to carefully collect material from the infiltrate's leading edge and base.[\[3\]](#)
 - Smear Preparation: Smear the collected material directly onto glass slides for Gram stain, Giemsa stain, and Potassium Hydroxide (KOH) wet mount.
 - Culture Inoculation: Inoculate the remaining material directly onto culture media:
 - Bacterial: Blood agar, chocolate agar, thioglycolate broth.
 - Fungal: Sabouraud dextrose agar (without cycloheximide).
 - Acanthamoeba: Non-nutrient agar with an E. coli overlay.
 - Incubation: Incubate plates at appropriate temperatures (37°C for bacteria, 25-30°C for fungi) and observe for growth for several weeks.

Protocol 2: In Vivo Confocal Microscopy (IVCM)

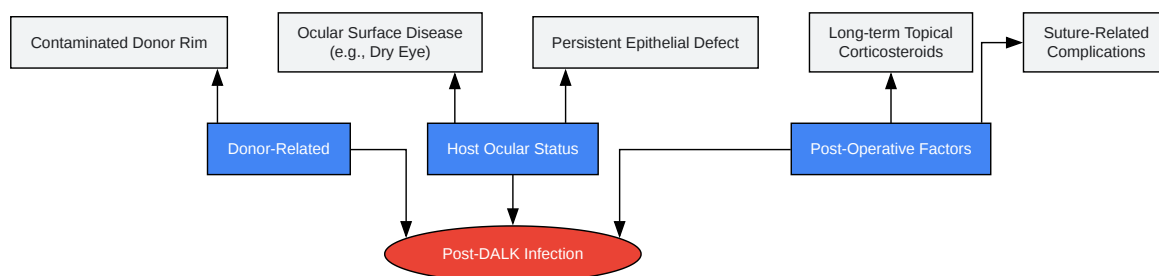
- Objective: Non-invasive, real-time imaging of the corneal microstructure to aid in the rapid presumptive diagnosis of infectious keratitis.
- Methodology:
 - Anesthesia: Instill a topical anesthetic.

- Coupling Gel: Apply a sterile, viscous coupling gel to the tip of the microscope objective lens.
- Applanation: Gently applanate the cornea with the objective lens.
- Imaging: Systematically scan through the corneal layers, from the epithelium down to the endothelium, focusing on the graft-host interface.
- Image Interpretation:
 - Fungal Filaments: Appear as hyper-reflective, branching, linear structures (hyphae).
 - Acanthamoeba: May appear as hyper-reflective, double-walled cysts or ovoid trophozoites.
 - Bacteria: Difficult to detect reliably, but large filamentous bacteria like Nocardia may be visualized.[5]

Visualizations

Caption: Diagnostic workflow for suspected post-DALK infection.

Caption: Treatment algorithm for refractory post-DALK interface keratitis.



[Click to download full resolution via product page](#)

Caption: Key risk factors contributing to post-DALK infections.

Need Custom Synthesis?

BenchChem offers custom synthesis for rare earth carbides and specific isotopic labeling.

Email: info@benchchem.com or [Request Quote Online](#).

References

- 1. bjo.bmj.com [bjo.bmj.com]
- 2. Interface infectious keratitis after anterior and posterior lamellar keratoplasty. Clinical features and treatment strategies. A review - PubMed [pubmed.ncbi.nlm.nih.gov]
- 3. Interface infectious keratitis following deep anterior lamellar keratoplasty - PMC [pmc.ncbi.nlm.nih.gov]
- 4. bjo.bmj.com [bjo.bmj.com]
- 5. Current Concepts in the Management of Unique Post-keratoplasty Infections - PMC [pmc.ncbi.nlm.nih.gov]
- 6. Infectious interface keratitis (IIK) following lamellar keratoplasty: A literature review - PubMed [pubmed.ncbi.nlm.nih.gov]
- 7. Post-keratoplasty Infectious Keratitis: Epidemiology, Risk Factors, Management, and Outcomes - PMC [pmc.ncbi.nlm.nih.gov]
- 8. mdpi.com [mdpi.com]
- 9. Frontiers | Post-keratoplasty Infectious Keratitis: Epidemiology, Risk Factors, Management, and Outcomes [frontiersin.org]
- 10. Complications After DALK | Ento Key [entokey.com]
- 11. Microbial keratitis in corneal grafts | Eye News [eyenews.uk.com]
- 12. anncaserep.com [anncaserep.com]
- 13. ophthalmologytimes.com [ophthalmologytimes.com]
- To cite this document: BenchChem. [Technical Support Center: Management of Post-DALK Infections]. BenchChem, [2025]. [Online PDF]. Available at: [https://www.benchchem.com/product/b15575147#management-of-post-dalk-infections]

Disclaimer & Data Validity:

The information provided in this document is for Research Use Only (RUO) and is strictly not intended for diagnostic or therapeutic procedures. While BenchChem strives to provide accurate protocols, we make no warranties, express or implied, regarding the fitness of this product for every specific experimental setup.

Technical Support: The protocols provided are for reference purposes. Unsure if this reagent suits your experiment? [[Contact our Ph.D. Support Team for a compatibility check](#)]

Need Industrial/Bulk Grade? [Request Custom Synthesis Quote](#)

BenchChem

Our mission is to be the trusted global source of essential and advanced chemicals, empowering scientists and researchers to drive progress in science and industry.

Contact

Address: 3281 E Guasti Rd
Ontario, CA 91761, United States
Phone: (601) 213-4426
Email: info@benchchem.com