

# Technical Support Center: Management of Post-DALK Astigmatism

**Author:** BenchChem Technical Support Team. **Date:** December 2025

## Compound of Interest

Compound Name: dALK-3

Cat. No.: B15575147

[Get Quote](#)

This technical support center provides researchers, scientists, and drug development professionals with comprehensive troubleshooting guides and frequently asked questions (FAQs) for addressing astigmatism following Deep Anterior Lamellar Keratoplasty (DALK) surgery.

## Frequently Asked Questions (FAQs)

Q1: What are the common causes of astigmatism after DALK surgery?

High degrees of astigmatism are a common cause of unsatisfactory vision after DALK.<sup>[1]</sup> Several factors can contribute to post-operative astigmatism, including:

- **Suturing Technique:** Unevenly distributed tension in the sutures used to secure the donor cornea can lead to an irregular corneal shape.<sup>[2]</sup>
- **Wound Healing:** Individual variations in the healing process at the graft-host interface can induce astigmatism.<sup>[3]</sup>
- **Donor and Recipient Tissue Disparity:** Mismatches in the size or thickness between the donor and recipient corneal tissue can contribute to post-operative refractive errors.<sup>[2]</sup>
- **Pre-existing Corneal Shape:** The underlying shape of the recipient's cornea, even after removal of the diseased tissue, can influence the final corneal curvature.

Q2: What are the primary treatment options for managing post-DALK astigmatism?

A range of surgical interventions are available to correct astigmatism after DALK surgery. The choice of procedure depends on the degree of astigmatism, the patient's overall ocular health, and the surgeon's preference. Key options include:

- Relaxing Incisions (RI) / Astigmatic Keratotomy (AK): These procedures involve making precise incisions in the cornea to relax the steeper meridian and reduce astigmatism.[4][5] Femtosecond lasers can be used for greater precision in creating these incisions (Femtosecond Laser-Assisted Astigmatic Keratotomy - FSAK).[6][7]
- Laser Vision Correction (LASIK and PRK): Both Femtosecond-assisted LASIK (Femto-LASIK) and Photorefractive Keratectomy (PRK) can be effective in correcting residual astigmatism after DALK by reshaping the cornea with an excimer laser.[8][9][10]
- Toric Intraocular Lenses (IOLs): For patients who also require cataract surgery, implanting a toric IOL can correct both the cataract and the pre-existing astigmatism in a single procedure.[1][11]
- Intrastromal Corneal Ring Segments (ICRS): These small, implantable devices can help to reshape the cornea and reduce astigmatism.[12]
- Repeat DALK: In cases of very high astigmatism that are refractory to other treatments, a repeat DALK with a larger diameter graft may be considered.[13]

Q3: When is the appropriate time to intervene for post-DALK astigmatism?

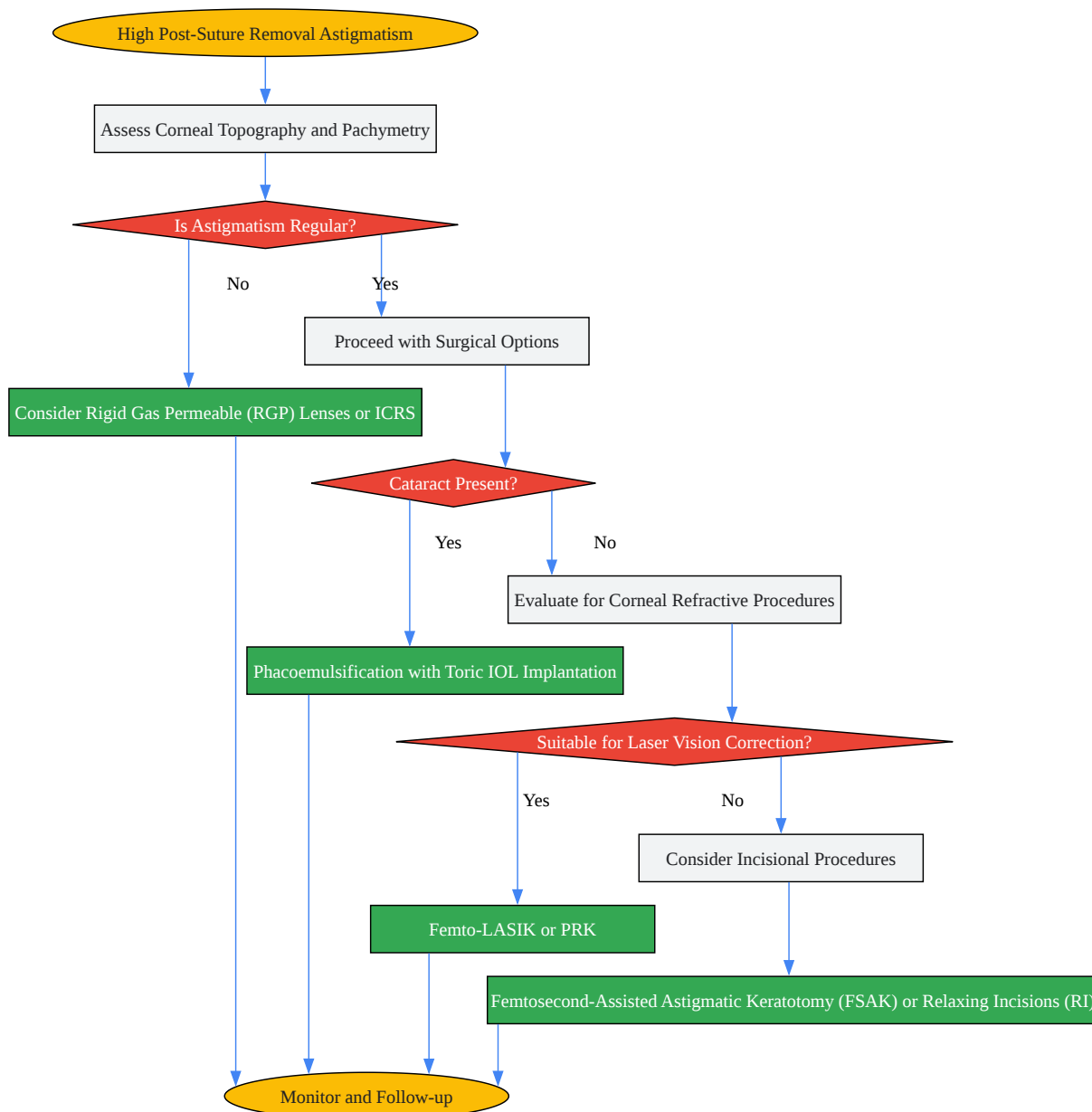
It is generally recommended to wait until the refractive error has stabilized before considering surgical correction for post-DALK astigmatism. This typically occurs at least 6 months after the complete removal of all sutures.[10][14]

## Troubleshooting Guides

### Guide 1: Persistent High Astigmatism After Suture Removal

**Problem:** The patient exhibits significant and stable astigmatism (>5.0 D) more than six months after all sutures have been removed, and this is not correctable with spectacles or contact lenses.

Troubleshooting Workflow:



[Click to download full resolution via product page](#)

Caption: Decision workflow for managing high post-suture removal astigmatism.

## Guide 2: Complications Following Astigmatism Correction

Problem: The patient experiences a complication after a procedure to correct post-DALK astigmatism.

Complication	Potential Cause(s)	Recommended Action(s)
Overcorrection or Undercorrection	Inaccurate pre-operative measurements, unpredictable wound healing.	Monitor for stability. Consider enhancement procedure if visually significant and stable.
Regression	Long-term corneal remodeling, especially in eyes with a history of radial keratotomy. [14]	Monitor refractive error. May require further intervention if significant.
Corneal Haze	Common after PRK, especially without Mitomycin C.[8]	Typically resolves over time. Manage with topical steroids as prescribed.
Microperforation	Incision depth during relaxing incisions.[4]	Often self-sealing. Monitor for Descemet's detachment or double anterior chamber.[4]
Graft Rejection	Inflammatory response to the surgical intervention.	Immediate and aggressive treatment with topical corticosteroids.

## Quantitative Data on Treatment Outcomes

Treatment Modality	Mean Astigmatism Reduction (Diopters)	Key Findings and Complications	Reference(s)
Office-Based Relaxing Incisions	$2.95 \pm 3.43$ D (subtraction) $5.16 \pm 2.97$ D (vector)	Safe and effective office-based procedure. Microperforation occurred in one case but resolved spontaneously.	[4]
Femto-LASIK	Refractive cylinder reduced from $-3.88 \pm 1.00$ D to $-0.93 \pm 0.39$ D	Safe and effective for residual astigmatism. 70% of eyes gained lines of corrected distance visual acuity. Refractive stability was observed in 80% of eyes.	[9][10][14]
PRK with Mitomycin C	Pre-op mean SE $-4.98 \pm 1.75$ D to post-op $0.28 \pm 0.61$ D	Safe and effective for myopia and regular myopic astigmatism. A 6% undercorrection is planned to compensate for the effect of MMC.	[8]
Femtosecond Laser-Assisted Astigmatic Keratotomy (FSAK)	Reduction of 35.4% to 84.77% in post-keratoplasty astigmatism	Effective for high regular or irregular astigmatism. Potential for loss of visual acuity and low predictability.	

---

Toric IOLs	Significant reduction in astigmatism and improvement in visual acuity.	Effective for correcting corneal astigmatism in patients with cataracts post-DALK. Good rotational stability. <a href="#">[1]</a>
------------	------------------------------------------------------------------------	-----------------------------------------------------------------------------------------------------------------------------------

---

## Experimental Protocols

### Protocol 1: Office-Based Relaxing Incision Procedure

Objective: To reduce post-DALK astigmatism in a clinical setting.

Methodology:

- Pre-operative Assessment: Determine the location and extent of the steep semi-meridians using corneal topography.
- Anesthesia: Administer topical anesthetic drops to the operative eye.
- Incision:
  - Perform the procedure at a slit-lamp biomicroscope.
  - Use a 27-gauge needle to create relaxing incisions at the donor-recipient interface on one side of the steepest meridian.
  - The arc length of the incision should be between 45° to 60°.
  - The initial depth of the incision should be approximately 70-80% of the corneal thickness. [\[4\]](#)[\[15\]](#)
- Intra-operative Assessment: After 30-40 minutes, perform corneal topography to assess the initial effect.
- Enhancement: If the desired astigmatic correction is not achieved, the initial incision can be enhanced in depth and length. If necessary, a second incision can be made at the opposite semi-meridian during the same session.[\[4\]](#)[\[15\]](#)

- Post-operative Care: Prescribe topical antibiotics and corticosteroids. Monitor the patient for complications such as microperforation and graft rejection.

## Protocol 2: Femtosecond Laser-Assisted LASIK (Femto-LASIK)

Objective: To correct residual astigmatism after DALK using an excimer laser.

Methodology:

- Pre-operative Planning:
  - Ensure at least 6 months have passed since complete suture removal to allow for refractive stability.[\[10\]](#)
  - Perform detailed corneal topography and pachymetry.
- Surgical Procedure:
  - Create a corneal flap using a femtosecond laser. The flap diameter should be smaller than the graft diameter to ensure the hinge is within the donor tissue.
  - Lift the flap to expose the stromal bed.
  - Perform excimer laser ablation to correct the refractive error. The ablation should be centered on the pupil and confined within the graft.
  - Reposition the corneal flap.
- Post-operative Management:
  - Prescribe topical antibiotics and steroids.
  - Monitor for flap-related complications, graft failure, and corneal ectasia.[\[14\]](#)

## Protocol 3: Photorefractive Keratectomy (PRK) with Mitomycin C (MMC)

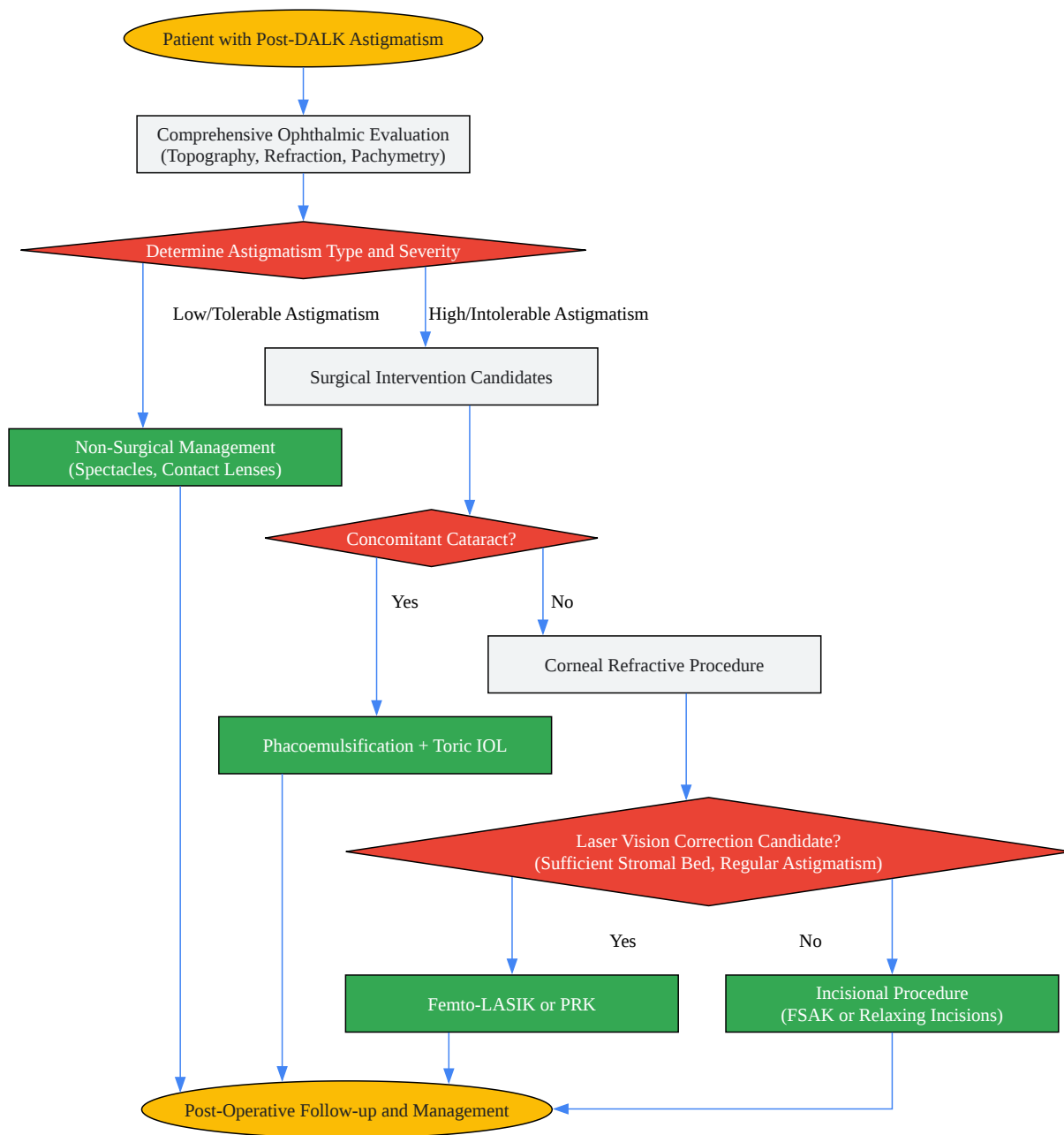
Objective: To correct myopic astigmatism after DALK.

Methodology:

- Pre-operative Evaluation: Assess for compound myopic astigmatism. Plan for a 6% undercorrection to account for the effect of MMC.[8]
- Surgical Procedure:
  - Administer topical anesthesia.
  - Remove the corneal epithelium using a preferred method (e.g., alcohol-assisted, mechanical debridement).
  - Perform excimer laser ablation to correct the refractive error.
  - Apply a sponge soaked in Mitomycin C (0.2 mg/mL) to the stromal bed for 45 seconds.[8]
  - Thoroughly irrigate the ocular surface with a balanced salt solution.
  - Place a bandage contact lens.
- Post-operative Care:
  - Prescribe topical antibiotics, steroids, and non-steroidal anti-inflammatory drugs.
  - Monitor for corneal haze and epithelial healing. The mean epithelialization time is approximately 4 days.[8]

## Signaling Pathways and Workflows





[Click to download full resolution via product page](#)

Caption: General workflow for the management of post-DALK astigmatism.

**Need Custom Synthesis?**

BenchChem offers custom synthesis for rare earth carbides and specific isotopic labeling.

Email: [info@benchchem.com](mailto:info@benchchem.com) or [Request Quote Online](#).

## References

- 1. Customized Toric Intraocular Lens Implantation in Eyes with Cataract and Corneal Astigmatism after Deep Anterior Lamellar Keratoplasty: A Prospective Study - PMC [pmc.ncbi.nlm.nih.gov]
- 2. scientificliterature.org [scientificliterature.org]
- 3. m.youtube.com [m.youtube.com]
- 4. Office-based Relaxing Incision Procedure for Correction of Astigmatism after Deep Anterior Lamellar Keratoplasty - PMC [pmc.ncbi.nlm.nih.gov]
- 5. Relaxing incisions combined with adjustment sutures for post-deep anterior lamellar keratoplasty astigmatism in keratoconus - PubMed [pubmed.ncbi.nlm.nih.gov]
- 6. Femtosecond laser-assisted astigmatic keratotomy: a review - PMC [pmc.ncbi.nlm.nih.gov]
- 7. mdpi.com [mdpi.com]
- 8. Photorefractive keratectomy with mitomycin C after deep anterior lamellar keratoplasty for keratoconus - PubMed [pubmed.ncbi.nlm.nih.gov]
- 9. Femto-LASIK after Deep Anterior Lamellar Keratoplasty to Correct Residual Astigmatism: A Long-Term Case Series Study - PubMed [pubmed.ncbi.nlm.nih.gov]
- 10. Femto-LASIK after Deep Anterior Lamellar Keratoplasty to Correct Residual Astigmatism: A Long-Term Case Series Study - PMC [pmc.ncbi.nlm.nih.gov]
- 11. Toric intraocular lenses for astigmatism correction after keratoplasty in phakic and pseudophakic eyes - PubMed [pubmed.ncbi.nlm.nih.gov]
- 12. dovepress.com [dovepress.com]
- 13. High Astigmatism After Conventional Diameter Deep Anterior Lamellar Keratoplasty in Keratoconus Can Be Successfully Managed With Repeat Wide Diameter Deep Anterior Lamellar Keratoplasty - PubMed [pubmed.ncbi.nlm.nih.gov]
- 14. mdpi.com [mdpi.com]

- 15. Office-based Relaxing Incision Procedure for Correction of Astigmatism after Deep Anterior Lamellar Keratoplasty - PubMed [pubmed.ncbi.nlm.nih.gov]
- To cite this document: BenchChem. [Technical Support Center: Management of Post-DALK Astigmatism]. BenchChem, [2025]. [Online PDF]. Available at: [https://www.benchchem.com/product/b15575147#addressing-astigmatism-after-dalk-surgery]

---

#### Disclaimer & Data Validity:

The information provided in this document is for Research Use Only (RUO) and is strictly not intended for diagnostic or therapeutic procedures. While BenchChem strives to provide accurate protocols, we make no warranties, express or implied, regarding the fitness of this product for every specific experimental setup.

**Technical Support:** The protocols provided are for reference purposes. Unsure if this reagent suits your experiment? [[Contact our Ph.D. Support Team for a compatibility check](#)]

**Need Industrial/Bulk Grade?** [Request Custom Synthesis Quote](#)

## BenchChem

Our mission is to be the trusted global source of essential and advanced chemicals, empowering scientists and researchers to drive progress in science and industry.

#### Contact

Address: 3281 E Guasti Rd  
Ontario, CA 91761, United States  
Phone: (601) 213-4426  
Email: [info@benchchem.com](mailto:info@benchchem.com)