

Technical Support Center: Improving Pyomyositis Diagnostic Specificity

Author: BenchChem Technical Support Team. **Date:** December 2025

Compound of Interest

Compound Name: *Piomy*

Cat. No.: *B1172056*

[Get Quote](#)

This technical support center provides researchers, scientists, and drug development professionals with detailed troubleshooting guides and frequently asked questions (FAQs) to enhance the specificity of diagnostic criteria for pyomyositis.

Frequently Asked Questions (FAQs)

Q1: What are the classic clinical stages of pyomyositis, and why is early-stage diagnosis so challenging?

A1: Pyomyositis typically progresses through three clinical stages. The initial stage often presents with nonspecific symptoms, leading to diagnostic delays.^[1]

- **Stage 1 (Invasive Stage):** Characterized by crampy, localized muscle pain, low-grade fever, and general malaise.^[1] At this point, there is no frank abscess, and the affected muscle may feel "woody" or indurated on palpation.^[1] Mild leukocytosis may be present.^[1] Aspiration of the muscle at this stage will not yield purulent material, making diagnosis difficult.^[1]
- **Stage 2 (Suppurative Stage):** Occurring 10 to 21 days after the onset of symptoms, this stage is marked by the formation of an abscess.^[1] Patients typically experience more intense pain, swelling, and fever. Aspiration of the muscle usually yields pus, which is a key diagnostic confirmation.^[1]
- **Stage 3 (Septic Stage):** If left untreated, the infection can progress to a systemic illness with signs of sepsis, such as high fever, and potentially septic shock.^[1]

The challenge in early diagnosis lies in the vague and non-specific nature of the initial symptoms, which can mimic more common conditions like muscle strain or a viral illness.

Q2: What are the expected laboratory findings in a patient with suspected pyomyositis, and how reliable are they?

A2: Laboratory findings in pyomyositis are often non-specific but can be valuable indicators of an underlying inflammatory or infectious process. Key laboratory markers include:

- **White Blood Cell (WBC) Count:** Leukocytosis (an elevated white blood cell count) is a common finding, often with a predominance of neutrophils.[\[2\]](#)[\[3\]](#)
- **Inflammatory Markers:** The Erythrocyte Sedimentation Rate (ESR) and C-Reactive Protein (CRP) levels are typically elevated, indicating an inflammatory response.[\[1\]](#)[\[3\]](#)
- **Blood Cultures:** While a positive blood culture can identify the causative organism, they are only positive in a minority of cases, with reported rates ranging from 5% to 38%.[\[4\]](#)[\[5\]](#)
- **Muscle Enzymes:** Serum creatine kinase (CK) levels are often normal or only slightly elevated, which can help differentiate pyomyositis from other myopathies.[\[4\]](#)

It is important to note that normal laboratory values do not exclude a diagnosis of pyomyositis, especially in the early stages.

Q3: What is the role of imaging in the diagnosis of pyomyositis, and which modality is considered the gold standard?

A3: Imaging is crucial for the diagnosis and management of pyomyositis. Magnetic Resonance Imaging (MRI) is considered the gold standard due to its high sensitivity for detecting early muscle inflammation and its ability to clearly delineate abscess formation.[\[4\]](#)

- **MRI:** Offers excellent soft tissue contrast and can detect muscle edema in the early, pre-suppurative stage.[\[4\]](#) It is also highly effective in identifying intramuscular abscesses, which appear as rim-enhancing fluid collections after the administration of contrast material.
- **Ultrasound (US):** A useful and readily available tool, particularly for superficial muscle groups.[\[4\]](#) It can identify fluid collections and guide needle aspiration for diagnostic and

therapeutic purposes. However, its sensitivity is lower for deep muscle involvement.

- Computed Tomography (CT): Can be used if MRI is unavailable or contraindicated. CT can show muscle enlargement and fluid collections, especially with contrast enhancement, but it is less sensitive than MRI for detecting early inflammatory changes.^[4]

Troubleshooting Guides

Problem: A patient presents with clinical signs suggestive of pyomyositis, but initial blood cultures are negative. How should I proceed to confirm the diagnosis?

Solution:

- **Prioritize Imaging:** Proceed with an MRI of the affected muscle group. MRI is highly sensitive for detecting the characteristic features of pyomyositis, even in the absence of positive blood cultures.^[4]
- **Image-Guided Aspiration:** If imaging reveals a fluid collection, perform an ultrasound- or CT-guided needle aspiration.^[4] This is the most direct method to obtain a sample for microbiological analysis.
- **Gram Stain and Culture of Aspirate:** Immediately perform a Gram stain on the aspirated fluid for preliminary identification of the causative organism and send the sample for both aerobic and anaerobic culture.
- **Consider Muscle Biopsy:** If no fluid collection is present but there is strong clinical suspicion and MRI findings of myositis, a muscle biopsy of the affected area can be considered for histopathological examination and tissue culture.

Problem: The initial ultrasound of a suspected pyomyositis is inconclusive. What are the next steps to improve diagnostic specificity?

Solution:

- **Proceed to MRI:** An inconclusive ultrasound should be followed by an MRI, which is the most sensitive imaging modality for pyomyositis.^[4] MRI can detect early muscle edema that may not be apparent on ultrasound and can better visualize deep muscle compartments.

- **Contrast-Enhanced Imaging:** If not already performed, a contrast-enhanced MRI is recommended. The characteristic rim enhancement of an abscess on post-contrast images significantly increases diagnostic specificity.
- **Correlate with Clinical and Laboratory Findings:** Re-evaluate the patient's clinical presentation and laboratory markers. Persistent fever, localized pain, and elevated inflammatory markers (CRP, ESR) in the context of a high clinical suspicion should prompt further investigation despite an initially negative or equivocal ultrasound.

Data Presentation

Table 1: Comparison of Imaging Modalities for the Diagnosis of Pyomyositis

Imaging Modality	Sensitivity	Specificity	Key Advantages	Key Limitations
MRI	High (reported as high as 97% for musculoskeletal infections)[4]	High	Excellent soft tissue contrast, detects early inflammation and edema, accurately delineates abscesses.[4]	Higher cost, longer acquisition time, potential contraindications (e.g., pacemakers).
Ultrasound	Variable (reported as 92-100% for abscess detection in some studies, but operator dependent)[6]	Lower than MRI	Readily available, low cost, no ionizing radiation, useful for guiding aspiration.[4]	Operator dependent, limited visualization of deep muscle groups, less sensitive in the early, non-suppurative stage.[4]
CT	Moderate	Moderate	Faster than MRI, good for detecting bone involvement and gas formation.	Less sensitive than MRI for early muscle inflammation, exposure to ionizing radiation, may not definitively differentiate abscess from phlegmon without contrast. [4]

Table 2: Common Laboratory Findings in Pyomyositis

Laboratory Finding	Reported Prevalence in Pyomyositis Patients	Clinical Significance
Leukocytosis	Frequently reported, though percentages vary	Indicates a systemic inflammatory response to infection. [2] [3]
Elevated ESR	Commonly elevated	A non-specific marker of inflammation. [1] [3]
Elevated CRP	Commonly elevated	A more sensitive and rapidly responsive marker of inflammation than ESR. [1] [3]
Positive Blood Culture	5% - 38%	Confirms the causative organism but is often negative. [4] [5]
Normal/Slightly Elevated Creatine Kinase (CK)	Typical finding	Helps to differentiate pyomyositis from other myopathies characterized by significant muscle damage. [4]

Experimental Protocols

Protocol for Ultrasound-Guided Abscess Drainage

This protocol outlines the key steps for performing an ultrasound-guided percutaneous drainage of a muscle abscess.

- Pre-procedure Preparation:
 - Obtain informed consent from the patient.
 - Review coagulation parameters and correct any coagulopathy.
 - Perform a preliminary ultrasound to confirm the location, size, and depth of the abscess and to plan the safest access route, avoiding major blood vessels and nerves.[\[7\]](#)
- Patient Positioning and Sterile Preparation:

- Position the patient to allow for optimal access to the abscess.
- Prepare the skin over the target area with an antiseptic solution and drape sterilely.
- Local Anesthesia:
 - Infiltrate the skin and subcutaneous tissues along the planned needle track with a local anesthetic.^[7]
- Catheter Insertion (Seldinger Technique):
 - Under real-time ultrasound guidance, advance an introducer needle into the abscess cavity.
 - Confirm the needle position by aspirating pus.
 - Insert a guidewire through the needle into the abscess.
 - Remove the needle, leaving the guidewire in place.
 - Make a small skin incision at the guidewire entry site.
 - Pass a dilator over the guidewire to create a tract.
 - Advance a drainage catheter over the guidewire into the abscess cavity.
 - Remove the guidewire and secure the catheter to the skin.
- Post-procedure Care:
 - Connect the catheter to a drainage bag.
 - Monitor the patient's vital signs and the drainage output.
 - The catheter is typically left in place until drainage has significantly decreased and follow-up imaging confirms resolution of the collection.

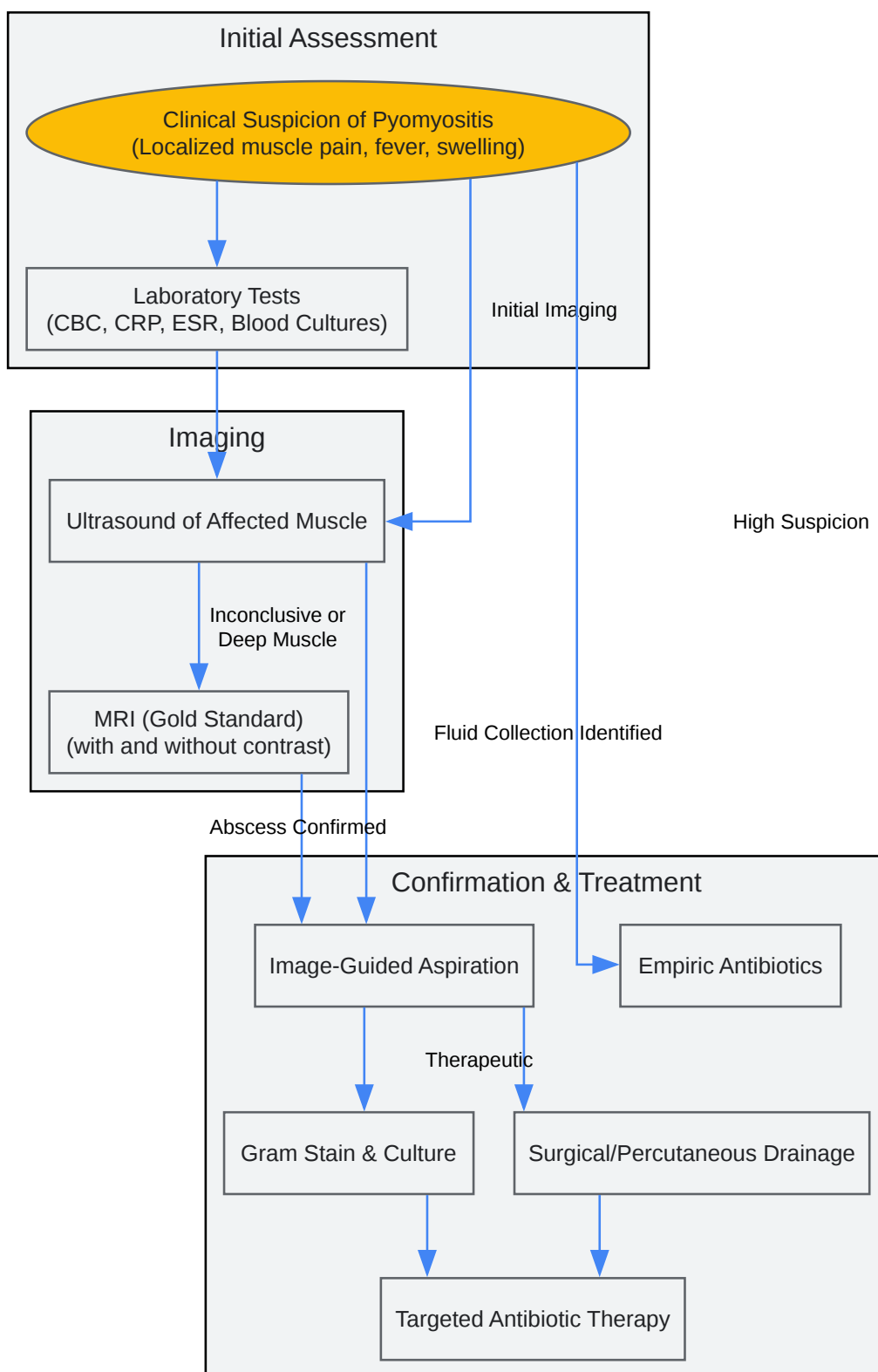
Protocol for Open Muscle Biopsy

This protocol provides a general outline for performing an open muscle biopsy for suspected myositis when other diagnostic methods are inconclusive.

- Pre-procedure Planning:
 - Obtain informed consent.
 - Select the biopsy site based on clinical findings and imaging (MRI or ultrasound) to target an affected but not end-stage muscle.[8] Avoid sites of recent EMG needle insertion or trauma.[8]
- Surgical Procedure:
 - Administer local or general anesthesia as appropriate.
 - Make a skin incision (approximately 4-6 cm) over the target muscle.[8]
 - Dissect through the subcutaneous tissue and fascia to expose the muscle belly.
 - Carefully excise a small, rectangular piece of muscle tissue (approximately 1.5 cm x 0.5 cm), ensuring the muscle fibers are oriented along the long axis of the specimen.[8]
 - Handle the specimen gently to avoid crush artifact.
- Specimen Handling:
 - Immediately wrap the fresh muscle specimen in a saline-moistened gauze (do not immerse in saline).
 - For histochemical analysis, the specimen should be rapidly frozen in isopentane cooled by liquid nitrogen.
 - For routine histology, a portion of the specimen can be placed in 10% neutral buffered formalin.
 - For electron microscopy, a small piece should be fixed in glutaraldehyde.
- Closure and Post-operative Care:

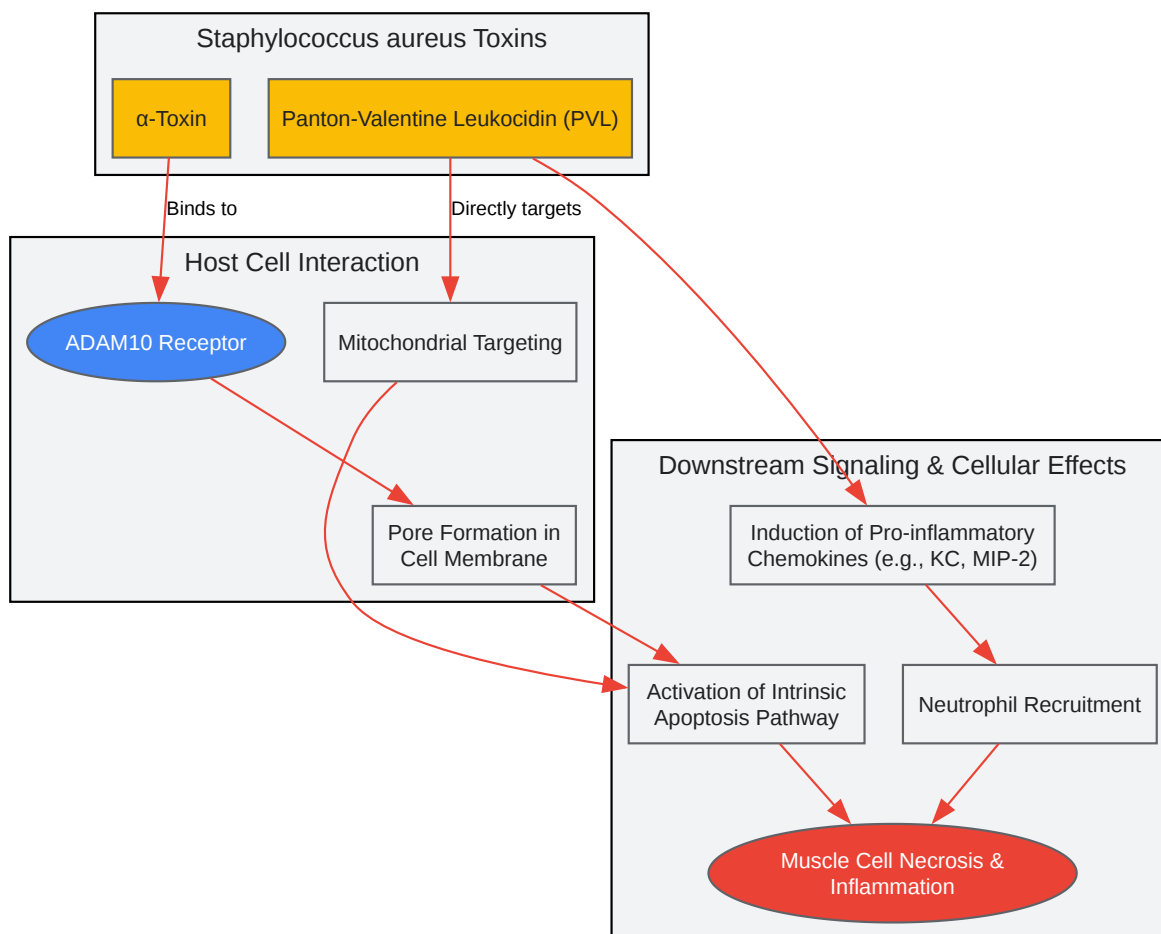
- Close the fascia and skin in layers.
- Provide appropriate post-operative wound care and pain management.

Mandatory Visualizations



[Click to download full resolution via product page](#)

Diagnostic workflow for pyomyositis.



[Click to download full resolution via product page](#)

Need Custom Synthesis?

BenchChem offers custom synthesis for rare earth carbides and specific isotopic labeling.

Email: info@benchchem.com or [Request Quote Online](#).

References

- 1. Primary Pyomyositis: Contact Sports as the Rare Risk Factors - PMC [pmc.ncbi.nlm.nih.gov]
- 2. Tropical Pyomyositis - PMC [pmc.ncbi.nlm.nih.gov]
- 3. Pyomyositis is not only a tropical pathology: a case series - PMC [pmc.ncbi.nlm.nih.gov]
- 4. droracle.ai [droracle.ai]
- 5. Primary pyomyositis: an unusual presentation in an older patient with no recognised risk factors - PMC [pmc.ncbi.nlm.nih.gov]
- 6. sdms.org [sdms.org]
- 7. Staphylococcus aureus Pantón-Valentine Leukocidin Contributes to Inflammation and Muscle Tissue Injury - PMC [pmc.ncbi.nlm.nih.gov]
- 8. Staphylococcus aureus Pantón-Valentine Leukocidin Contributes to Inflammation and Muscle Tissue Injury | PLOS One [journals.plos.org]
- To cite this document: BenchChem. [Technical Support Center: Improving Pyomyositis Diagnostic Specificity]. BenchChem, [2025]. [Online PDF]. Available at: [https://www.benchchem.com/product/b1172056#improving-the-specificity-of-diagnostic-criteria-for-pyomyositis]

Disclaimer & Data Validity:

The information provided in this document is for Research Use Only (RUO) and is strictly not intended for diagnostic or therapeutic procedures. While BenchChem strives to provide accurate protocols, we make no warranties, express or implied, regarding the fitness of this product for every specific experimental setup.

Technical Support: The protocols provided are for reference purposes. Unsure if this reagent suits your experiment? [[Contact our Ph.D. Support Team for a compatibility check](#)]

Need Industrial/Bulk Grade? [Request Custom Synthesis Quote](#)

BenchChem

Our mission is to be the trusted global source of essential and advanced chemicals, empowering scientists and researchers to drive progress in science and industry.

Contact

Address: 3281 E Guasti Rd

Ontario, CA 91761, United States

Phone: (601) 213-4426

Email: info@benchchem.com