

Technical Support Center: Histological Artifacts in Caerulein-Induced Pancreatitis

Author: BenchChem Technical Support Team. **Date:** December 2025

Compound of Interest

Compound Name: *Caerulein*

Cat. No.: *B1668201*

[Get Quote](#)

This technical support center provides troubleshooting guidance and frequently asked questions (FAQs) to assist researchers, scientists, and drug development professionals in identifying, preventing, and interpreting histological artifacts in **caerulein**-induced pancreatitis tissue samples.

Troubleshooting Guides

This section addresses specific issues that may arise during the histological preparation of pancreatic tissue from **caerulein**-induced pancreatitis models.

Question: Why does my H&E staining appear uneven, with some areas darker or lighter than others?

Answer: Uneven staining in pancreatic tissue can be attributed to several factors throughout the histological process.

- **Inadequate Fixation:** Delayed or incomplete fixation can lead to poor preservation of cellular details, resulting in inconsistent stain penetration.^[1] Ensure prompt immersion of tissue in a sufficient volume of fixative (at least 10:1 fixative-to-tissue ratio).
- **Improper Dehydration:** Incomplete dehydration can leave water in the tissue, which is immiscible with the clearing agent and paraffin, leading to patchy staining.^[2] Conversely, over-dehydration can make the tissue hard and brittle, also affecting stain uptake.^[2]

- **Residual Wax:** Failure to completely remove paraffin wax before staining will prevent the aqueous stains from penetrating the tissue sections, resulting in unstained or weakly stained areas.[\[2\]](#)
- **Stain Quality and Contamination:** Using expired or contaminated staining solutions can lead to precipitates on the tissue or inconsistent staining.[\[2\]](#)

Troubleshooting Steps:

- **Review Fixation Protocol:** Confirm that fresh fixative was used at the correct ratio and for an appropriate duration.
- **Check Processing Schedule:** Ensure the dehydration, clearing, and infiltration steps are of adequate duration for the tissue size.
- **Optimize Deparaffinization:** Increase the duration of xylene or other clearing agents prior to staining to ensure complete wax removal.
- **Filter Stains:** Filter hematoxylin and eosin solutions daily before use to remove any precipitates.

Question: My pancreatic tissue sections are detaching from the microscope slides. What is causing this and how can I prevent it?

Answer: Tissue detachment, or "floating," is a common issue that can ruin otherwise well-prepared sections.

- **Poor Adhesion:** The use of uncoated or improperly coated slides may not provide sufficient adhesion for the pancreatic tissue, which can be fragile, especially when inflamed.
- **Aggressive Staining or Washing:** Harsh washing steps or the use of certain reagents can weaken the bond between the tissue and the slide.
- **Incomplete Drying:** Sections that are not fully dried onto the slide before staining are more prone to detachment.

Troubleshooting Steps:

- **Use Adhesive Slides:** Employ positively charged or coated slides (e.g., with poly-L-lysine or organosilane) to enhance tissue adhesion.
- **Gentle Handling:** Be gentle during washing and reagent changes. Use a squeeze bottle with a fine tip to direct the flow of liquids away from the tissue.
- **Proper Drying:** Ensure sections are thoroughly dried in an oven or on a slide warmer at an appropriate temperature before deparaffinization and staining.
- **Clean Water Bath:** Contaminants in the flotation water bath can interfere with adhesion.[2]

Question: I am observing significant empty spaces and tissue separation (edema artifact) in my control tissue. How can I differentiate this from pathological edema?

Answer: Distinguishing true pathological edema from artifactual spaces is crucial for accurate interpretation.

- **Slow Fixation:** A delay in fixation allows for post-mortem changes, including cell swelling and separation, which can mimic edema.[1]
- **Aggressive Tissue Handling:** Excessive manipulation of the fresh tissue before fixation can create artificial spaces.[3]
- **Processing Artifacts:** Shrinkage during dehydration and clearing can cause tissues to pull apart, creating spaces that are not present in vivo.[4]

Troubleshooting and Interpretation:

- **Prompt and Proper Fixation:** The most critical step is to fix the tissue immediately upon dissection.[1] Perfusion fixation, if feasible for your experimental design, can also minimize these artifacts.
- **Gentle Handling:** Handle the pancreas with care, avoiding excessive squeezing or stretching. [5]
- **Correlate with Other Pathological Signs:** True edema in **caerulein**-induced pancreatitis is typically accompanied by other histological changes such as inflammatory cell infiltration and

acinar cell vacuolization.[6][7] Control tissues should ideally lack these additional features.

- Examine the Nature of the Space: Pathological edema often contains eosinophilic proteinaceous fluid, whereas artifactual spaces are typically clear.

Frequently Asked Questions (FAQs)

Q1: What are the most common histological artifacts to look out for in **caerulein**-induced pancreatitis models?

A1: The most frequently encountered artifacts include:

- Fixation Artifacts: Such as autolysis from delayed fixation, which can obscure cellular detail, and shrinkage artifacts.[1][4]
- Processing Artifacts: Including tissue brittleness from over-dehydration and wrinkling from inadequate paraffin infiltration.[2]
- Sectioning Artifacts: Chatter (vibrations causing thick and thin lines), knife marks (scratches on the section), and compression can all distort tissue architecture.[2][8]
- Staining Artifacts: Precipitates from unfiltered stains or uneven staining due to incomplete deparaffinization.[2]

Q2: How can I minimize autolysis in my pancreatic tissue samples?

A2: The pancreas is particularly prone to autolysis due to its high concentration of digestive enzymes. To minimize this:

- Rapid Dissection and Fixation: Dissect the pancreas as quickly as possible after euthanasia and immediately immerse it in a large volume of cold fixative.[1]
- Adequate Fixative Penetration: Ensure the tissue pieces are small enough (ideally no more than 5mm thick) to allow for rapid and thorough penetration of the fixative.
- Use of Appropriate Fixative: 10% neutral buffered formalin is a standard and effective fixative for pancreatic tissue.[6][7]

Q3: Can artifacts be quantified, and how do they impact scoring of pancreatitis severity?

A3: While artifacts themselves are not typically scored, their presence can significantly impact the accurate scoring of pancreatitis severity. For instance, artificial spaces can be mistaken for edema, and poor fixation can mimic acinar cell necrosis. It is crucial to recognize and mentally discount these artifacts when applying a scoring system. If artifacts are severe and widespread, the sample may be unsuitable for quantitative analysis.

Quantitative Data Summary

The severity of **caerulein**-induced pancreatitis is often assessed by scoring various histological parameters. The following tables provide examples of scoring systems that can be adapted for your research.

Table 1: Histological Scoring of Pancreatitis Severity

Parameter	Score 0	Score 1	Score 2	Score 3	Score 4	Score 5
Edema	Absent	Interlobular	Intralobular	Isolated acinar islands	-	-
Inflammation	None	1-2 inflammatory cells in adipose tissue	3-4 inflammatory cells in adipose tissue	5-6 inflammatory cells, multifocal moderate (26-50% of lobules)	7-8 inflammatory cells, diffuse marked (51-75% of lobules)	>10 inflammatory cells, diffuse severe (>75% of lobules)
Acinar Cell Degeneration/Necrosis	None	1-4 cells/field	5-9 cells/field	10-12 cells/field	13-15 cells/field	>20 cells/field

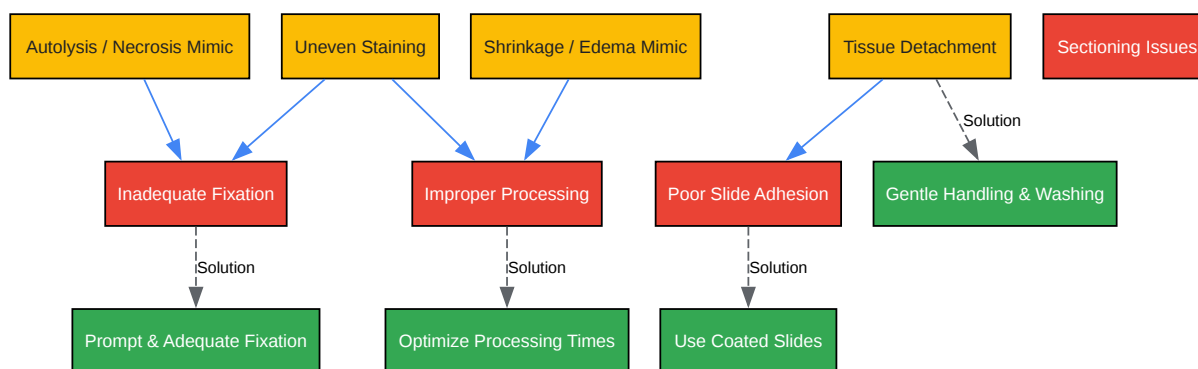
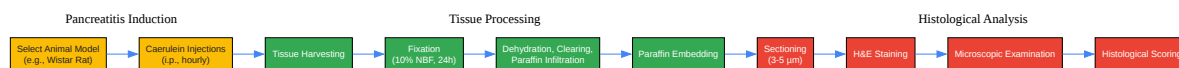Source: Adapted from various histological scoring protocols for **caerulein**-induced pancreatitis. [\[9\]](#)[\[10\]](#)[\[11\]](#)

Experimental Protocols

Protocol: **Caerulein**-Induced Pancreatitis and Tissue Preparation

- Animal Model: Male Wistar or C57BL/6 mice are commonly used.[\[6\]](#)[\[12\]](#)
- Induction of Pancreatitis: Administer intraperitoneal injections of **caerulein** (e.g., 50 µg/kg) hourly for a total of 6-10 doses.[\[6\]](#)[\[7\]](#) Control animals receive saline injections.
- Tissue Harvesting: At a predetermined time point after the final injection (e.g., 9 hours, 24 hours), euthanize the animals.[\[6\]](#)
- Fixation: Immediately dissect the pancreas, remove extraneous tissue, and fix in 10% neutral buffered formalin for 24 hours.[\[7\]](#)
- Tissue Processing:
 - Dehydrate the fixed tissue through a graded series of ethanol (e.g., 70%, 80%, 95%, 100%).
 - Clear the tissue with an agent like xylene.
 - Infiltrate and embed the tissue in paraffin wax.
- Sectioning: Cut 3-5 µm thick sections using a rotary microtome.[\[6\]](#)
- Staining: Mount the sections on slides and stain with Hematoxylin and Eosin (H&E).

Visualizations



[Click to download full resolution via product page](#)

Need Custom Synthesis?

BenchChem offers custom synthesis for rare earth carbides and specific isotopic labeling.

Email: info@benchchem.com or [Request Quote Online](#).

References

- 1. Avoid Common Mistakes In Pancreas Histology: Pitfalls To Know - COVID Care Hub [covidstatus.dps.illinois.edu]
- 2. Artifact in Histological Section – Biomedical and Pharmacology Journal [biomedpharmajournal.org]
- 3. scispace.com [scispace.com]
- 4. researchgate.net [researchgate.net]
- 5. Common Artifacts and Remedies in Histological Preparations [scirp.org]

- 6. Caerulein-induced pancreatitis in rats: Histological and genetic expression changes from acute phase to recuperation - PMC [pmc.ncbi.nlm.nih.gov]
- 7. A mouse model of severe acute pancreatitis induced with caerulein and lipopolysaccharide - PMC [pmc.ncbi.nlm.nih.gov]
- 8. A review of artifacts in histopathology - PMC [pmc.ncbi.nlm.nih.gov]
- 9. inotiv.com [inotiv.com]
- 10. researchgate.net [researchgate.net]
- 11. Histopathology and pathogenesis of caerulein-, duct ligation-, and arginine-induced acute pancreatitis in Sprague-Dawley rats and C57BL6 mice - PubMed [pubmed.ncbi.nlm.nih.gov]
- 12. Analysis of Pain and Analgesia Protocols in Acute Cerulein-Induced Pancreatitis in Male C57BL/6 Mice - PubMed [pubmed.ncbi.nlm.nih.gov]
- To cite this document: BenchChem. [Technical Support Center: Histological Artifacts in Caerulein-Induced Pancreatitis]. BenchChem, [2025]. [Online PDF]. Available at: [https://www.benchchem.com/product/b1668201#histological-artifacts-in-caerulein-induced-pancreatitis-tissue-samples]

Disclaimer & Data Validity:

The information provided in this document is for Research Use Only (RUO) and is strictly not intended for diagnostic or therapeutic procedures. While BenchChem strives to provide accurate protocols, we make no warranties, express or implied, regarding the fitness of this product for every specific experimental setup.

Technical Support: The protocols provided are for reference purposes. Unsure if this reagent suits your experiment? [[Contact our Ph.D. Support Team for a compatibility check](#)]

Need Industrial/Bulk Grade? [Request Custom Synthesis Quote](#)

BenchChem

Our mission is to be the trusted global source of essential and advanced chemicals, empowering scientists and researchers to drive progress in science and industry.

Contact

Address: 3281 E Guasti Rd

Ontario, CA 91761, United States

Phone: (601) 213-4426

Email: info@benchchem.com