

Technical Support Center: Hepatobiliary Phase Imaging

Author: BenchChem Technical Support Team. **Date:** December 2025

Compound of Interest

Compound Name: *Gadoxetic acid*

Cat. No.: *B1262754*

[Get Quote](#)

This guide provides troubleshooting assistance and frequently asked questions for researchers, scientists, and drug development professionals encountering poor hepatobiliary phase (HBP) enhancement in magnetic resonance imaging (MRI) experiments using liver-specific contrast agents like gadoxetate disodium (Gd-EOB-DTPA).

Frequently Asked Questions (FAQs) & Troubleshooting

Q1: What is the primary cause of poor or suboptimal hepatobiliary phase enhancement?

Poor enhancement during the hepatobiliary phase is primarily linked to impaired liver function.
[1][2][3][4][5] The contrast agent, gadoxetate disodium, is taken up by functioning hepatocytes via organic anion transporting polypeptides (OATP1B3) and subsequently excreted into the bile.[6][7] When hepatocellular function is compromised, as in cirrhosis or in patients with high bilirubin levels, this uptake and excretion process is inefficient, leading to reduced signal intensity in the liver parenchyma.[1][5][8][9]

Q2: How do specific liver function parameters correlate with HBP enhancement?

Several liver function markers and scoring systems show a significant correlation with the degree of liver enhancement. Elevated direct bilirubin is strongly associated with reduced enhancement.[1][9][10][11] There is a negative correlation between liver enhancement and scores like the Model for End-stage Liver Disease (MELD) and Albumin-Bilirubin (ALBI) grade.

[1][2] Conversely, higher albumin and lower aspartate aminotransferase (AST) levels are correlated with better enhancement.[2] In patients with chronic liver disease, enhancement is significantly lower than in controls, but it may appear normal if direct bilirubin levels are not elevated.[1][9]

Q3: My subject has known liver disease. How should I adjust the imaging protocol?

For patients with known chronic liver disease or cirrhosis, extending the delay time for HBP acquisition is often necessary.[12][13] While in patients with normal liver function a 10-20 minute delay is standard, in cirrhotic patients, peak parenchymal enhancement may not be achieved for 40 minutes or more.[4][12][13] Some studies suggest a "super delayed phase" of 60-120 minutes can improve liver contrast in patients with impaired function.[5] Additionally, using a higher flip angle (e.g., 30°-40°) for T1-weighted sequences can improve the contrast between the liver parenchyma and lesions.[6][12][14]

Q4: What constitutes an "adequate" hepatobiliary phase image?

An adequate hepatobiliary phase is generally defined as the point where the signal intensity of the liver parenchyma is unequivocally higher than that of the intrahepatic blood vessels, such as the portal vein.[7][8][12] The initial visualization of the intrahepatic bile duct is also considered a marker for an adequate HBP.[13] Suboptimal images are characterized by the liver parenchyma not being clearly brighter than the blood vessels.[8][10]

Q5: Can technical MRI parameters, aside from timing, affect HBP enhancement?

Yes, technical parameters play a crucial role. The choice of flip angle is significant; a larger flip angle (30°-40°) can increase T1 weighting and improve liver-to-lesion conspicuity during the HBP.[6][12][14] The contrast agent injection protocol, including the dose and rate, can also impact the earlier dynamic phases, which can indirectly affect the overall study quality.[7][15] [16] The standard approved dose for gadoxetate disodium is 0.025 mmol/kg.[6][15]

Q6: Are there any imaging artifacts that can mimic or contribute to poor enhancement?

Artifacts can certainly degrade image quality. Transient severe motion (TSM) is a known issue during the arterial phase with gadoxetate disodium, which can compromise the entire dynamic study.[17] While this doesn't directly reduce HBP signal, poor quality dynamic phases can complicate interpretation. Other issues like severe steatosis (fatty liver) or iron overload can

also lead to suboptimal HBP images where the parenchyma is not distinctly brighter than the vasculature.[8]

Quantitative Data Summary

The following tables summarize key quantitative data for easy reference and comparison.

Table 1: Correlation of Liver Enhancement with Liver Function Parameters

Parameter	Correlation with Liver Enhancement	Notes	Source
Liver-to-Spleen Ratio (LSR)	Significant negative correlation with ALBI and MELD-Na scores.	Patients with ALBI grade 1 have significantly higher LSR.	[2]
Hepatic Enhancement Coefficient (HEK)	Significant negative correlation with the number of abnormal Liver Function Tests (LFTs) and MELD scores.	HEK is significantly lower in patients with chronic liver disease.	[1][9]
Direct Bilirubin	Strong negative correlation.	Enhancement is significantly reduced with elevated direct bilirubin. Considered a key predictor of suboptimal HBP.	[1][9][10][11]
Albumin	Significant positive correlation.	Higher albumin levels are associated with better liver enhancement.	[2]
AST (Aspartate Aminotransferase)	Significant negative correlation.	Higher AST is linked to poorer enhancement.	[2]
Platelet Count	Significant positive correlation.	Lower platelet counts (often seen in cirrhosis) correlate with lower enhancement.	[2]

Table 2: Recommended MRI Protocol Parameters for Optimal Hepatobiliary Phase

Parameter	Recommendation for Normal Liver Function	Recommendation for Impaired Liver Function (e.g., Cirrhosis)	Source
Contrast Agent Dose (Gadoxetate Disodium)	0.025 mmol/kg (0.1 mL/kg)	0.025 mmol/kg (0.1 mL/kg)	[6] [15] [16]
Injection Rate	1.0 - 1.5 mL/s followed by saline flush	1.0 - 1.5 mL/s followed by saline flush	[4] [7] [16]
HBP Acquisition Delay Time	10 - 20 minutes post-injection	20 - 40 minutes or longer; consider super delayed phase (60-120 min)	[4] [5] [12] [13]
T1-weighted Sequence Flip Angle	30° - 40° recommended to improve conspicuity	30° - 40° recommended to improve conspicuity	[6] [12] [14]
Acquisition Type	3D T1-weighted gradient-echo (e.g., VIBE) with fat saturation	3D T1-weighted gradient-echo with fat saturation	[7] [18]

Key Experimental Protocols

Protocol: Quantitative Assessment of Liver Enhancement

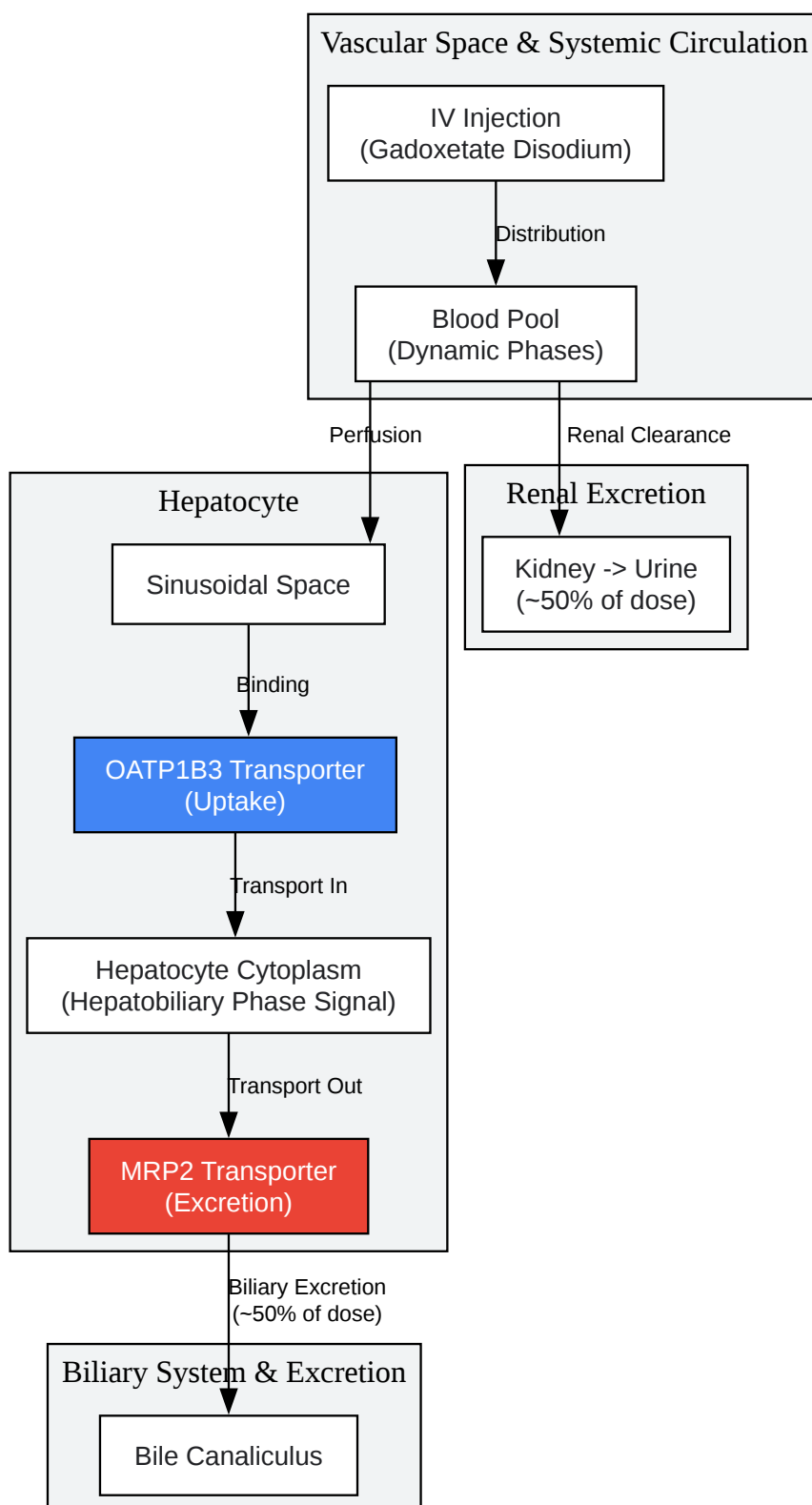
This protocol outlines a method to quantify liver enhancement and correlate it with biochemical markers, adapted from methodologies described in clinical research.[\[1\]](#)[\[2\]](#)[\[11\]](#)

- Subject Preparation:
 - Subjects should fast for at least 6 hours prior to the MRI scan to standardize gallbladder filling and reduce gastrointestinal motility.[\[16\]](#)

- Obtain recent liver function tests (bilirubin, albumin, AST, ALT, platelet count) and calculate MELD/ALBI scores if applicable.
- MRI Acquisition:
 - Use a 1.5T or 3.0T MRI scanner.
 - Pre-contrast sequences: Acquire axial T1-weighted in-phase and out-of-phase images and T2-weighted images.[\[18\]](#)
 - Contrast Administration: Inject 0.025 mmol/kg of gadoxetate disodium at a rate of 1-1.5 mL/s, followed by a 20 mL saline flush.[\[16\]](#)
 - Dynamic Phases: Acquire T1-weighted fat-saturated images during the late arterial (approx. 35s), portal venous (approx. 70s), and transitional phases (approx. 3-5 min).[\[14\]](#)
[\[18\]](#)
 - Hepatobiliary Phase: Acquire the primary HBP T1-weighted fat-saturated sequence at 20 minutes post-injection. If liver function is known to be poor, schedule additional acquisitions at 40, 60, or even 120 minutes.[\[4\]](#)[\[5\]](#)[\[13\]](#)
- Image Analysis and Quantification:
 - On the HBP images, place Regions of Interest (ROIs) in three different segments of the liver parenchyma, avoiding major vessels and lesions.
 - Place a similar-sized ROI in the spleen and another in the portal vein.
 - Calculate the mean signal intensity (SI) for each ROI.
 - Calculate Liver-to-Spleen Ratio (LSR): $LSR = \text{Mean SI}_{\text{liver}} / \text{Mean SI}_{\text{spleen}}$.[\[2\]](#)
 - Calculate Liver-Portal Vein Contrast Ratio: $\text{Ratio} = (\text{Mean SI}_{\text{liver}} - \text{Mean SI}_{\text{portal_vein}}) / \text{Mean SI}_{\text{portal_vein}}$.[\[11\]](#)
 - An adequate HBP is often associated with an LSR > 1.5 or a visibly hyperintense liver compared to the portal vein.[\[11\]](#)

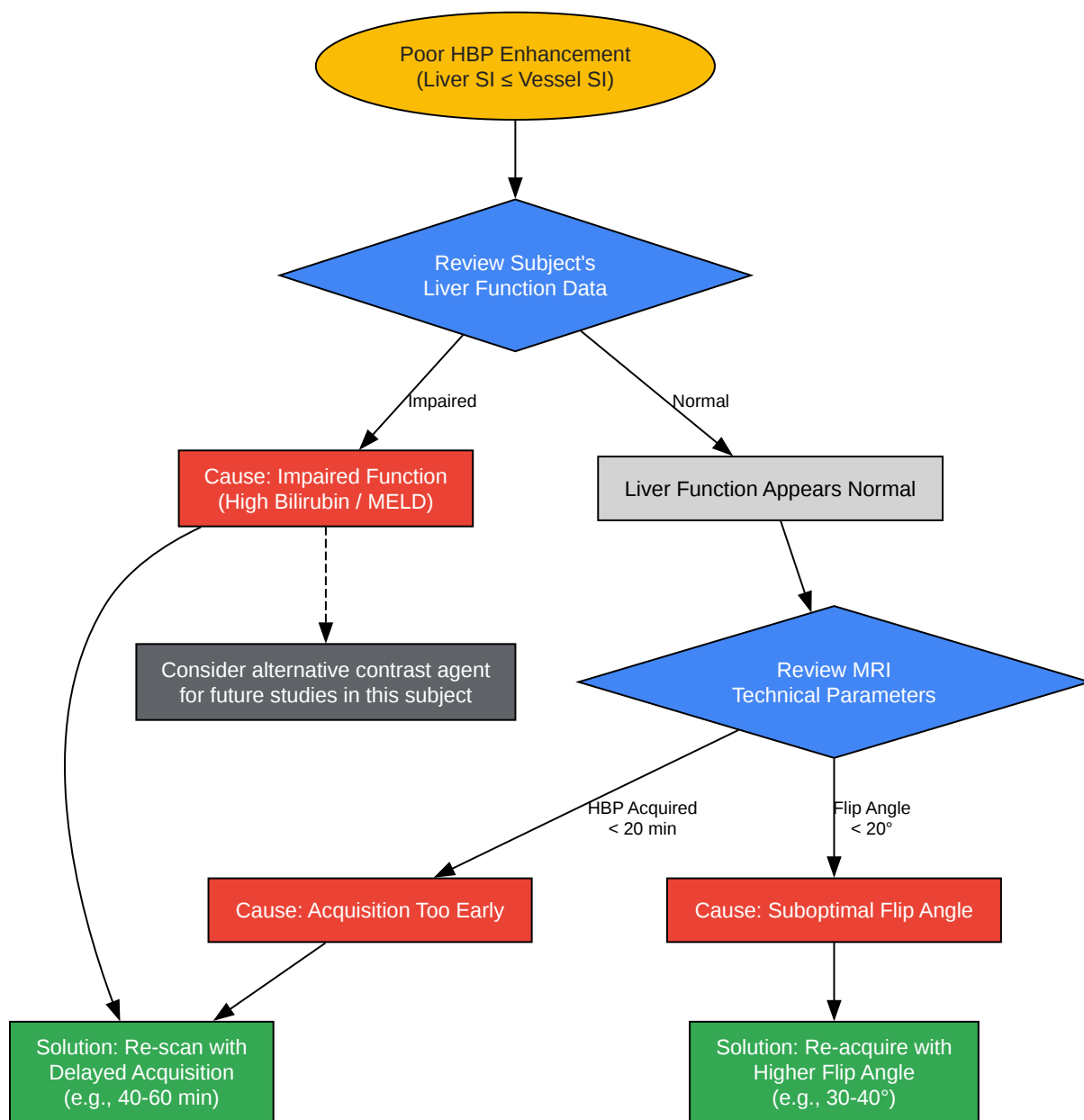
- Data Correlation:
 - Use statistical software to perform correlation analysis (e.g., Spearman's rank correlation) between the calculated enhancement ratios (LSR, etc.) and the subject's biochemical data (bilirubin, MELD score, etc.).

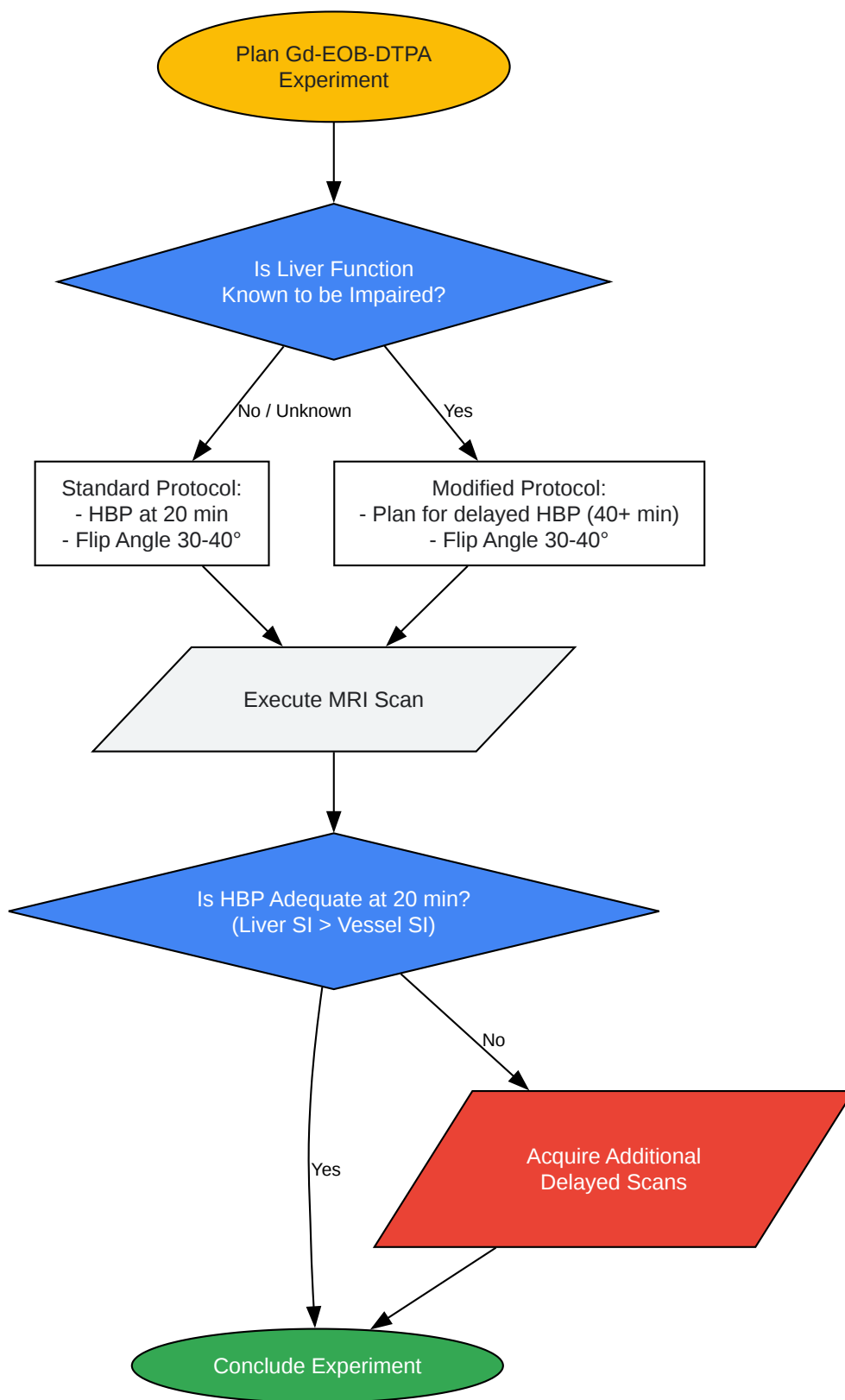
Visualizations



[Click to download full resolution via product page](#)

Caption: Pharmacokinetic pathway of gadoxetate disodium uptake and excretion.





[Click to download full resolution via product page](#)

Need Custom Synthesis?

BenchChem offers custom synthesis for rare earth carbides and specific isotopic labeling.

Email: info@benchchem.com or [Request Quote Online](#).

References

- 1. Hepatic enhancement during the hepatobiliary phase after gadoxetate disodium administration in patients with chronic liver disease: the role of laboratory factors - PubMed [pubmed.ncbi.nlm.nih.gov]
- 2. d-nb.info [d-nb.info]
- 3. Gadoxetate Acid-Enhanced MR Imaging for HCC: A Review for Clinicians - PMC [pmc.ncbi.nlm.nih.gov]
- 4. mriquestions.com [mriquestions.com]
- 5. Super delayed phase imaging in gadoxetic acid-enhanced MRI: investigating factors contributing to improved liver contrast - PMC [pmc.ncbi.nlm.nih.gov]
- 6. geiselmed.dartmouth.edu [geiselmed.dartmouth.edu]
- 7. Patterns of enhancement in the hepatobiliary phase of gadoxetic acid-enhanced MRI - PMC [pmc.ncbi.nlm.nih.gov]
- 8. researchgate.net [researchgate.net]
- 9. researchgate.net [researchgate.net]
- 10. Suboptimal hepatobiliary phase image in gadoxetic acid-enhanced liver MRI for the evaluation of the HCC: Predictive factors - PMC [pmc.ncbi.nlm.nih.gov]
- 11. Suboptimal hepatobiliary phase image in gadoxetic acid-enhanced liver MRI for the evaluation of the HCC: Predictive factors - PubMed [pubmed.ncbi.nlm.nih.gov]
- 12. Optimization of hepatobiliary phase imaging in gadoxetic acid-enhanced magnetic resonance imaging: a narrative review - PMC [pmc.ncbi.nlm.nih.gov]
- 13. Optimization of hepatobiliary phase imaging in gadoxetic acid-enhanced magnetic resonance imaging: a narrative review - Wang - Quantitative Imaging in Medicine and Surgery [qims.amegroups.org]
- 14. preprints.org [preprints.org]
- 15. ajronline.org [ajronline.org]

- 16. Hepatobiliary phases in magnetic resonance imaging using liver-specific contrast for focal lesions in clinical practice - PMC [pmc.ncbi.nlm.nih.gov]
- 17. Troubleshooting Arterial-Phase MR Images of Gadoxetate Disodium-Enhanced Liver - PMC [pmc.ncbi.nlm.nih.gov]
- 18. radiopaedia.org [radiopaedia.org]
- To cite this document: BenchChem. [Technical Support Center: Hepatobiliary Phase Imaging]. BenchChem, [2025]. [Online PDF]. Available at: [https://www.benchchem.com/product/b1262754#troubleshooting-poor-hepatobiliary-phase-enhancement]

Disclaimer & Data Validity:

The information provided in this document is for Research Use Only (RUO) and is strictly not intended for diagnostic or therapeutic procedures. While BenchChem strives to provide accurate protocols, we make no warranties, express or implied, regarding the fitness of this product for every specific experimental setup.

Technical Support: The protocols provided are for reference purposes. Unsure if this reagent suits your experiment? [[Contact our Ph.D. Support Team for a compatibility check](#)]

Need Industrial/Bulk Grade? [Request Custom Synthesis Quote](#)

BenchChem

Our mission is to be the trusted global source of essential and advanced chemicals, empowering scientists and researchers to drive progress in science and industry.

Contact

Address: 3281 E Guasti Rd
Ontario, CA 91761, United States
Phone: (601) 213-4426
Email: info@benchchem.com