

Technical Support Center: Gd-EOB-DTPA & Hyperbilirubinemia

Author: BenchChem Technical Support Team. **Date:** December 2025

Compound of Interest

Compound Name: *Eob-dtpa*

Cat. No.: *B3021170*

[Get Quote](#)

Welcome to the technical support center for researchers, scientists, and drug development professionals. This resource provides guidance on the impact of hyperbilirubinemia on Gadolinium ethoxybenzyl diethylenetriamine pentaacetic acid (Gd-**EOB-DTPA**) enhanced magnetic resonance imaging (MRI). Here you will find frequently asked questions and troubleshooting guides to address common issues encountered during experiments.

Frequently Asked Questions (FAQs)

Q1: What is the mechanism of Gd-**EOB-DTPA** uptake and excretion in the liver?

A1: Gd-**EOB-DTPA** is a hepatocyte-specific MRI contrast agent. After intravenous injection, it is taken up by hepatocytes from the sinusoidal blood. This uptake is primarily mediated by organic anion transporting polypeptides (OATPs), specifically OATP1B1 and OATP1B3, on the sinusoidal membrane of the hepatocytes.[1] Following uptake, approximately 50% of the injected dose is excreted unchanged into the bile via the multidrug resistance-associated protein 2 (MRP2) located on the canalicular membrane of the hepatocytes.[2] The remaining 50% is excreted renally.[3][4]

Q2: How does hyperbilirubinemia affect Gd-**EOB-DTPA** liver enhancement?

A2: Hyperbilirubinemia, an excess of bilirubin in the blood, can significantly reduce liver enhancement during the hepatobiliary phase (HBP) of a Gd-**EOB-DTPA** enhanced MRI.[5] This is because bilirubin and Gd-**EOB-DTPA** compete for the same OATP transporters for uptake into hepatocytes.[1][2][5] Elevated bilirubin levels can saturate these transporters, leading to

decreased uptake of the contrast agent by the liver cells and consequently, reduced signal intensity enhancement.[2]

Q3: Is the renal excretion of Gd-**EOB-DTPA** affected by hyperbilirubinemia?

A3: Yes, in cases of hepatic impairment leading to hyperbilirubinemia, the body compensates by increasing the renal excretion of Gd-**EOB-DTPA**. In patients with very high bilirubin levels (>3 mg/dL), renal excretion can increase to between 72% and 96% of the administered dose, compared to approximately 50% in individuals with normal liver function.[4]

Q4: Can Gd-**EOB-DTPA** enhanced MRI still be useful in patients with hyperbilirubinemia?

A4: Despite reduced enhancement, Gd-**EOB-DTPA** enhanced MRI can still provide valuable diagnostic information in patients with hyperbilirubinemia. The degree of reduced uptake and delayed excretion can serve as an indicator of the severity of liver dysfunction.[3][6] However, the interpretation of images may be more challenging, and quantitative analysis is often necessary to assess liver function accurately.[7]

Q5: What is the typical timeframe for the hepatobiliary phase in patients with normal versus impaired liver function?

A5: In patients with normal liver function, the hepatobiliary phase typically occurs around 20 minutes after Gd-**EOB-DTPA** injection.[1][8] In patients with impaired liver function, including those with hyperbilirubinemia, the uptake of the contrast agent is slower, and the time to peak parenchymal enhancement may be delayed.[3]

Troubleshooting Guides

Problem 1: Suboptimal or no liver enhancement in the hepatobiliary phase in a subject with known hyperbilirubinemia.

- Possible Cause: Competitive inhibition of OATP transporters by high levels of bilirubin, leading to reduced uptake of Gd-**EOB-DTPA** by hepatocytes.[2][5]
- Troubleshooting Steps:

- **Verify Bilirubin Levels:** Correlate the imaging findings with the subject's serum total bilirubin levels. A negative correlation between bilirubin levels and liver enhancement is expected.[9]
- **Quantitative Analysis:** Instead of relying solely on visual assessment, perform quantitative analysis of the signal intensity. Calculate the relative enhancement (RE) of the liver parenchyma.[6] Lower RE values are anticipated with higher bilirubin levels.
- **Delayed Imaging:** Consider acquiring images at later time points (e.g., 40, 60, or even 120 minutes post-injection) to assess for delayed uptake and excretion, which can be indicative of impaired liver function.[8]
- **Alternative Imaging:** If characterization of a liver lesion is the primary goal and hepatocyte function is severely compromised, consider using a conventional extracellular gadolinium-based contrast agent that does not rely on hepatocyte uptake.

Problem 2: Difficulty in differentiating between a true lesion and an area of poor enhancement due to localized liver dysfunction.

- **Possible Cause:** Conditions like cholestasis or localized biliary obstruction can lead to regional differences in Gd-**EOB-DTPA** uptake, mimicking a hypointense lesion.[10]
- **Troubleshooting Steps:**
 - **Review Other Sequences:** Carefully analyze pre-contrast T1-weighted, T2-weighted, and diffusion-weighted images to look for underlying abnormalities in the area of reduced enhancement.
 - **Correlate with Clinical Data:** Check for clinical signs and laboratory markers of biliary obstruction or localized liver injury.
 - **Dynamic Phase Evaluation:** Assess the arterial and portal venous phase enhancement patterns. True lesions often have characteristic vascular patterns that differ from dysfunctional parenchyma.[11] For instance, hepatocellular carcinoma (HCC) typically shows arterial phase hyperenhancement and portal venous phase "washout".[11]

- Follow-up Imaging: If uncertainty remains, a follow-up scan after resolution of the underlying issue (if possible) may clarify the findings.

Quantitative Data Summary

The following tables summarize key quantitative findings from studies investigating the impact of liver function on Gd-**EOB-DTPA** enhancement.

Table 1: Relative Enhancement (RE) in Patients with Normal vs. Impaired Liver Function

Liver Function Status	Mean Relative Enhancement (RE) \pm SD	Optimal Cut-off for Differentiation	Sensitivity	Specificity	Area Under Curve (AUC)
Normal Liver Function (MELD score ≤ 10)	87.2% \pm 29.5%	47.7%	82.8%	92.7%	0.87
Impaired Liver Function (MELD score > 10)	45.4% \pm 26.5%				

Data adapted from a study evaluating Gd-**EOB-DTPA** uptake at 3T.[6]

Table 2: Correlation of Relative Enhancement at 20 minutes (RE_{20min}) with Liver Function Parameters

Parameter	Pearson Correlation Coefficient (r) with RE _{20min}	P-value
Serum Total Bilirubin	-0.491	<0.05
Prothrombin Time	-0.481	<0.05
Child-Pugh Score	-0.619	<0.05
Serum Albumin	0.352	<0.05

Data from a retrospective analysis of patients with hepatitis B cirrhosis.[9]

Experimental Protocols

Protocol 1: Animal Model of Biliary Obstruction

- Objective: To investigate the effect of biliary obstruction on Gd-**EOB-DTPA** enhancement.
- Animal Model: Male Wistar rats.
- Procedure:
 - Induction of Obstruction:
 - Selective Biliary Obstruction (SBO): Ligation of the bile ducts draining specific liver lobes.
 - Total Biliary Obstruction (TBO): Ligation of the common bile duct.
 - MRI Protocol:
 - Scanner: 1.5T MRI scanner.
 - Sequence: T1-weighted spin-echo sequence.
 - Contrast Agent: Gd-**EOB-DTPA** administered intravenously at a dose of 0.1 mmol/kg.

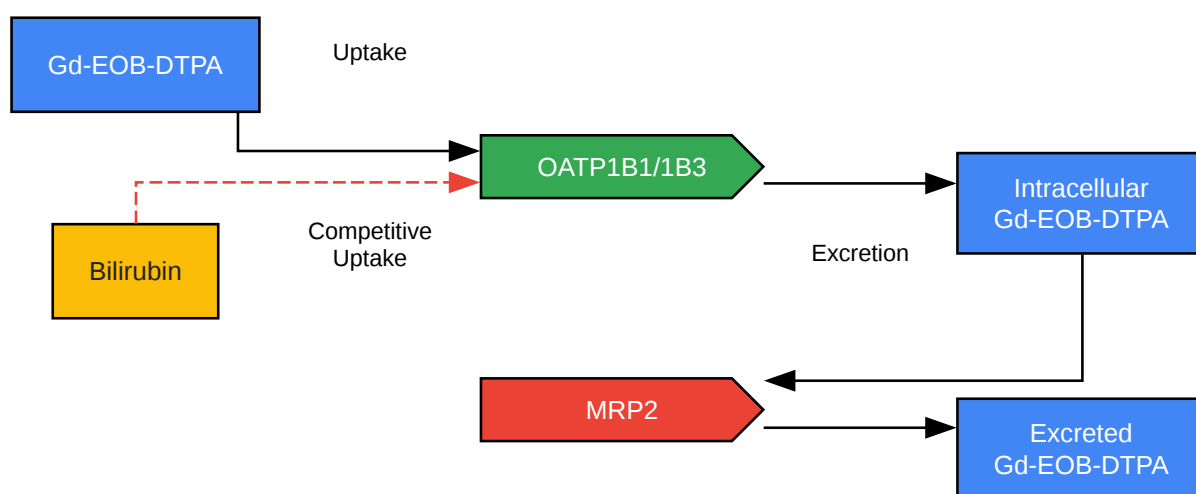
- Imaging Timepoints: Pre-contrast and serial post-contrast images acquired up to 60 minutes.
- Data Analysis:
 - Measure signal intensity (SI) of the liver parenchyma in obstructed and unobstructed lobes.
 - Calculate the liver-to-muscle SI ratio to normalize enhancement.
- Correlation: Correlate MRI findings with serum bilirubin levels, microcholangiography, and histopathology.[\[10\]](#)

Protocol 2: Quantitative Evaluation of Liver Function using Gd-**EOB-DTPA** MRI

- Objective: To quantitatively assess liver function using dynamic contrast-enhanced MRI with Gd-**EOB-DTPA**.
- Subjects: Patients with varying degrees of liver function.
- MRI Protocol:
 - Scanner: 3T MRI scanner.
 - Sequence: T1-weighted volume interpolated breath-hold examination (VIBE) with fat suppression.
 - Contrast Agent: Gd-**EOB-DTPA** administered intravenously as a bolus at a dose of 0.025 mmol/kg.
 - Imaging Timepoints: Pre-contrast and at 20 minutes post-injection (hepatobiliary phase).
- Data Analysis:
 - Region of Interest (ROI) Placement: Draw ROIs on the liver parenchyma, avoiding large vessels and artifacts.

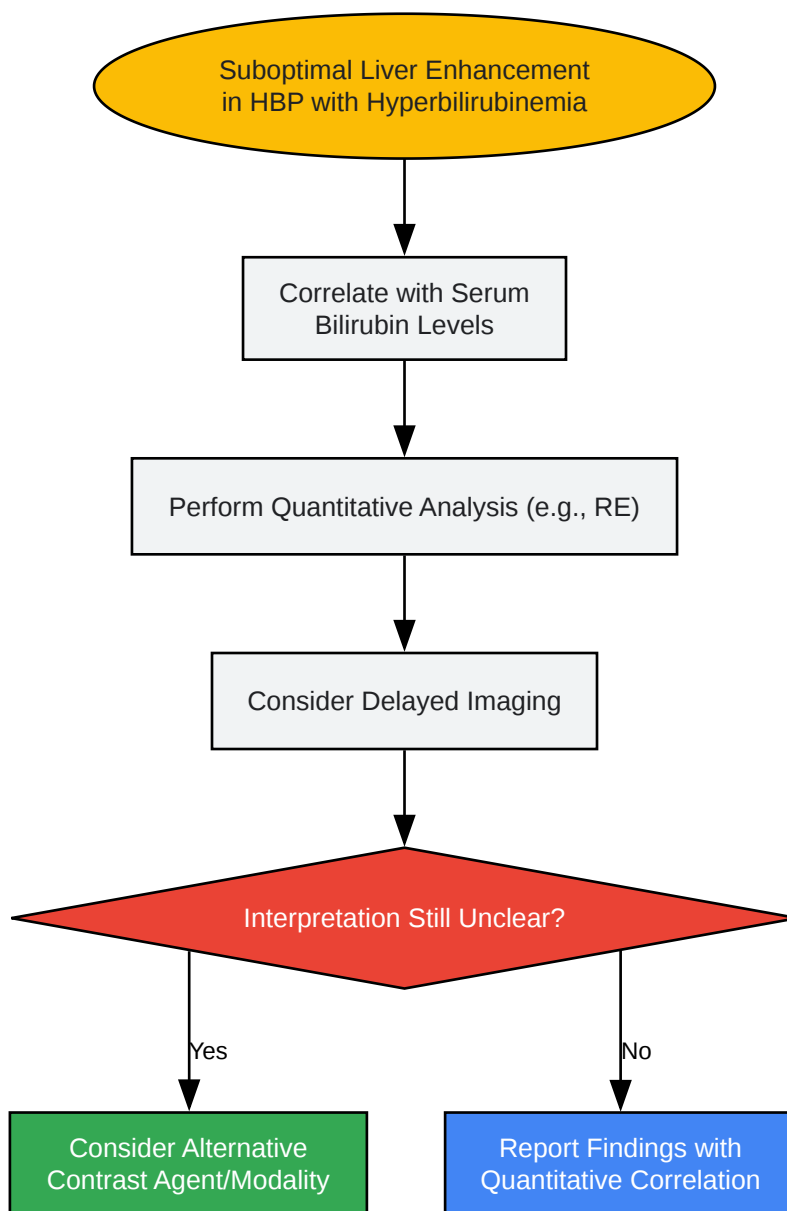
- Signal Intensity Measurement: Measure the mean signal intensity of the liver in the pre-contrast (SI_pre) and 20-minute post-contrast (SI_post) images.
- Calculation of Relative Enhancement (RE):
 - $RE (\%) = [(SI_{post} - SI_{pre}) / SI_{pre}] * 100$
- Correlation: Correlate the calculated RE with clinical scores of liver function such as the Model for End-Stage Liver Disease (MELD) score or Child-Pugh score.[6]

Visualizations



[Click to download full resolution via product page](#)

Caption: Gd-**EOB-DTPA** uptake and excretion pathway in hepatocytes.



[Click to download full resolution via product page](#)

Caption: Troubleshooting workflow for suboptimal Gd-**EOB-DTPA** enhancement.

Need Custom Synthesis?

BenchChem offers custom synthesis for rare earth carbides and specific isotopic labeling.

Email: info@benchchem.com or [Request Quote Online](#).

References

- 1. radiopaedia.org [radiopaedia.org]
- 2. Evaluation of liver function using Gd-EOB-DTPA-enhanced MRI with T1 mapping - PMC [pmc.ncbi.nlm.nih.gov]
- 3. Gd-EOB-DTPA-enhanced MRI for the assessment of liver function and volume in liver cirrhosis - PMC [pmc.ncbi.nlm.nih.gov]
- 4. Pharmacokinetics and imaging properties of Gd-EOB-DTPA in patients with hepatic and renal impairment - PubMed [pubmed.ncbi.nlm.nih.gov]
- 5. ovid.com [ovid.com]
- 6. Assessing liver function by liver enhancement during the hepatobiliary phase with Gd-EOB-DTPA-enhanced MRI at 3 Tesla - PubMed [pubmed.ncbi.nlm.nih.gov]
- 7. Quantitative Evaluation of Liver Function with Gd-EOB-DTPA-enhanced MR Imaging [jstage.jst.go.jp]
- 8. Hepatobiliary MR Imaging with Gadolinium Based Contrast Agents - PMC [pmc.ncbi.nlm.nih.gov]
- 9. xfcrb2020.com [xfcrb2020.com]
- 10. MR imaging evaluation of liver enhancement by Gd-EOB-DTPA in selective and total bile duct obstruction in rats: correlation with serologic, microcholangiographic, and histologic findings - PubMed [pubmed.ncbi.nlm.nih.gov]
- 11. Gd-EOB-DTPA enhanced MRI nomogram model to differentiate hepatocellular carcinoma and focal nodular hyperplasia both showing iso- or hyperintensity in the hepatobiliary phase - PMC [pmc.ncbi.nlm.nih.gov]
- To cite this document: BenchChem. [Technical Support Center: Gd-EOB-DTPA & Hyperbilirubinemia]. BenchChem, [2025]. [Online PDF]. Available at: [https://www.benchchem.com/product/b3021170#impact-of-hyperbilirubinemia-on-gd-eob-dtpa-enhancement]

Disclaimer & Data Validity:

The information provided in this document is for Research Use Only (RUO) and is strictly not intended for diagnostic or therapeutic procedures. While BenchChem strives to provide accurate protocols, we make no warranties, express or implied, regarding the fitness of this product for every specific experimental setup.

Technical Support: The protocols provided are for reference purposes. Unsure if this reagent suits your experiment? [[Contact our Ph.D. Support Team for a compatibility check](#)]

Need Industrial/Bulk Grade? [Request Custom Synthesis Quote](#)

BenchChem

Our mission is to be the trusted global source of essential and advanced chemicals, empowering scientists and researchers to drive progress in science and industry.

Contact

Address: 3281 E Guasti Rd
Ontario, CA 91761, United States
Phone: (601) 213-4426
Email: info@benchchem.com