

# Technical Support Center: Gd-EOB-DTPA (Eovist/Primovist)

**Author:** BenchChem Technical Support Team. **Date:** December 2025

## Compound of Interest

Compound Name: *Eob-dtpa*

Cat. No.: *B3021170*

[Get Quote](#)

This technical support center provides troubleshooting guidance and frequently asked questions (FAQs) for researchers, scientists, and drug development professionals utilizing Gadolinium ethoxybenzyl diethylenetriaminepentaacetic acid (Gd-**EOB-DTPA**) in preclinical and clinical research, with a specific focus on its limitations in subjects with severe cholestasis.

## Troubleshooting Guides

Issue: Reduced or absent hepatic parenchymal enhancement in the hepatobiliary phase (HBP).

- Question: We are observing significantly lower than expected signal intensity in the liver parenchyma during the 20-minute delayed hepatobiliary phase in our study subjects. What could be the cause?
- Answer: Reduced hepatic enhancement with Gd-**EOB-DTPA** is a known limitation in the presence of impaired liver function, particularly severe cholestasis or cirrhosis.[1][2] The primary reason is the competition between Gd-**EOB-DTPA** and bilirubin for uptake into hepatocytes via the organic anion transporting polypeptide (OATP) transporters.[3][4][5] In cholestatic conditions, elevated serum bilirubin levels saturate these transporters, leading to decreased uptake of the contrast agent by hepatocytes. Additionally, in severe cirrhosis (e.g., Child-Pugh grade C), the overall mass and function of hepatocytes are reduced, further diminishing the capacity for Gd-**EOB-DTPA** uptake.[1]

Issue: Delayed or non-visualization of the biliary tree.

- Question: In our experiments, there is a significant delay or complete absence of Gd-**EOB-DTPA** excretion into the biliary ducts, even in delayed imaging sequences. Why is this happening?
- Answer: The excretion of Gd-**EOB-DTPA** from hepatocytes into the bile canaliculi is an active process mediated by the multidrug resistance-associated protein 2 (MRP2).[6][7] In severe cholestasis, the function of MRP2 can be impaired or downregulated, leading to reduced or absent biliary excretion of the contrast agent.[8][9] This results in prolonged retention of Gd-**EOB-DTPA** within the hepatocytes and poor or no visualization of the biliary tree.[10] In patients with normal liver function, a 20-minute delay is typically sufficient for biliary evaluation; however, in those with impaired function, delays of 60-180 minutes may be necessary.[11]

Issue: Suboptimal image quality in the hepatobiliary phase for lesion detection.

- Question: The contrast between the liver parenchyma and suspected lesions is poor in the hepatobiliary phase, making lesion detection and characterization difficult. How can we predict or mitigate this?
- Answer: Suboptimal image quality in the hepatobiliary phase is strongly correlated with serum total bilirubin levels.[4] Elevated bilirubin directly competes with Gd-**EOB-DTPA** for hepatocyte uptake, reducing the background liver enhancement necessary for lesion conspicuity.[3][4] For patients with chronic liver disease, the hepatobiliary specific scanning time can be extended to account for delayed and weaker enhancement.[1]

## Frequently Asked Questions (FAQs)

- What is the mechanism of Gd-**EOB-DTPA** uptake and excretion? Gd-**EOB-DTPA** is a hepatocyte-specific MRI contrast agent.[6] Following intravenous injection, it distributes in the extracellular space, allowing for dynamic phase imaging.[12] Subsequently, approximately 50% of the injected dose is actively transported into hepatocytes via organic anion transporting polypeptides (OATPs).[3][6] It is then excreted unchanged into the bile via the multidrug resistance-associated protein 2 (MRP2).[6] The remaining 50% is eliminated by the kidneys through glomerular filtration.[3][5]

- At what level of hyperbilirubinemia do limitations become significant? Studies have shown that serum total bilirubin levels can predict suboptimal image quality in the hepatobiliary phase.[4] One study identified an optimal cutoff value of total bilirubin at 2.1 mg/dL for predicting poor image quality.[4] Another source suggests that elevated total bilirubin above 3.5 mg/dL is a contraindication for the use of Eovist for certain indications.[13]
- Are there alternative imaging agents for patients with severe cholestasis? For patients with severe cholestasis where Gd-**EOB-DTPA** may be ineffective, alternative contrast agents can be considered. Extracellular contrast agents (ECAs) can provide information on the vascularity of liver lesions during dynamic phase imaging, which is still valuable for characterization.[14] Another hepatobiliary agent, gadobenate dimeglumine (Gd-BOPTA), is also available. However, only about 3-5% of the administered dose of Gd-BOPTA is excreted into the bile, compared to 50% for Gd-**EOB-DTPA**, making it less ideal for biliary imaging but still useful for characterizing liver lesions.[11][15]
- How does severe cirrhosis affect Gd-**EOB-DTPA** enhancement? In patients with severe cirrhosis, particularly Child-Pugh grade C, the degree of liver parenchyma enhancement and the timing of biliary system excretion are correlated with the severity of liver function damage.[1] The reduced number and function of hepatocytes lead to weak and uneven enhancement in the hepatobiliary phase, which can negatively impact the detection of liver lesions.[1][2]

## Quantitative Data Summary

Parameter	Value	Significance	Reference
Total Bilirubin Cutoff for Suboptimal HBP Image Quality	2.1 mg/dL	This value can be used to predict which patients are likely to have poor image quality in the hepatobiliary phase.	[4]
Total Bilirubin Contraindication	> 3.5 mg/dL	For certain indications, a total bilirubin level above this value is considered a contraindication for Eovist-enhanced MRI.	[13]
Biliary Excretion of Gd-EOB-DTPA	~50%	This high percentage of biliary excretion is what makes it a valuable agent for functional biliary imaging.	[5][12]
Biliary Excretion of Gd-BOPTA	~3-5%	The lower biliary excretion of this alternative agent makes it less suitable for detailed biliary imaging compared to Gd-EOB-DTPA.	[11]
Standard Dose of Gd-EOB-DTPA	0.025 mmol/kg	This is a quarter of the standard dose for some other gadolinium-based contrast agents.	[1]

## Experimental Protocols

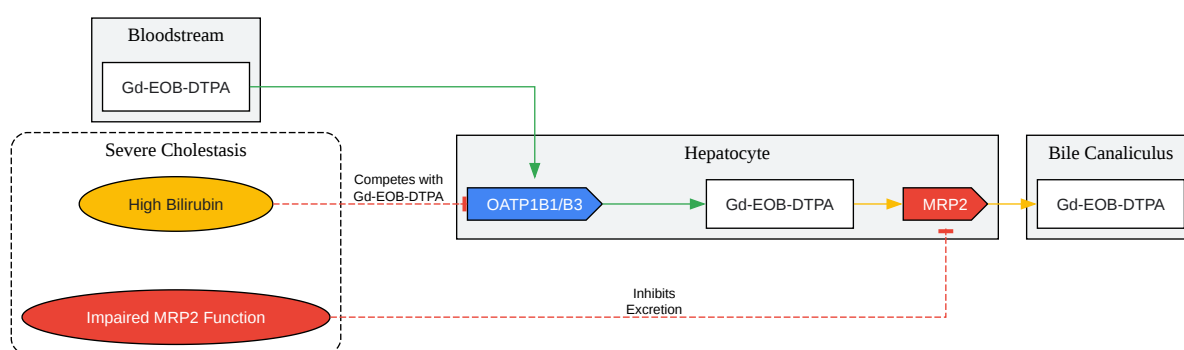
### Protocol for Assessing Gd-**EOB-DTPA** Enhancement in a Rat Model of Biliary Obstruction

This protocol is a summary of the methodology described in studies investigating the effects of cholestasis on Gd-**EOB-DTPA** enhancement.

- Animal Model:
  - Induce selective biliary obstruction (SBO) or total biliary obstruction (TBO) in male Wistar rats by ligating the corresponding bile ducts.[\[10\]](#)
  - Use a control group of sham-operated rats.
- MRI Acquisition:
  - Perform MRI using a clinical or preclinical scanner (e.g., 1.5T).
  - Acquire baseline T1-weighted images before contrast administration.
  - Administer Gd-**EOB-DTPA** intravenously at a dose of 0.025 mmol/kg body weight.[\[1\]](#)
  - Acquire serial T1-weighted images at multiple time points post-injection (e.g., 5, 10, 20, 30, and 40 minutes) to capture the dynamic and hepatobiliary phases.[\[9\]](#)
- Data Analysis:
  - Measure the signal intensity (SI) in regions of interest (ROIs) placed over the liver parenchyma on the pre- and post-contrast images.
  - Calculate the relative enhancement (RE) using the formula:  $RE (\%) = [(SI_{post} - SI_{pre}) / SI_{pre}] * 100$ .
  - Compare the RE between the obstructed and unobstructed liver lobes (in SBO), and between the cholestatic and control groups.[\[9\]](#)[\[10\]](#)
- Correlative Analysis:

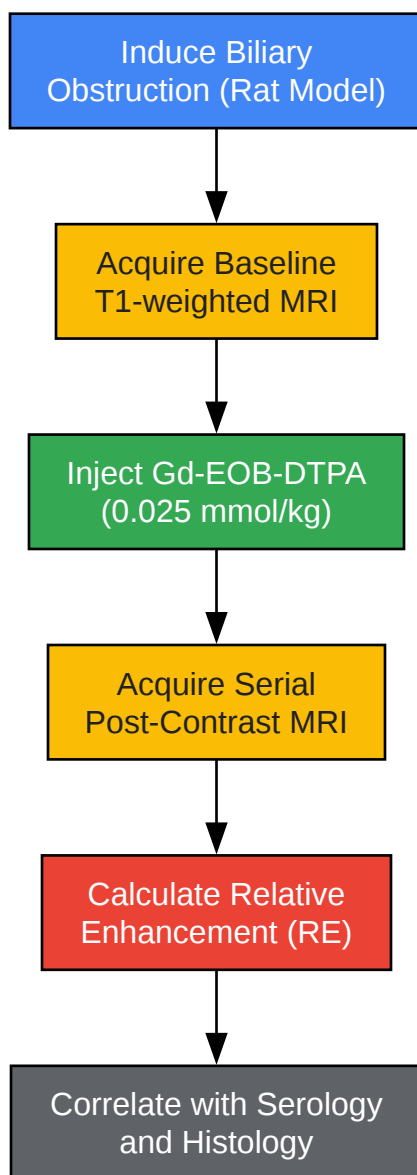
- Collect blood samples for serological analysis of liver function markers (e.g., total bilirubin, direct bilirubin, ALT, AST).[9]
- Perform histological analysis of liver tissue to assess for fibrosis and expression of transporters like OATP1 and MRP2 using immunohistochemistry.[9]

## Visualizations



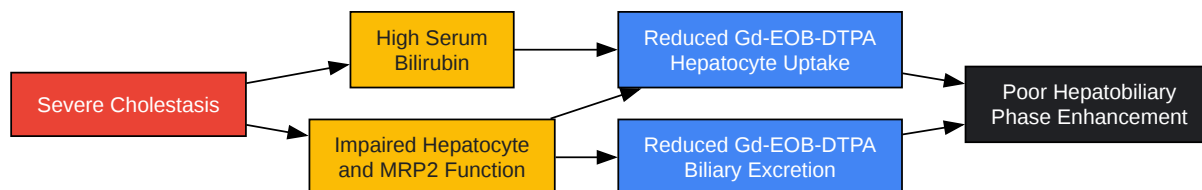
[Click to download full resolution via product page](#)

Caption: Gd-EOB-DTPA uptake and excretion pathway and its inhibition in severe cholestasis.



[Click to download full resolution via product page](#)

Caption: Experimental workflow for assessing Gd-**EOB-DTPA** limitations in cholestasis.



[Click to download full resolution via product page](#)

Caption: Logical relationship between severe cholestasis and imaging limitations of Gd-EOB-DTPA.

#### Need Custom Synthesis?

BenchChem offers custom synthesis for rare earth carbides and specific isotopic labeling.

Email: [info@benchchem.com](mailto:info@benchchem.com) or [Request Quote Online](#).

## References

- 1. Application of Gd-EOB-DTPA-enhanced magnetic resonance imaging (MRI) in hepatocellular carcinoma - PMC [pmc.ncbi.nlm.nih.gov]
- 2. Diagnostic Accuracy of Gd-EOB-DTPA for Detection Hepatocellular Carcinoma (HCC): A Comparative Study with Dynamic Contrast Enhanced Magnetic Resonance Imaging (MRI) and Dynamic Contrast Enhanced Computed Tomography (CT) - PMC [pmc.ncbi.nlm.nih.gov]
- 3. mriquestions.com [mriquestions.com]
- 4. Total Bilirubin Level as a Predictor of Suboptimal Image Quality of the Hepatobiliary Phase of Gadoteric Acid-Enhanced MRI in Patients with Extrahepatic Bile Duct Cancer - PMC [pmc.ncbi.nlm.nih.gov]
- 5. mriquestions.com [mriquestions.com]
- 6. Liver fibrosis and Gd-EOB-DTPA-enhanced MRI: A histopathologic correlation - PMC [pmc.ncbi.nlm.nih.gov]
- 7. The roles of MRP2, MRP3, OATP1B1, and OATP1B3 in conjugated hyperbilirubinemia - PubMed [pubmed.ncbi.nlm.nih.gov]
- 8. Multidrug Resistance-Associated Protein 2 Deficiency Aggravates Estrogen-Induced Impairment of Bile Acid Metabolomics in Rats - PMC [pmc.ncbi.nlm.nih.gov]
- 9. Dynamic contrast-enhanced MRI of the liver in Mrp2-deficient rats using the hepatobiliary contrast agent Gd-EOB-DTPA - PubMed [pubmed.ncbi.nlm.nih.gov]
- 10. MR imaging evaluation of liver enhancement by Gd-EOB-DTPA in selective and total bile duct obstruction in rats: correlation with serologic, microcholangiographic, and histologic findings - PubMed [pubmed.ncbi.nlm.nih.gov]



- 11. Diagnostic value of Gd-EOB-DTPA-enhanced MR cholangiography in non-invasive detection of postoperative bile leakage - PMC [pmc.ncbi.nlm.nih.gov]
- 12. radiologysolutions.bayer.com [radiologysolutions.bayer.com]
- 13. radres.ucsd.edu [radres.ucsd.edu]
- 14. MRI of the liver: choosing the right contrast agent - PubMed [pubmed.ncbi.nlm.nih.gov]
- 15. geiselmed.dartmouth.edu [geiselmed.dartmouth.edu]
- To cite this document: BenchChem. [Technical Support Center: Gd-EOB-DTPA (Eovist/Primovist)]. BenchChem, [2025]. [Online PDF]. Available at: [https://www.benchchem.com/product/b3021170#limitations-of-eob-dtpa-in-severe-cholestasis]

---

### Disclaimer & Data Validity:

The information provided in this document is for Research Use Only (RUO) and is strictly not intended for diagnostic or therapeutic procedures. While BenchChem strives to provide accurate protocols, we make no warranties, express or implied, regarding the fitness of this product for every specific experimental setup.

**Technical Support:** The protocols provided are for reference purposes. Unsure if this reagent suits your experiment? [[Contact our Ph.D. Support Team for a compatibility check](#)]

**Need Industrial/Bulk Grade?** [Request Custom Synthesis Quote](#)

## BenchChem

Our mission is to be the trusted global source of essential and advanced chemicals, empowering scientists and researchers to drive progress in science and industry.

### Contact

Address: 3281 E Guasti Rd  
Ontario, CA 91761, United States  
Phone: (601) 213-4426  
Email: [info@benchchem.com](mailto:info@benchchem.com)