

Technical Support Center: Flutemetamol ($[^{18}\text{F}]$) PET Scan Visual Interpretation

Author: BenchChem Technical Support Team. **Date:** December 2025

Compound of Interest

Compound Name: *Flutemetamol*

Cat. No.: *B1248471*

[Get Quote](#)

This technical support center provides troubleshooting guidance and frequently asked questions (FAQs) to assist researchers, scientists, and drug development professionals in improving the accuracy of visual reads for **Flutemetamol** ($[^{18}\text{F}]$) PET scans.

Frequently Asked Questions (FAQs)

Q1: What are the key principles for accurate visual interpretation of **Flutemetamol** ($[^{18}\text{F}]$) PET scans?

A1: Accurate visual interpretation of **Flutemetamol** ($[^{18}\text{F}]$) PET scans relies on a systematic approach. The scan is assessed for the presence or absence of amyloid plaques in the brain. A scan is considered positive if there is uptake in any of the five specified brain regions: frontal, lateral temporal, posterior cingulate/precuneus, temporo-parietal, and striatum.[1][2] It is crucial to use a recommended color scale, such as Sokoloff, Rainbow, or Spectrum, and to scale all images with the pons set to 90% of the maximum image intensity.[1] This standardized scaling allows for consistent interpretation of white and gray matter uptake within and between scans. [1] Reviewing available MRI or CT images can aid in interpretation, especially when atrophy is suspected, as this can potentially lead to false-negative results.[1]

Q2: How effective are electronic training programs for improving the accuracy of visual reads?

A2: Electronic training programs (ETPs) have been shown to be highly effective in training readers, even those without prior experience in amyloid PET image interpretation.[3][4][5] A study validating a self-guided ETP demonstrated that new readers achieved high sensitivity,

specificity, and inter-reader agreement.[3][4] The training typically covers brain anatomy, pathophysiology, image orientation, and the standardized interpretation methodology for **Flutemetamol** scans.[5]

Q3: What is the expected inter-rater and intra-rater reliability for visual interpretation of **Flutemetamol** (^{18}F) PET scans?

A3: Visual interpretation of **Flutemetamol** (^{18}F) PET scans generally demonstrates high inter-rater and intra-rater reliability. Studies have reported inter-rater agreement with Fleiss' kappa and Conger's kappa values around 0.83, indicating substantial agreement among readers.[6][7] Intra-reader reproducibility has been shown to be in the range of 93% to 100%.[3][4] However, variability can increase in cases with intermediate levels of amyloid accumulation, where confidence levels for a definitive positive or negative read are lower.[6][7]

Q4: How does visual interpretation compare to quantitative analysis methods like SUVR and Centiloid scales?

A4: Visual interpretation shows a high level of concordance with quantitative methods such as Standardized Uptake Value Ratio (SUVR) and the Centiloid (CL) scale.[8][9][10] One study found a 94.6% agreement between visual assessment and quantitative measures, with an SUVR cutoff of 1.13 and a CL cutoff of 16 providing the best concordance.[8][10] While visual reads are the approved method for clinical assessment, quantitative analysis can be a valuable tool to supplement interpretation, especially in equivocal cases.[8][11][12] Discordance between visual and quantitative reads is more common in cases with borderline amyloid levels.[13]

Q5: Can visual assessment determine the extent and location of amyloid pathology?

A5: Yes, visual assessment can provide information beyond a simple positive or negative result. Experienced readers can identify the specific brain regions with amyloid deposition.[2][14] Research has shown that the number of visually positive regions corresponds to an incremental increase in the quantitative Centiloid measurement, indicating that visual reads can offer a semi-quantitative assessment of the extent of amyloid pathology.[14]

Troubleshooting Guides

Issue 1: Inconsistent or Equivocal Scan Interpretations

- Problem: Difficulty in definitively classifying a scan as positive or negative, leading to low confidence in the read. This is more common in cases with intermediate amyloid burden.[\[6\]](#)
[\[7\]](#)
- Troubleshooting Steps:
 - Re-evaluate Image Quality: Ensure the scan is free of motion artifacts and that the full cerebrum is within the field of view.[\[1\]](#) Head motion can degrade image quality and reduce reading accuracy.[\[15\]](#)
 - Confirm Correct Image Scaling: Verify that the image intensity is scaled to 90% of the pons signal.[\[1\]](#) Incorrect scaling can alter the visual appearance of tracer uptake.
 - Systematic Regional Review: Methodically review all five specified brain regions (frontal, lateral temporal, posterior cingulate/precuneus, temporo-parietal, and striatum). A scan is positive if even one region shows clear uptake.[\[1\]](#)[\[2\]](#)
 - Consult Anatomic Imaging: Review corresponding MRI or CT scans to assess for brain atrophy, which can make visual interpretation more challenging.[\[1\]](#)
 - Utilize Quantitative Analysis: As an adjunct to visual interpretation, calculate SUVR or Centiloid values. These quantitative measures can provide objective data to support the visual read, especially in borderline cases.[\[8\]](#)[\[10\]](#)[\[16\]](#)
 - Seek a Second Opinion: Have another trained reader independently assess the scan to improve confidence and accuracy.

Issue 2: Discrepancies Between Readers (Low Inter-Rater Agreement)

- Problem: Different readers provide conflicting interpretations of the same scan.
- Troubleshooting Steps:
 - Standardize Reading Procedures: Ensure all readers are following the same standardized protocol for image display, scaling, and regional assessment as outlined in the official training materials.[\[3\]](#)[\[4\]](#)[\[5\]](#)

- Joint Reading Session: Conduct a reconciliation reading session where the disagreeing readers can review the case together and discuss their interpretations.[\[17\]](#)
- Review Training Materials: Encourage readers to revisit the electronic training program to reinforce the standardized methodology.[\[3\]](#)[\[4\]](#)
- Analyze Discrepant Cases: Identify if disagreements tend to occur in scans with specific characteristics (e.g., mild uptake, significant atrophy) to pinpoint areas for further training or protocol refinement.

Data Presentation

Table 1: Performance of Trained Readers in **Flutemetamol** (^{18}F) PET Scan Interpretation

Performance Metric	Result	Source
Sensitivity	84% to 94%	[3] [4]
Specificity	77% to 96%	[3] [4]
Intra-reader Reproducibility	93% to 100%	[3] [4]
Inter-reader Agreement (κ score)	> 0.8	[3] [4]

Table 2: Concordance Between Visual and Quantitative Assessments

Comparison	Concordance/ Accuracy	SUVR Cutoff	Centiloid (CL) Cutoff	Source
Visual vs. Quantitative (SUVR/CL)	94.6% Accuracy	1.13	16	[8][10]
Visual vs. Quantitative (SUVR)	97% Accuracy	1.41	N/A	[16]
Visual vs. Centiloid (CL=12)	95.2% Agreement (κ = 0.89)	N/A	12	[9]
Visual vs. Centiloid (CL=30)	95.4% Agreement (κ = 0.88)	N/A	30	[9]

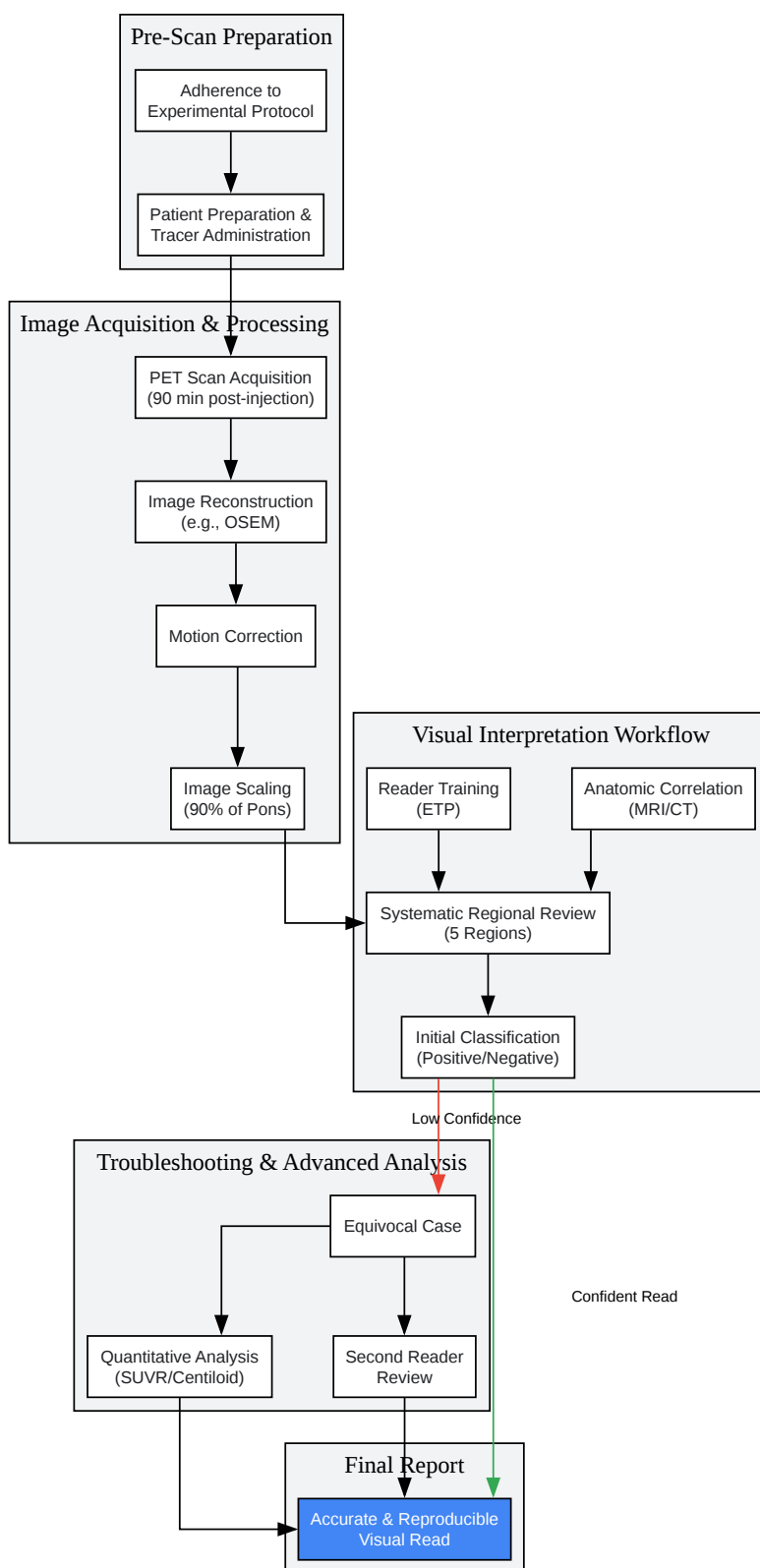
Experimental Protocols

Key Methodological Parameters for **Flutemetamol** ($[^{18}\text{F}]$) PET Imaging and Interpretation

- **Tracer Injection:** Intravenous bolus injection of **Flutemetamol** ($[^{18}\text{F}]$). A typical dose is around 185-270 MBq.[8][18]
- **Scan Acquisition Time:** A 20-minute PET scan is typically initiated approximately 90 minutes post-injection.[1] The recommended window for starting the scan is 60-120 minutes after tracer injection.[8][18]
- **Image Reconstruction:** Ordered subsets expectation maximization (OSEM) is a commonly used reconstruction method.[8]
- **Image Orientation and Quality Control:** Images should be checked for rotation or tilt and realigned if necessary. They should also be assessed for motion artifacts.[1] Data-driven motion correction algorithms can improve image quality and inter-reader agreement.[15]
- **Visual Interpretation Procedure:**

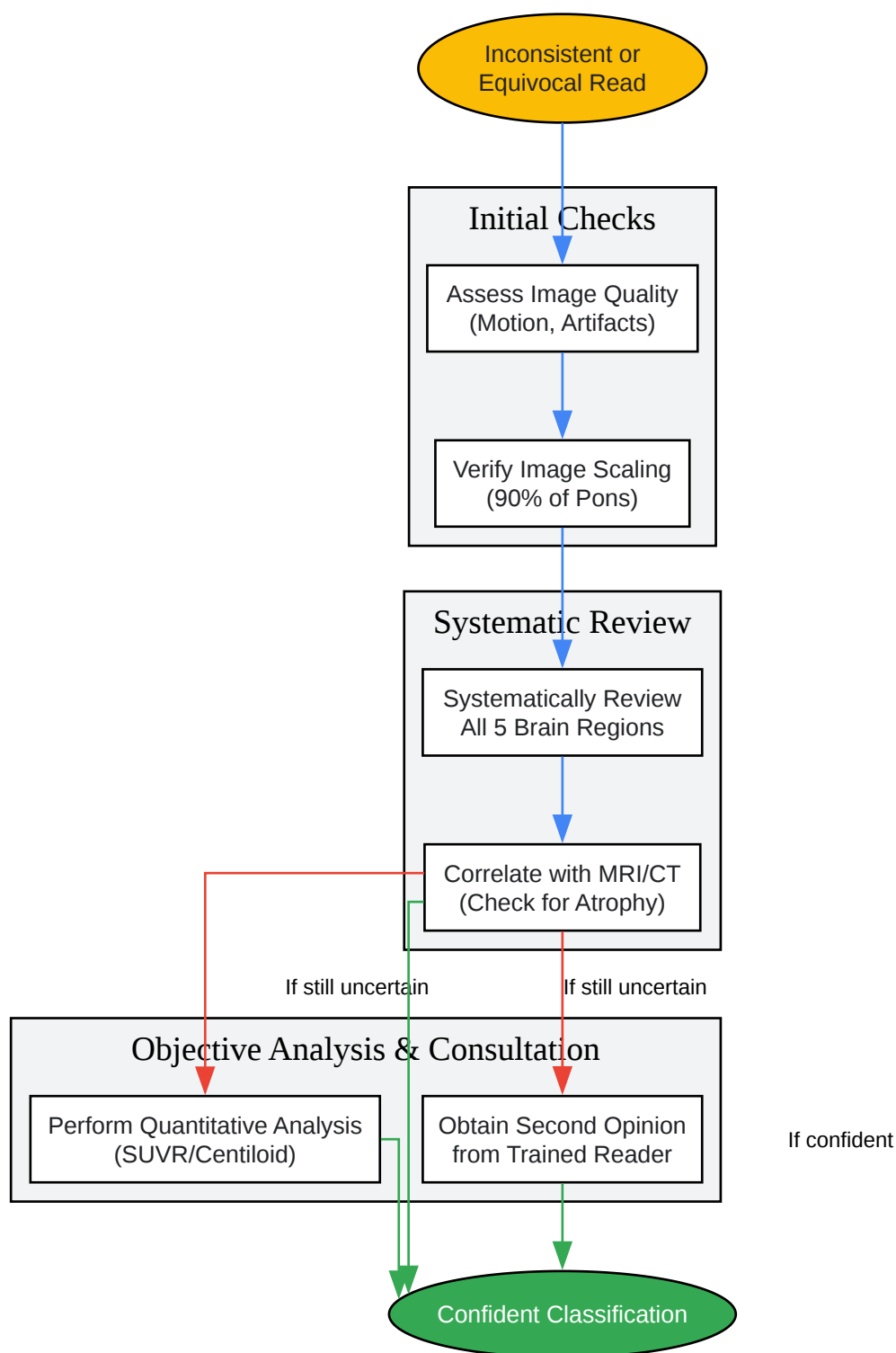
- Images are scaled to 90% of the pons' maximum intensity.[\[1\]](#)
- A systematic review of five brain regions is conducted: frontal, lateral temporal, posterior cingulate/precuneus, temporo-parietal, and striatum.[\[1\]](#)[\[2\]](#)
- A scan is classified as positive if any of these regions show amyloid deposition.[\[1\]](#)[\[2\]](#)
- Anatomic images (CT or MRI) should be reviewed alongside the PET scan to aid interpretation, particularly in cases of suspected atrophy.[\[1\]](#)

Mandatory Visualizations



[Click to download full resolution via product page](#)

Workflow for Improving Visual Read Accuracy



[Click to download full resolution via product page](#)

Troubleshooting Equivocal Visual Reads

Need Custom Synthesis?

BenchChem offers custom synthesis for rare earth carbides and specific isotopic labeling.

Email: info@benchchem.com or [Request Quote Online](#).

References

- 1. gehealthcare.se [gehealthcare.se]
- 2. researchgate.net [researchgate.net]
- 3. Validation of an electronic image reader training programme for interpretation of [18F]flutemetamol β -amyloid PET brain images - PMC [pmc.ncbi.nlm.nih.gov]
- 4. Validation of an electronic image reader training programme for interpretation of [18F]flutemetamol β -amyloid PET brain images - PubMed [pubmed.ncbi.nlm.nih.gov]
- 5. researchgate.net [researchgate.net]
- 6. Interrater agreement and variability in visual reading of [18F] flutemetamol PET images - PubMed [pubmed.ncbi.nlm.nih.gov]
- 7. researchgate.net [researchgate.net]
- 8. Frontiers | Quantitative Evaluation of 18F-Flutemetamol PET in Patients With Cognitive Impairment and Suspected Alzheimer's Disease: A Multicenter Study [frontiersin.org]
- 9. Visual assessment of [18F]flutemetamol PET images can detect early amyloid pathology and grade its extent - PMC [pmc.ncbi.nlm.nih.gov]
- 10. Quantitative Evaluation of 18F-Flutemetamol PET in Patients With Cognitive Impairment and Suspected Alzheimer's Disease: A Multicenter Study - PMC [pmc.ncbi.nlm.nih.gov]
- 11. Is Amyloid Burden Measured by 18F-Flutemetamol PET Associated with Progression in Clinical Alzheimer's Disease? - PMC [pmc.ncbi.nlm.nih.gov]
- 12. m.youtube.com [m.youtube.com]
- 13. emjreviews.com [emjreviews.com]
- 14. Alzheimer's: visual assessment of [18F]flutemetamol PET can reveal not only presence but also extent and location of amyloid | IHI Innovative Health Initiative [ihi.europa.eu]
- 15. Improving diagnostic precision in amyloid brain PET imaging through data-driven motion correction - PMC [pmc.ncbi.nlm.nih.gov]
- 16. jnm.snmjournals.org [jnm.snmjournals.org]

- 17. Visual assessments of 11C-Pittsburgh compound-B PET vs 18F-Flutemetamol PET across the age spectrum - PMC [pmc.ncbi.nlm.nih.gov]
- 18. Sequential scans of 18F-flutemetamol PET using PET/CT and PET/MRI: influence of amyloid burden, scan interval, and age | springermedizin.de [springermedizin.de]
- To cite this document: BenchChem. [Technical Support Center: Flutemetamol (^{18}F) PET Scan Visual Interpretation]. BenchChem, [2025]. [Online PDF]. Available at: [https://www.benchchem.com/product/b1248471#improving-the-accuracy-of-visual-reads-for-flutemetamol-pet-scans]

Disclaimer & Data Validity:

The information provided in this document is for Research Use Only (RUO) and is strictly not intended for diagnostic or therapeutic procedures. While BenchChem strives to provide accurate protocols, we make no warranties, express or implied, regarding the fitness of this product for every specific experimental setup.

Technical Support: The protocols provided are for reference purposes. Unsure if this reagent suits your experiment? [[Contact our Ph.D. Support Team for a compatibility check](#)]

Need Industrial/Bulk Grade? [Request Custom Synthesis Quote](#)

BenchChem

Our mission is to be the trusted global source of essential and advanced chemicals, empowering scientists and researchers to drive progress in science and industry.

Contact

Address: 3281 E Guasti Rd
Ontario, CA 91761, United States
Phone: (601) 213-4426
Email: info@benchchem.com