

Technical Support Center: ^{18}F -DCFBC PET/CT Imaging

Author: BenchChem Technical Support Team. **Date:** December 2025

Compound of Interest

Compound Name: Dcfbc

Cat. No.: B1669887

[Get Quote](#)

This technical support center provides troubleshooting guidance and frequently asked questions (FAQs) for researchers, scientists, and drug development professionals utilizing ^{18}F -DCFBC PET/CT imaging.

Frequently Asked Questions (FAQs)

Q1: What is the normal biodistribution of ^{18}F -DCFBC and where can I expect to see physiological uptake?

A1: ^{18}F -DCFBC, a PSMA-targeted radiotracer, exhibits a characteristic biodistribution pattern. Intense physiological uptake is typically observed in the kidneys, due to high PSMA expression and urinary excretion of the tracer. High to moderate uptake is also seen in the salivary and lacrimal glands. The liver and spleen show moderate uptake, while there is variable, lower-level uptake in the small intestine and colon. Recognizing this normal distribution is crucial to avoid misinterpreting physiological uptake as metastatic disease.

Q2: What are the common causes of false-positive findings on an ^{18}F -DCFBC PET/CT scan?

A2: False-positive findings can arise from several sources. As prostate-specific membrane antigen (PSMA) is not entirely specific to prostate cancer, other tissues and conditions can show uptake. These include:

- Benign Prostatic Hyperplasia (BPH): BPH nodules can exhibit ^{18}F -DCFBC uptake, though typically at a lower intensity than clinically significant prostate cancer.[\[1\]](#)[\[2\]](#)[\[3\]](#)[\[4\]](#)[\[5\]](#)

- Inflammation and Infection: Inflammatory processes, such as prostatitis or post-surgical inflammation, can lead to increased radiotracer accumulation.[6]
- Other Tumors: Various other malignancies can express PSMA, including some lung, breast, and neuroendocrine tumors.[7]
- Benign Bone Lesions: Conditions like fibrous dysplasia, Paget's disease, and even healing fractures can show ^{18}F -**DCFBC** uptake.[8]
- Sympathetic Ganglia: Celiac and sacral ganglia can demonstrate physiological uptake and should not be mistaken for lymph node metastases.

Q3: Can a patient have prostate cancer and a negative ^{18}F -**DCFBC** PET/CT scan?

A3: Yes, this is possible and represents a potential pitfall of PSMA-targeted imaging. Approximately 5-10% of prostate cancers do not express PSMA and will therefore not be detected on an ^{18}F -**DCFBC** PET/CT scan.[7] Additionally, very small lesions, typically less than 4mm, may not be detectable due to the spatial resolution limitations of PET imaging.[7]

Q4: Does the use of intravenous (IV) CT contrast media affect the accuracy of ^{18}F -**DCFBC** PET/CT imaging?

A4: The use of IV iodinated contrast for the CT portion of a PET/CT scan can theoretically lead to an overestimation of PET signal due to errors in attenuation correction. However, studies have shown that while a statistically significant increase in Standardized Uptake Values (SUV) can occur in areas of high contrast concentration, this increase is generally not considered clinically significant and is unlikely to alter the diagnostic interpretation of the scan.

Troubleshooting Guide

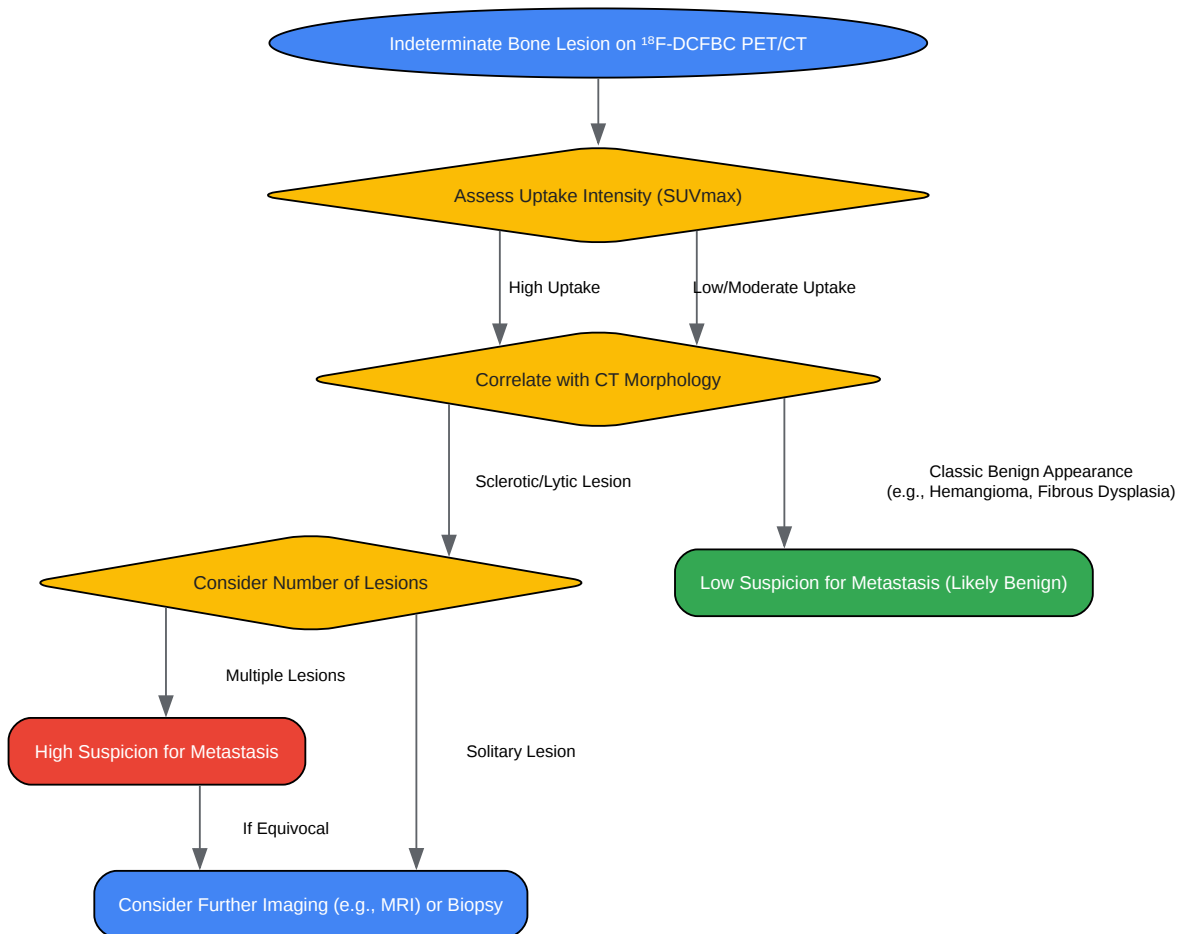Issue 1: Intense urinary activity in the bladder obscures the prostate or pelvic lymph nodes.

- Cause: ^{18}F -**DCFBC** is excreted through the urinary system, leading to high concentrations of the radiotracer in the bladder. This can create "hot spots" that make it difficult to evaluate adjacent structures.
- Troubleshooting Steps:

- Patient Hydration: Ensure the patient is well-hydrated before and after the radiotracer injection to promote diuresis.
- Pre-Scan Voiding: Instruct the patient to void immediately before the PET/CT scan to minimize the amount of radioactive urine in the bladder.
- Diuretic Administration: In some cases, a diuretic like furosemide can be administered to enhance tracer washout from the urinary tract. Delayed imaging after diuretic administration may improve visualization of the pelvic region.[\[9\]](#)[\[10\]](#)
- Delayed Imaging: Acquiring images at a later time point (e.g., 2 hours post-injection) may sometimes improve the tumor-to-background ratio as tracer clears from the urinary system.

Issue 2: An indeterminate bone lesion is identified. How can I differentiate between a metastatic lesion and a benign finding?

- Cause: Both malignant and some benign bone conditions can exhibit PSMA uptake.
- Troubleshooting Workflow:



[Click to download full resolution via product page](#)

Caption: Troubleshooting workflow for indeterminate bone lesions.

- Step 1: Evaluate Uptake Intensity: Metastatic lesions from prostate cancer generally demonstrate higher ^{18}F -**DCFBC** uptake compared to benign bone pathologies.[2]

- Step 2: Correlate with CT Findings: Carefully examine the CT portion of the scan for morphological features. Benign lesions like hemangiomas (with characteristic trabecular patterns) or fibrous dysplasia (ground-glass appearance) often have a distinct look.^{[2][8]} Metastases are more commonly associated with sclerotic or lytic changes.^[11]
- Step 3: Consider the Number of Lesions: Multiple lesions are more suggestive of metastatic disease, whereas a single lesion may be more likely to be benign.^[2]
- Step 4: Clinical Correlation and Further Imaging: Correlate the findings with the patient's clinical history and PSA levels. If the diagnosis remains uncertain, further imaging with MRI or a biopsy may be necessary.

Issue 3: Motion artifacts are present in the pelvic region, leading to blurring and misregistration between PET and CT images.

- Cause: Patient movement during the scan, including respiratory motion, can cause a misalignment between the PET and CT data, resulting in inaccurate localization and quantification of tracer uptake.
- Troubleshooting Steps:
 - Patient Comfort and Immobilization: Ensure the patient is in a comfortable position to minimize voluntary movement. Immobilization devices can be used if necessary.
 - Clear Instructions: Instruct the patient to breathe shallowly and avoid movement during the acquisition, especially for the pelvic region.
 - Shorter Acquisition Times: Where possible, using a scanner with higher sensitivity and optimizing the protocol to reduce the scan time per bed position can minimize the window for patient motion.
 - Motion Correction Software: Some modern PET/CT systems are equipped with motion correction software that can retrospectively correct for motion artifacts.
 - Repeat Acquisition: If significant motion is detected during the scan, it may be necessary to repeat the acquisition for the affected area.

Quantitative Data Summary

The following tables summarize key quantitative data from studies on ^{18}F -**DCFBC** and other PSMA PET tracers to aid in image interpretation.

Table 1: Comparison of ^{18}F -**DCFBC** Uptake in Prostate Tissues

Tissue Type	Median SUVmax	Reference
Primary Prostate Cancer	3.5	[1][5]
Benign Prostatic Hyperplasia (BPH)	2.2	[1][5]
Normal Prostate Tissue	2.1 \pm 0.4 (mean \pm SD)	[4]

Table 2: ^{18}F -**DCFBC** PET/CT Detection Rates by PSA Level in Biochemical Recurrence

PSA Level (ng/mL)	Detection Rate	Reference
< 0.5	15%	[6][12]
0.5 to < 1.0	46%	[6][12]
1.0 to < 2.0	83%	[6][12]
\geq 2.0	77%	[6][12]

Experimental Protocols

1. Patient Preparation Protocol for ^{18}F -**DCFBC** PET/CT

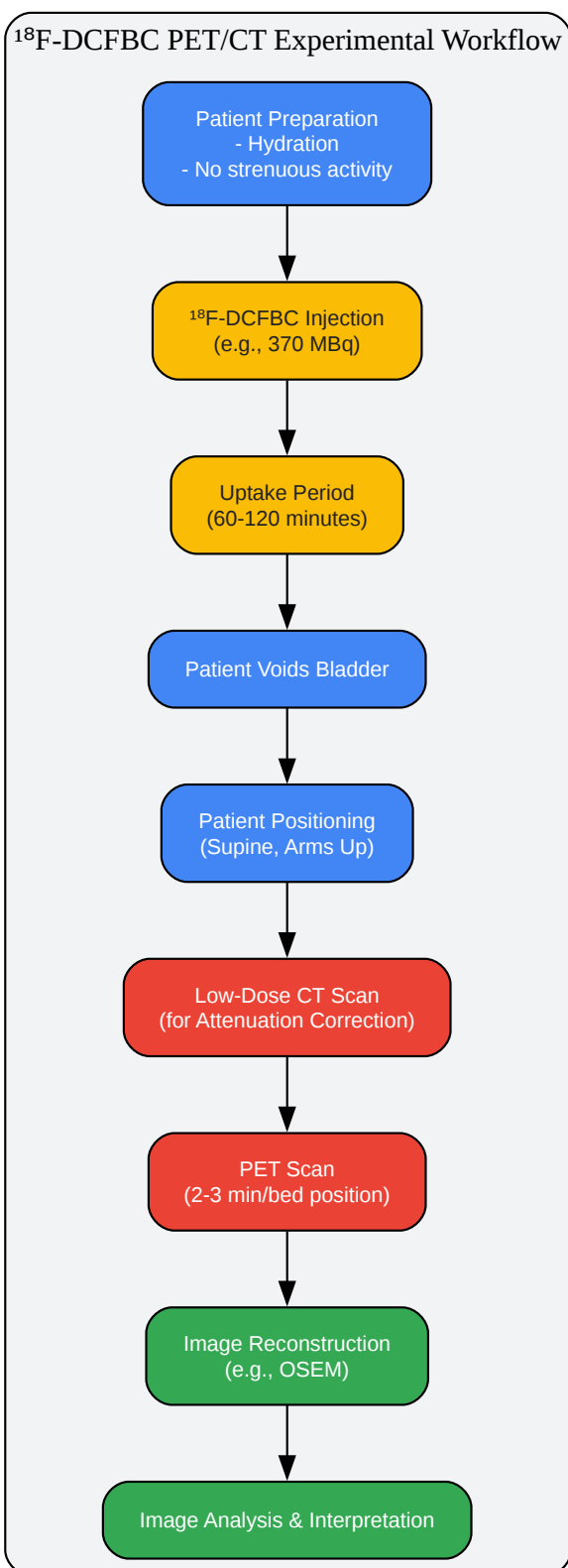
- Dietary Restrictions:** No specific dietary restrictions such as fasting or a low-carbohydrate diet are typically required for ^{18}F -**DCFBC** imaging, unlike ^{18}F -FDG PET/CT.
- Hydration:** Patients should be encouraged to drink plenty of water (approximately 1-2 liters) starting 1-2 hours before the scan and continuing after the injection to ensure adequate hydration and promote clearance of the radiotracer from the urinary system.

- Medications: Patients can generally continue to take their routine medications.
- Physical Activity: Strenuous physical activity should be avoided for 24 hours prior to the scan to prevent non-specific muscle uptake.
- Pre-injection: A recent serum creatinine level should be available. An intravenous line will be placed for the radiotracer injection.

2. ^{18}F -DCFBC PET/CT Imaging Protocol

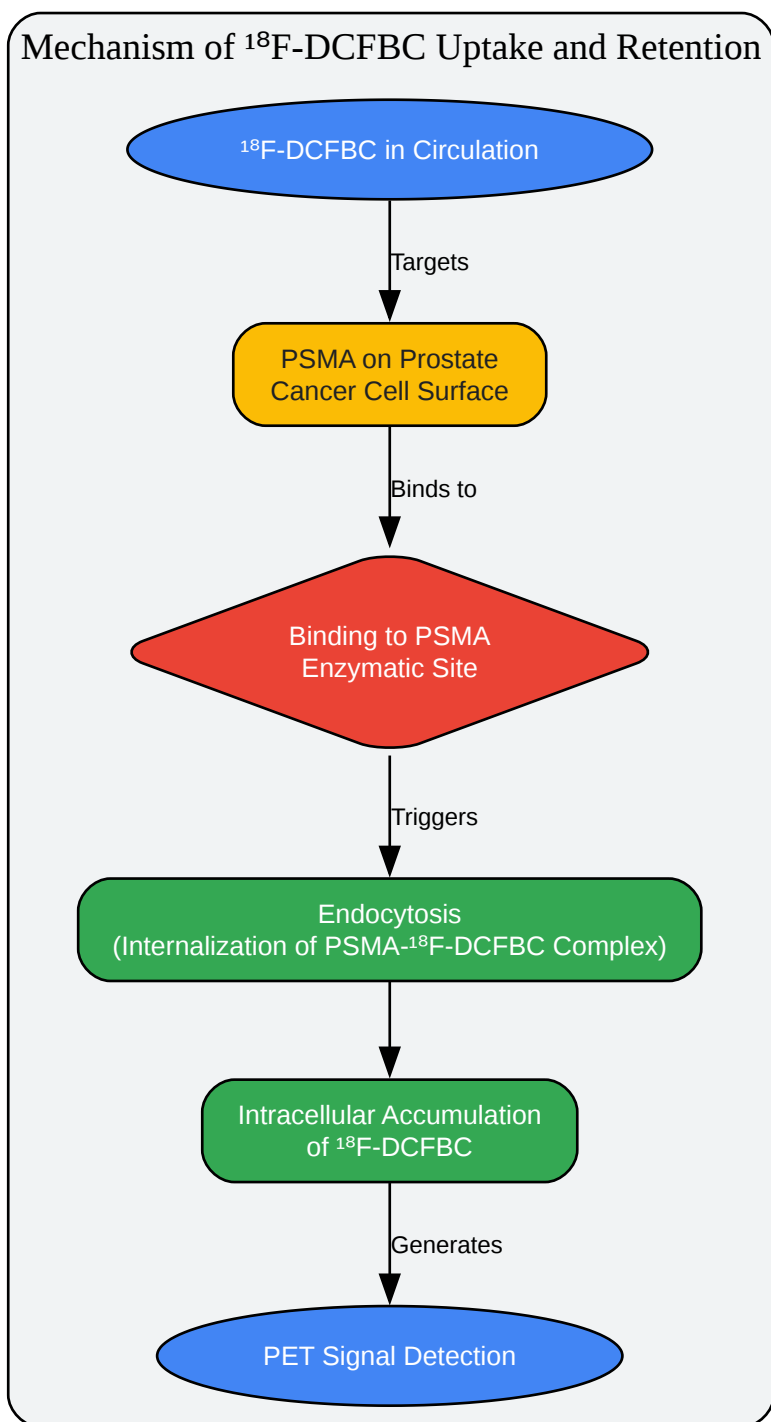
- Radiotracer Dose: A typical intravenous bolus injection of 370 MBq (10 mCi) of ^{18}F -DCFBC is administered.[2]
- Uptake Period: The patient should rest in a quiet room for an uptake period of 60 to 120 minutes.[1][2]
- Patient Positioning: The patient is positioned supine on the scanner bed with their arms raised above their head if possible to avoid artifacts in the torso.
- CT Acquisition: A low-dose CT scan is performed for attenuation correction and anatomical localization. Typical parameters are 120 kVp and 60-80 mA.[2][6]
- PET Acquisition: Whole-body PET images are acquired from the mid-thigh to the base of the skull. The acquisition time is typically 2-3 minutes per bed position.
- Image Reconstruction: PET images are reconstructed using an iterative algorithm such as Ordered Subset Expectation Maximization (OSEM).[2]

Visualizations



[Click to download full resolution via product page](#)

Caption: Standard experimental workflow for ^{18}F -DCFBC PET/CT.



[Click to download full resolution via product page](#)

Caption: ^{18}F -DCFBC uptake and internalization by PSMA-expressing cells.

Need Custom Synthesis?

BenchChem offers custom synthesis for rare earth carbides and specific isotopic labeling.

Email: info@benchchem.com or [Request Quote Online](#).

References

- 1. A Prospective Comparison of ^{18}F -Sodium Fluoride PET/CT and PSMA-Targeted ^{18}F -DCFBC PET/CT in Metastatic Prostate Cancer | Journal of Nuclear Medicine [jnm.snmjournals.org]
- 2. ^{18}F -DCFBC PET/CT for PSMA-Based Detection and Characterization of Primary Prostate Cancer - PMC [pmc.ncbi.nlm.nih.gov]
- 3. documentsdelivered.com [documentsdelivered.com]
- 4. semiquantitative-parameters-in-psma-targeted-pet-imaging-with-18-f-dcfpyl-variability-in-normal-organ-uptake - Ask this paper | Bohrium [bohrium.com]
- 5. urotoday.com [urotoday.com]
- 6. Clinical impact of PSMA-based ^{18}F —DCFBC PET/CT imaging in patients with biochemically recurrent prostate cancer after primary local therapy - PMC [pmc.ncbi.nlm.nih.gov]
- 7. jnm.snmjournals.org [jnm.snmjournals.org]
- 8. Improvement of motion artifacts using dynamic whole-body ^{18}F -FDG PET/CT imaging - PMC [pmc.ncbi.nlm.nih.gov]
- 9. ^{18}F -DCFBC PET/CT for PSMA-Based Detection and Characterization of Primary Prostate Cancer - PubMed [pubmed.ncbi.nlm.nih.gov]
- 10. ^{18}F -FDG PET/CT Imaging: Normal Variants, Pitfalls, and Artifacts Musculoskeletal, Infection, and Inflammation - PMC [pmc.ncbi.nlm.nih.gov]
- 11. jnm.snmjournals.org [jnm.snmjournals.org]
- 12. Clinical impact of PSMA-based ^{18}F -DCFBC PET/CT imaging in patients with biochemically recurrent prostate cancer after primary local therapy - PubMed [pubmed.ncbi.nlm.nih.gov]
- To cite this document: BenchChem. [Technical Support Center: ^{18}F -DCFBC PET/CT Imaging]. BenchChem, [2025]. [Online PDF]. Available at: [https://www.benchchem.com/product/b1669887#artifacts-and-pitfalls-in-f-dcfbc-pet-ct-imaging]

Disclaimer & Data Validity:

The information provided in this document is for Research Use Only (RUO) and is strictly not intended for diagnostic or therapeutic procedures. While BenchChem strives to provide accurate protocols, we make no warranties, express or implied, regarding the fitness of this product for every specific experimental setup.

Technical Support: The protocols provided are for reference purposes. Unsure if this reagent suits your experiment? [[Contact our Ph.D. Support Team for a compatibility check](#)]

Need Industrial/Bulk Grade? [Request Custom Synthesis Quote](#)

BenchChem

Our mission is to be the trusted global source of essential and advanced chemicals, empowering scientists and researchers to drive progress in science and industry.

Contact

Address: 3281 E Guasti Rd
Ontario, CA 91761, United States
Phone: (601) 213-4426
Email: info@benchchem.com