

Technical Support Center: Enhancing Liver Imaging Resolution in GSD-I

Author: BenchChem Technical Support Team. **Date:** December 2025

Compound of Interest

Compound Name: GSD-1

Cat. No.: B1192801

[Get Quote](#)

This technical support center provides researchers, scientists, and drug development professionals with comprehensive guidance on advanced liver imaging techniques for Glycogen Storage Disease Type I (GSD-I). It includes troubleshooting guides, frequently asked questions (FAQs), detailed experimental protocols, and comparative data to address specific issues encountered during experimental procedures.

Section 1: Frequently Asked Questions (FAQs)

Q1: What are the primary imaging modalities for monitoring liver health in GSD-I? A: The primary modalities are ultrasound and Magnetic Resonance Imaging (MRI). Ultrasound is often the first-line method for pediatric patients due to its accessibility and lack of ionizing radiation.^[1] It is used to assess liver size (hepatomegaly), echogenicity (which is often increased), and to screen for focal liver lesions (FLLs).^{[2][3]} MRI is recommended for routine surveillance, especially in patients over 16 or when adenomas are detected, due to its superior soft-tissue contrast and ability to characterize lesions more accurately.^{[1][4]}

Q2: Why is MRI often preferred over ultrasound for surveillance in older GSD-I patients? A: MRI offers higher soft tissue contrast, which is crucial for detecting and characterizing hepatic tumors within a steatotic (fatty) liver, a common feature of GSD-I.^{[1][5]} It allows for the use of advanced techniques like Diffusion-Weighted Imaging (DWI) and dynamic contrast enhancement, which improve the differentiation between benign hepatic adenomas (HCAs) and malignant hepatocellular carcinoma (HCC).^[1] MRI is also less operator-dependent and provides a more comprehensive assessment of the entire liver.

Q3: What is the role of Gd-EOB-DTPA (Gadoxetate Disodium) in GSD-I liver imaging? A: Gd-EOB-DTPA is a hepatocyte-specific MRI contrast agent that is taken up by functional liver cells. This unique property is highly valuable in GSD-I for differentiating various types of liver nodules.[1] During the hepatobiliary phase (around 20 minutes post-injection), lesions without functional hepatocytes, like most HCAs and HCCs, will appear hypointense (dark) compared to the enhancing background liver parenchyma.[6][7] This enhances lesion detection and characterization. Regenerative nodules, however, typically show high signal intensity in this phase.[1]

Q4: How can we non-invasively assess liver fibrosis in GSD-I? A: Liver fibrosis can be non-invasively assessed by measuring liver stiffness using elastography techniques.[8] The two main methods are Ultrasound Elastography (specifically Shear Wave Elastography, SWE) and Magnetic Resonance Elastography (MRE).[9][10] MRE is considered a highly accurate and reproducible method for staging liver fibrosis.[11][12] These techniques measure the speed of shear waves propagating through the liver; stiffer, more fibrotic tissue allows waves to travel faster.[13]

Q5: What are the challenges in differentiating Hepatic Adenoma (HCA) from Hepatocellular Carcinoma (HCC) in GSD-I? A: Differentiating HCA from HCC is a primary challenge because both can present as hypervascular lesions in the arterial phase on contrast-enhanced CT or MRI.[14] While "washout" in the portal venous or delayed phase is a hallmark of HCC, some HCAs can also exhibit this feature, making diagnosis difficult.[15] Furthermore, GSD-I patients can have multiple adenomas, and malignant transformation can occur within a pre-existing adenoma.[6] Advanced imaging with agents like Gd-EOB-DTPA and careful analysis of features like lesion size, growth, and signal characteristics are crucial for accurate diagnosis.[6][16]

Section 2: Troubleshooting Guides

Q1: Issue - Poor image quality in MRI due to severe hepatic steatosis. A: Hepatic steatosis (fatty liver) is nearly universal in GSD-I and can cause artifacts and reduce the sensitivity of lesion detection.

- Recommended Solution: Utilize fat-suppression techniques. Chemical shift imaging sequences like the Dixon method are highly effective not only for suppressing the fat signal but also for quantifying the fat fraction.[1] For contrast-enhanced and diffusion-weighted

sequences, robust fat suppression is critical to clearly identify hepatic tumors.[1] T1-weighted in-phase and out-of-phase imaging can confirm the presence of diffuse steatosis.[17]

Q2: Issue - Suboptimal arterial phase enhancement with Gd-EOB-DTPA. A: Achieving a robust arterial phase can be challenging with Gd-EOB-DTPA due to its lower recommended dose (0.025 mmol/kg) compared to conventional extracellular agents.

- Recommended Solution: Precise timing of the arterial phase is critical. The use of an automated bolus tracking technique is highly recommended.[18] The operator should monitor the real-time arrival of the contrast bolus in the heart or aorta and initiate the arterial phase sequence immediately upon its arrival to ensure optimal visualization of hypervascular lesions.[18]

Q3: Issue - Inconsistent or unreliable liver stiffness measurements with elastography. A: Liver stiffness measurements can be affected by patient-related factors (fasting state, breathing) and technical execution.

- Recommended Solution: Adherence to a standardized protocol is mandatory.
 - Patient Preparation: Patients should fast for at least 2-4 hours to minimize the confounding effect of postprandial blood flow on liver stiffness.[19][20]
 - Technique (SWE): Measurements should be taken in the right lobe of the liver through an intercostal space, with the patient in a supine position and the right arm in maximal extension.[19] The acquisition should occur during a neutral breath-hold to avoid motion.[21]
 - Quality Control: For SWE, the interquartile range/median (IQR/M) ratio should be checked. A ratio of $\leq 30\%$ (for kPa) or $\leq 15\%$ (for m/s) is considered a reliable measurement.[19][22] For MRE, review the wave images to ensure adequate wave propagation through the liver.[23]

Q4: Issue - Difficulty characterizing small (<1 cm) focal liver lesions with baseline ultrasound. A: Small lesions detected on screening ultrasound can be indeterminate, as features may be nonspecific.

- Recommended Solution: Proceed with a more advanced imaging modality.

- Contrast-Enhanced Ultrasound (CEUS): CEUS is an excellent problem-solving tool that can be performed in the same session. It provides real-time visualization of the lesion's enhancement pattern through arterial, portal, and late phases, which is crucial for characterization.[\[15\]](#)[\[24\]](#)
- Gd-EOB-DTPA Enhanced MRI: For a comprehensive evaluation and higher resolution, MRI with a hepatocyte-specific agent is the preferred next step, especially for detecting additional lesions and providing detailed anatomical information.

Section 3: Experimental Protocols

Protocol 1: High-Resolution Liver MRI with Gd-EOB-DTPA

- Patient Preparation: Patient should fast for at least 4 hours prior to the exam to ensure optimal gallbladder distention and hepatobiliary contrast uptake.
- Sequences (Pre-Contrast):
 - T1-Weighted In-Phase and Out-of-Phase (Dixon/GRE): Axial plane to assess for hepatic steatosis and iron deposition.[\[17\]](#)
 - T2-Weighted Single-Shot (HASTE): Axial and coronal planes for anatomical overview.
 - T2-Weighted Fat-Saturated (TSE/FSE): Axial plane to assess T2 signal of focal lesions.[\[25\]](#)
 - Diffusion-Weighted Imaging (DWI): Axial plane with multiple b-values (e.g., 50, 400, 800 s/mm²) and corresponding ADC maps to evaluate for restricted diffusion in malignant lesions.[\[25\]](#)
- Contrast Administration:
 - Agent: Gadoxetate Disodium (Gd-EOB-DTPA).
 - Dosage: Standard dose of 0.025 mmol/kg body weight.
- Sequences (Post-Contrast):

- Dynamic T1-Weighted 3D Gradient-Echo (e.g., VIBE/LAVA) with Fat Saturation: Acquire multiple phases after contrast injection.
 - Late Arterial Phase: ~20-30 seconds post-injection (use bolus tracking).[17]
 - Portal Venous Phase: ~60-70 seconds post-injection.[17]
 - Transitional/Equilibrium Phase: ~3-5 minutes post-injection.[17]
- Hepatobiliary Phase:
 - Timing: 20 minutes post-injection.[17]
 - Sequence: T1-weighted 3D gradient-echo (with and without fat saturation). This phase is critical for differentiating lesions based on hepatocyte function.[1]

Protocol 2: Contrast-Enhanced Ultrasound (CEUS) for Focal Liver Lesion Characterization

- Patient Preparation: Fasting for at least 4 hours is recommended.
- Baseline Ultrasound: Perform a complete grayscale and color Doppler examination of the liver to identify and localize the target lesion(s).
- Contrast Agent & Injection:
 - Agent: Use an approved ultrasound contrast agent (e.g., SonoVue).
 - Injection: Administer a bolus injection of the agent via an intravenous line, followed by a saline flush.
- Imaging Acquisition:
 - Technique: Use a low mechanical index (MI) contrast-specific imaging mode.
 - Real-Time Observation: Continuously image the target lesion for at least 3-5 minutes post-injection.

- Phases:
 - Arterial Phase (0-40 seconds): Observe the initial pattern of enhancement (e.g., peripheral nodular, diffuse, stellate).[21]
 - Portal Venous Phase (40-120 seconds): Assess for sustained enhancement or washout.
 - Late Phase (>120 seconds): Look for the degree and timing of washout (rapid and complete washout suggests malignancy other than HCC; late and weak washout can be seen in HCC).[14]
- Data Recording: Record digital cine clips of the entire enhancement and washout process for post-examination analysis.

Protocol 3: Ultrasound-based Shear Wave Elastography (SWE)

- Patient Preparation: Fasting for a minimum of 4 hours is required.[20]
- Patient Positioning: Supine or slight left lateral decubitus position, with the right arm raised above the head to widen the intercostal spaces.[19][20]
- Transducer & Location: Use a standard curvilinear transducer. Place it in a right intercostal space to obtain a clear view of the right liver lobe, avoiding large vessels, biliary ducts, and the liver edge.[21]
- Image Acquisition:
 - The region of interest (ROI) box should be placed in a homogeneous area of the liver parenchyma, at least 1.5-2.0 cm deep to the liver capsule to avoid reverberation artifacts. [21]
 - Instruct the patient to hold their breath in a neutral, relaxed state (not a deep inspiration or expiration).[21]
 - Acquire a stable, high-quality elastogram.
- Measurements & Quality Control:

- Obtain approximately 10 valid measurements.
- Calculate the median stiffness value in kilopascals (kPa) or meters per second (m/s).
- Ensure the Interquartile Range/Median (IQR/M) is $\leq 30\%$ for kPa or $\leq 15\%$ for m/s for a reliable result.[\[19\]](#)[\[22\]](#)

Protocol 4: Magnetic Resonance Elastography (MRE)

- Patient Preparation: Fasting for 4-6 hours is recommended.
- Hardware Setup:
 - Place a passive driver (a small, drum-like paddle) on the patient's right anterior abdominal wall, overlying the liver. Secure it with an abdominal binder.
 - Connect the passive driver to an active driver outside the magnet room, which generates low-frequency (e.g., 60 Hz) mechanical waves.[\[20\]](#)[\[26\]](#)
- Sequence Acquisition:
 - Technique: Use a specialized gradient-echo MRE sequence that is synchronized with the mechanical waves.
 - Imaging: Acquire 4-5 axial slices through the liver during a single 15-20 second breath-hold.[\[26\]](#)
- Data Processing & Analysis:
 - The raw phase-contrast images (wave images) are automatically processed by the scanner's software to generate quantitative stiffness maps (elastograms).
 - Draw a large region of interest (ROI) over the liver parenchyma on the elastogram, avoiding large vessels and the liver edge.[\[23\]](#)
 - The software calculates the mean stiffness value in kPa for the ROI. The mean of all slices is reported as the final liver stiffness value.[\[23\]](#)

Section 4: Data Presentation

Table 1: Comparison of Liver Imaging Modalities in GSD-

Feature	Ultrasound (US)	Contrast-Enhanced US (CEUS)	Magnetic Resonance Imaging (MRI)	MR Elastography (MRE)
Primary Use	Initial screening, size/echotexture assessment[2]	Characterization of focal liver lesions[15]	Lesion detection & characterization, steatosis quantification[1]	Quantitative staging of liver fibrosis[12]
Resolution	Good	Good (dynamic)	Excellent	N/A (provides stiffness map)
Key Advantage	Accessible, no radiation, low cost	Real-time vascular assessment, safe in renal failure[15]	Superior soft-tissue contrast, multi-parametric capability[1]	High accuracy and reproducibility for fibrosis staging[11]
Key Limitation	Operator dependent, limited in severe steatosis/obesity	Limited field of view, cannot assess entire liver at once	Higher cost, longer scan time, contrast contraindications	Requires specific hardware, limited availability
Ionizing Radiation	No	No	No	No

Table 2: Typical MRI Findings in GSD-I Liver Lesions (Post Gd-EOB-DTPA)

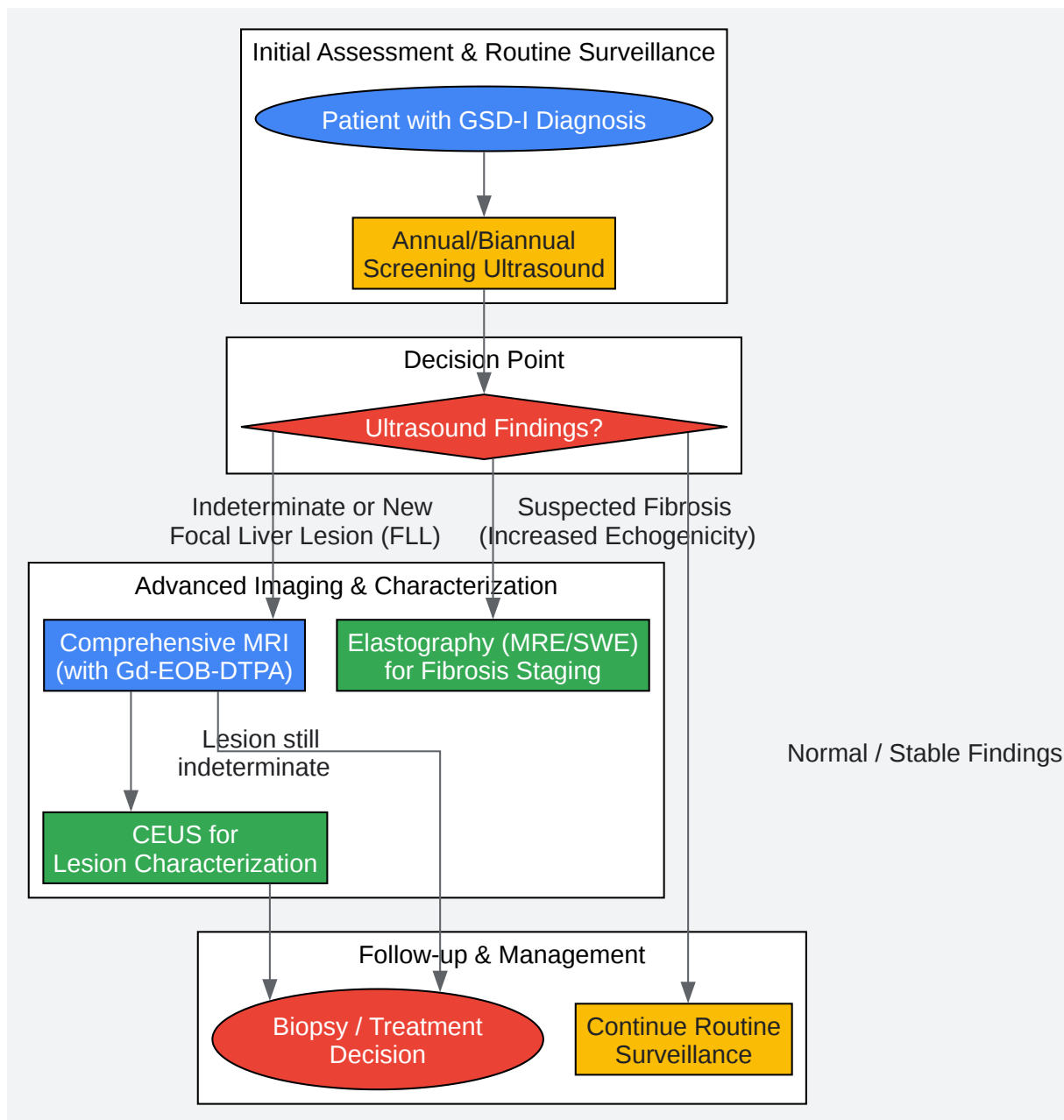
Lesion Type	Arterial Phase	Portal Venous Phase	Hepatobiliary Phase (20 min)	Key Differentiator
Hepatic Adenoma (HCA)	Typically hyperenhancement	Often becomes isointense or shows mild washout	Markedly hypointense (no contrast uptake) [7]	Lack of hepatocyte-specific contrast uptake is characteristic.
Hepatocellular Carcinoma (HCC)	Intense, non-rim hyperenhancement[27]	"Washout" appearance (hypointense)[27]	Markedly hypointense (no contrast uptake)	Classic pattern is arterial hyperenhancement followed by washout.
Regenerative Nodule	Isointense to liver	Isointense to liver	Isointense to hyperintense (contrast uptake) [1]	Uptake of contrast in the hepatobiliary phase indicates functional hepatocytes.
Focal Nodular Hyperplasia (FNH)	Intense, homogeneous hyperenhancement	Isointense or slightly hyperintense	Isointense to hyperintense (contrast uptake)	Retains contrast due to functional hepatocytes, unlike HCA/HCC.

Table 3: Quantitative Liver Stiffness Values for Fibrosis Staging

Fibrosis Stage (METAVIR)	Shear Wave Elastography (SWE) - Typical Cutoffs (kPa)	Magnetic Resonance Elastography (MRE) - Typical Cutoffs (kPa)	Interpretation
F0-F1 (None/Mild)	< 7.0	< 2.9 - 3.0[12][20]	Normal or mild fibrosis.
F2 (Significant)	7.0 - 9.5	3.0 - 3.5[12][20]	Significant fibrosis present.
F3 (Advanced)	9.5 - 13.0	3.5 - 4.0[12][20]	Advanced fibrosis.
F4 (Cirrhosis)	> 13.0[22]	> 4.0 - 5.0[12][20]	Cirrhosis is highly likely.

Note: Cutoff values can vary slightly based on disease etiology and the specific ultrasound/MRI system. The SWE values are generalized; the "rule of four" suggests >13 kPa is highly suggestive of compensated advanced chronic liver disease (cACLD).[22]

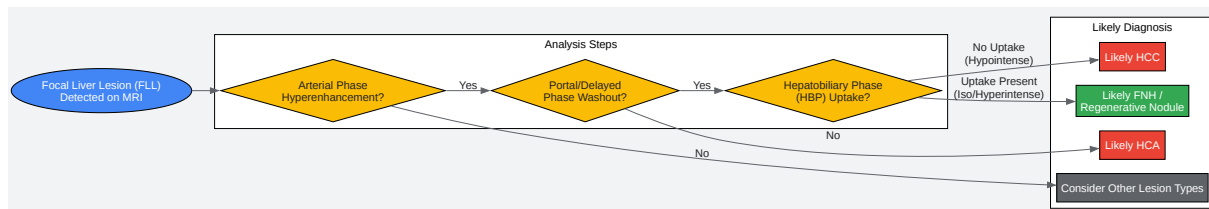
Section 5: Visualizations



[Click to download full resolution via product page](#)

Caption: Workflow for GSD-I Liver Imaging Surveillance.

Caption: Gd-EOB-DTPA Uptake and Excretion Pathway.



[Click to download full resolution via product page](#)

Caption: Troubleshooting Logic for Characterizing a Focal Liver Lesion.

Need Custom Synthesis?

BenchChem offers custom synthesis for rare earth carbides and specific isotopic labeling.

Email: info@benchchem.com or [Request Quote Online](#).

References

- 1. Pictorial Review of MRI Findings of Glycogen Storage Disease from Children to Young Adults - PMC [pmc.ncbi.nlm.nih.gov]
- 2. radiopaedia.org [radiopaedia.org]
- 3. radiopaedia.org [radiopaedia.org]
- 4. Glycogen Storage Disease Type I - StatPearls - NCBI Bookshelf [ncbi.nlm.nih.gov]
- 5. preprints.org [preprints.org]

- 6. Multiple hepatocellular adenomas in a patient with glycogen storage disease type I: various enhancement patterns in MRI with Gd-EOB-DTPA - PubMed [pubmed.ncbi.nlm.nih.gov]
- 7. wjgnet.com [wjgnet.com]
- 8. my.clevelandclinic.org [my.clevelandclinic.org]
- 9. Principles and clinical application of ultrasound elastography for diffuse liver disease - PMC [pmc.ncbi.nlm.nih.gov]
- 10. radiopaedia.org [radiopaedia.org]
- 11. Normative values for magnetic resonance elastography–based liver stiffness in a healthy population - PMC [pmc.ncbi.nlm.nih.gov]
- 12. resoundant.com [resoundant.com]
- 13. openmedscience.com [openmedscience.com]
- 14. youtube.com [youtube.com]
- 15. m.youtube.com [m.youtube.com]
- 16. researchgate.net [researchgate.net]
- 17. radiopaedia.org [radiopaedia.org]
- 18. mrimaster.com [mrimaster.com]
- 19. mindray.com [mindray.com]
- 20. Two-Dimensional Shear-Wave Elastography: Accuracy in Liver Fibrosis Staging Using Magnetic Resonance Elastography as the Reference Standard - PMC [pmc.ncbi.nlm.nih.gov]
- 21. google.com [google.com]
- 22. pubs.rsna.org [pubs.rsna.org]
- 23. abdominalradiology.org [abdominalradiology.org]
- 24. youtube.com [youtube.com]
- 25. Magnetic resonance imaging: Review of imaging techniques and overview of liver imaging - PMC [pmc.ncbi.nlm.nih.gov]
- 26. cds.ismrm.org [cds.ismrm.org]
- 27. The Radiology Assistant : LI-RADS [radiologyassistant.nl]
- To cite this document: BenchChem. [Technical Support Center: Enhancing Liver Imaging Resolution in GSD-I]. BenchChem, [2025]. [Online PDF]. Available at:

[<https://www.benchchem.com/product/b1192801#enhancing-the-resolution-of-liver-imaging-in-gsd-1>]

Disclaimer & Data Validity:

The information provided in this document is for Research Use Only (RUO) and is strictly not intended for diagnostic or therapeutic procedures. While BenchChem strives to provide accurate protocols, we make no warranties, express or implied, regarding the fitness of this product for every specific experimental setup.

Technical Support: The protocols provided are for reference purposes. Unsure if this reagent suits your experiment? [[Contact our Ph.D. Support Team for a compatibility check](#)]

Need Industrial/Bulk Grade? [Request Custom Synthesis Quote](#)

BenchChem

Our mission is to be the trusted global source of essential and advanced chemicals, empowering scientists and researchers to drive progress in science and industry.

Contact

Address: 3281 E Guasti Rd
Ontario, CA 91761, United States
Phone: (601) 213-4426
Email: info@benchchem.com