

Technical Support Center: EHIDA Imaging

Author: BenchChem Technical Support Team. **Date:** December 2025

Compound of Interest

Compound Name: Ehida

Cat. No.: B1195364

[Get Quote](#)

Welcome to the technical support center for Ethylenediaminediacetic acid (**EHIDA**) imaging, also known as hepatobiliary scintigraphy or HIDA scan. This guide is designed for researchers, scientists, and drug development professionals to troubleshoot common artifacts and pitfalls encountered during **EHIDA** imaging experiments.

Troubleshooting Guides

This section provides solutions to specific problems you might encounter during your **EHIDA** imaging studies.

Issue: Non-visualization of the gallbladder in a patient suspected of acute cholecystitis.

- Question: Why is the gallbladder not visible on the **EHIDA** scan, and how can we confirm if it's a true positive for acute cholecystitis?
- Answer: Non-visualization of the gallbladder is a key indicator of acute cholecystitis, suggesting a cystic duct obstruction.^{[1][2]} However, several factors can lead to a false-positive result. It's crucial to rule out these possibilities before concluding.
 - Patient Preparation: Ensure the patient has been fasting for an appropriate period, typically 4-6 hours.^[3] Prolonged fasting (>24 hours) can lead to a full, static gallbladder that doesn't uptake the tracer, mimicking an obstruction.^{[3][4]} Conversely, a recent meal (within 2-4 hours) can cause the gallbladder to contract, preventing it from filling with the tracer.^{[3][4]}

- Medical Conditions: Severe hepatocellular disease can impair the liver's ability to process the radiotracer, leading to poor visualization of the entire biliary system.[4] Acute pancreatitis and severe chronic cholecystitis can also cause transient non-visualization.[4]
- Medications: Recent use of narcotics, such as morphine, can cause the sphincter of Oddi to contract, increasing pressure in the common bile duct and preventing tracer from entering the gallbladder.[3][5]
- Troubleshooting Steps:
 - Verify the patient's fasting status and recent medication history.
 - If prolonged fasting is suspected, administration of sincalide (a cholecystokinin or CCK analog) can help empty the gallbladder before the scan.[4]
 - For suspected functional obstruction due to narcotics, delaying the scan is recommended.
 - In cases of suspected chronic cholecystitis, delayed imaging up to 4 hours can reduce false-positive results.[4] Intravenous morphine can be administered during the scan to increase biliary pressure and facilitate gallbladder filling if it's not the cause of the initial non-visualization.[1][6]

Issue: Delayed or slow transit of the radiotracer to the small intestine.

- Question: What does it mean if the radiotracer is slow to appear in the small intestine?
- Answer: Slow movement of the radioactive tracer through the biliary system might indicate a functional or mechanical obstruction in the common bile duct or a problem with liver function. [1][7] This could be due to a gallstone, a tumor, or sphincter of Oddi dysfunction.[5]

Issue: Radiotracer activity is detected outside the biliary system.

- Question: We are observing radiotracer in the peritoneal cavity. What is the likely cause?
- Answer: The presence of the radioactive tracer outside of the liver, gallbladder, bile ducts, and small intestine is indicative of a bile leak.[1][2][7] This can be a complication of recent

surgery, trauma, or liver biopsy.

Frequently Asked Questions (FAQs)

Q1: What are the most common causes of false-positive results in **EHIDA** scans for acute cholecystitis?

A1: The most common causes of false-positive results, where the gallbladder does not visualize despite the absence of acute cholecystitis, include:

- Prolonged fasting (>24 hours): This leads to a thick, bile-filled gallbladder that resists filling with the tracer.[3][4]
- Recent meal (within 2-4 hours): This stimulates gallbladder contraction, preventing tracer uptake.[3][4]
- Total Parenteral Nutrition (TPN): Can lead to bile stasis and gallbladder dysfunction.[4]
- Severe liver disease: Impaired hepatocyte function can result in insufficient tracer excretion.[4]
- Acute pancreatitis: Can cause transient gallbladder non-visualization.[4]
- Recent narcotic administration: Can cause functional obstruction at the sphincter of Oddi.[3]
- Severe chronic cholecystitis: The gallbladder may be functionally impaired and unable to take up the tracer.[4]

Q2: Can anatomical variations interfere with **EHIDA** scan interpretation?

A2: Yes, anatomical variations can be a pitfall. For instance, a duodenal diverticulum (an outpouching of the duodenum) can sometimes accumulate the radiotracer and be mistaken for the gallbladder.[8] Careful review of early and delayed images, along with anatomical correlation from other imaging modalities like ultrasound or CT, can help differentiate these.

Q3: How do elevated bilirubin levels affect the accuracy of an **EHIDA** scan?

A3: High levels of conjugated bilirubin can decrease the diagnostic accuracy of an **EHIDA** scan. Some radiotracers, like mebrofenin, may only allow for biliary visualization up to a certain bilirubin level. Grossly elevated bilirubin can impair the hepatic uptake and excretion of the tracer, potentially leading to a false-positive result, especially in the evaluation of conditions like biliary atresia in infants.[9]

Q4: What is the role of morphine and CCK (or sincalide) in **EHIDA** imaging?

A4:

- Morphine: It is used to augment the **EHIDA** scan when the gallbladder is not visualized initially. Morphine causes the sphincter of Oddi to contract, which increases pressure in the common bile duct. This pressure gradient can help force the radiotracer into the gallbladder if the cystic duct is patent, thus differentiating true cystic duct obstruction from functional non-filling.[1][6]
- CCK (or sincalide): This hormone is used to assess gallbladder function, specifically the gallbladder ejection fraction (GBEF). After the gallbladder has filled with the radiotracer, CCK is administered to stimulate gallbladder contraction. The GBEF is then calculated based on the amount of tracer expelled. A low GBEF may indicate chronic cholecystitis or functional gallbladder disease.[3][10] Sincalide can also be used prior to the scan in patients who have been fasting for a prolonged period to empty the gallbladder.[4]

Data Presentation

Table 1: Factors Influencing **EHIDA** Scan Accuracy and Potential for False Positives

Factor	Effect on EHIDA Scan	Troubleshooting/Consideration
Prolonged Fasting (>24h)	Non-visualization of gallbladder due to stasis.[3][4]	Administer sincalide before the scan to empty the gallbladder. [4]
Recent Meal (<4h)	Non-visualization of gallbladder due to contraction. [3][4]	Ensure proper patient fasting of at least 4-6 hours.[3]
Total Parenteral Nutrition (TPN)	Increased bile viscosity and decreased endogenous CCK. [4]	Consider sincalide administration.[4]
Alcoholism	Increased bile viscosity and abnormal hepatobiliary function.[4]	Interpret with caution; correlate with clinical findings.
Acute Pancreatitis	Transient non-visualization of the gallbladder.[4]	Delayed imaging may be necessary.[4]
Recent Narcotic Use	Functional obstruction at the Sphincter of Oddi.[3]	Withhold opiates for at least 6 hours before the exam.[3]
Severe Hepatocellular Disease	Decreased bile production and tracer uptake.[4]	The scan may not be diagnostic.
Severe Chronic Cholecystitis	Impaired gallbladder function leading to non-visualization.[4]	Delayed imaging up to 4 hours can be helpful.[4]
High Conjugated Bilirubin	Decreased diagnostic accuracy due to impaired tracer uptake.[9]	Consider the limitations of the scan in patients with severe jaundice.
Prematurity (in infants)	Underdeveloped liver function may reduce tracer uptake.[9]	Interpret with caution in premature infants.

Experimental Protocols

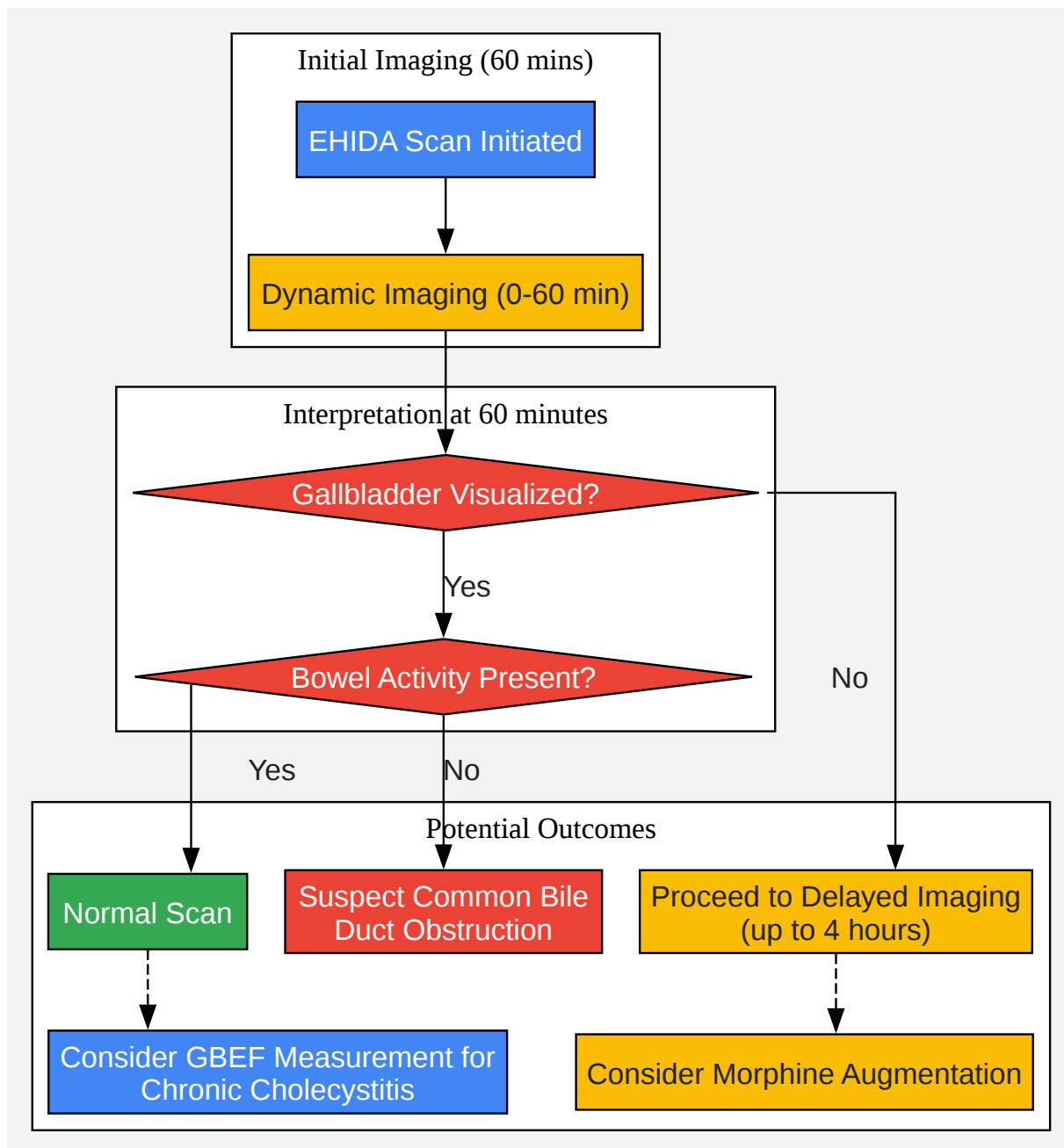
Standard EHIDA Scan Protocol for Gallbladder Evaluation

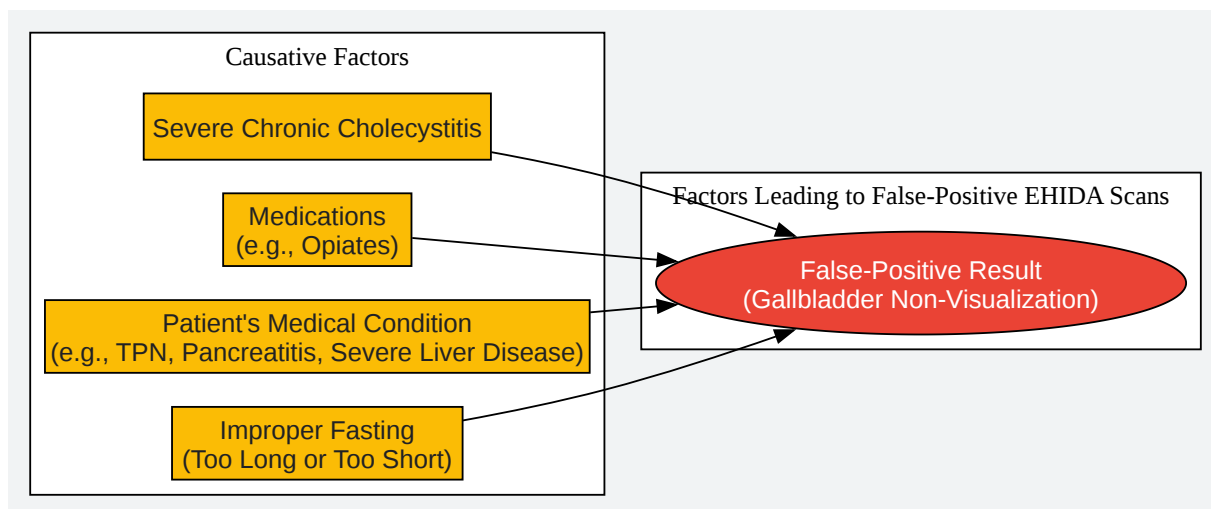
- Patient Preparation:
 - The patient should fast for a minimum of 4 hours but no longer than 24 hours before the scan.[\[1\]](#)[\[3\]](#)
 - Review the patient's medication history, particularly for any recent use of opiates.[\[3\]](#)
 - Inform the patient about the procedure, including the need to remain still during imaging.[\[7\]](#)
- Radiotracer Administration:
 - A radioactive tracer, typically a Technetium-99m (Tc-99m) labeled iminodiacetic acid derivative (e.g., mebrofenin or disofenin), is administered intravenously.[\[1\]](#)[\[7\]](#)
- Imaging:
 - The patient is positioned supine under a gamma camera.[\[1\]](#)
 - Dynamic imaging of the abdomen begins immediately after tracer injection and continues for approximately 60 minutes.[\[7\]](#)
 - Images are acquired to visualize the tracer's uptake by the liver, excretion into the biliary ducts, filling of the gallbladder, and passage into the small intestine.[\[7\]](#)
- Interventions (if necessary):
 - Delayed Imaging: If the gallbladder is not visualized within 60 minutes, delayed images may be acquired for up to 4 hours.[\[4\]](#)
 - Morphine Augmentation: If the gallbladder is still not seen and there is tracer in the small intestine, a small dose of morphine may be administered intravenously, with imaging continued for another 30-60 minutes.[\[1\]](#)
 - Gallbladder Ejection Fraction (GBEF) Measurement: If the indication is to assess gallbladder function, once the gallbladder is maximally filled with the tracer, a baseline image is taken. Sincalide is then infused intravenously over a period of time (e.g., 60

minutes) to stimulate gallbladder contraction.^[3] Dynamic images are acquired during and after the infusion to calculate the GBEF.

- Image Interpretation:
 - Normal: The tracer is seen in the liver, common bile duct, gallbladder, and small intestine within 60 minutes.^[1]
 - Acute Cholecystitis: The gallbladder is not visualized within 4 hours of tracer injection or 30 minutes after morphine administration.^{[1][6]}
 - Chronic Cholecystitis: This may be indicated by delayed gallbladder filling or a low GBEF (typically <35-38%).^{[1][3]}
 - Common Bile Duct Obstruction: The gallbladder may or may not be visualized, but there is no tracer activity in the small intestine.^[11]
 - Bile Leak: Radiotracer is identified outside the biliary system.^[1]

Visualizations





[Click to download full resolution via product page](#)

Need Custom Synthesis?

BenchChem offers custom synthesis for rare earth carbides and specific isotopic labeling.

Email: info@benchchem.com or [Request Quote Online](#).

References

- 1. HIDA scan - Mayo Clinic [[mayoclinic.org](https://www.mayoclinic.org)]
- 2. HIDA Scan: Preparation, Results, Side Effects, and Cost [[healthline.com](https://www.healthline.com)]
- 3. Hepatobiliary Scintigraphy - StatPearls - NCBI Bookshelf [[ncbi.nlm.nih.gov](https://www.ncbi.nlm.nih.gov)]
- 4. Roentgen Ray Reader: False Positives in HIDA [roentgenrayreader.blogspot.com]
- 5. HIDA Scan for Gallbladder: Purpose, Prep, Risks, and Results [[webmd.com](https://www.webmd.com)]
- 6. What to Know if You Need a HIDA Scan | Banner Health [[bannerhealth.com](https://www.bannerhealth.com)]
- 7. HIDA Scan: Results, Side Effects, (+ Procedure Preparation) [[hoag.org](https://www.hoag.org)]
- 8. Pitfalls in technetium-99m HIDA biliary imaging: duodenal diverticulum simulating the gallbladder - PubMed [pubmed.ncbi.nlm.nih.gov]

- 9. The Value of Hepatic Scintigraphy in the Diagnosis of Biliary Atresia - PMC [pmc.ncbi.nlm.nih.gov]
- 10. my.clevelandclinic.org [my.clevelandclinic.org]
- 11. m.youtube.com [m.youtube.com]
- To cite this document: BenchChem. [Technical Support Center: EHIDA Imaging]. BenchChem, [2025]. [Online PDF]. Available at: [https://www.benchchem.com/product/b1195364#artifacts-and-pitfalls-in-ehida-imaging]

Disclaimer & Data Validity:

The information provided in this document is for Research Use Only (RUO) and is strictly not intended for diagnostic or therapeutic procedures. While BenchChem strives to provide accurate protocols, we make no warranties, express or implied, regarding the fitness of this product for every specific experimental setup.

Technical Support: The protocols provided are for reference purposes. Unsure if this reagent suits your experiment? [[Contact our Ph.D. Support Team for a compatibility check](#)]

Need Industrial/Bulk Grade? [Request Custom Synthesis Quote](#)

BenchChem

Our mission is to be the trusted global source of essential and advanced chemicals, empowering scientists and researchers to drive progress in science and industry.

Contact

Address: 3281 E Guasti Rd
Ontario, CA 91761, United States
Phone: (601) 213-4426
Email: info@benchchem.com