

Technical Support Center: Deep Anterior Lamellar Keratoplasty (DALK) Graft Failure

Author: BenchChem Technical Support Team. **Date:** December 2025

Compound of Interest

Compound Name: dALK-3

Cat. No.: B15575147

[Get Quote](#)

This technical support center provides researchers, scientists, and drug development professionals with troubleshooting guides and frequently asked questions (FAQs) regarding graft failure in Deep Anterior Lamellar Keratoplasty (DALK).

Frequently Asked Questions (FAQs)

Q1: What are the primary causes of graft failure in DALK?

A1: Graft failure in DALK can be broadly categorized into immunological and non-immunological causes. The most common reasons include ocular surface diseases (such as limbal stem cell insufficiency, persistent epithelial defects, and keratolysis), recurrence of the primary corneal disease, and graft infection.^{[1][2]} While DALK is designed to minimize immunological rejection by preserving the host endothelium, stromal and epithelial rejection can still occur.^{[3][4]}

Q2: How does the risk of graft failure in DALK compare to Penetrating Keratoplasty (PK)?

A2: Meta-analyses have shown that while the rate of graft rejection is significantly lower in DALK compared to PK, the overall rate of graft failure is similar between the two procedures. This is often attributed to the unique non-immunological complications associated with the lamellar interface in DALK.

Q3: What are the early signs of DALK graft failure that I should monitor for in my experimental subjects?

A3: Early indicators of potential graft failure include persistent corneal edema that does not clear within the first few postoperative weeks, development of interface haze or opacity, signs of infection such as infiltrates or discharge, and persistent epithelial defects. Monitoring for signs of inflammation, such as conjunctival injection and anterior chamber reaction, is also crucial.

Q4: Can immunological rejection still occur in DALK even though the endothelium is preserved?

A4: Yes, while endothelial rejection is avoided, epithelial and stromal rejection can still occur in DALK.[3] These are immune responses directed against the donor epithelium and stromal keratocytes. Clinical signs can include a rejection line, stromal infiltrates, and graft edema.[3]

Q5: What is a "double anterior chamber" and is it a sign of graft failure?

A5: A double anterior chamber is a postoperative complication where aqueous humor leaks through a microperforation in Descemet's membrane, creating a fluid-filled space between the donor graft and the host's Descemet's membrane. While it is a serious complication, it does not automatically mean graft failure and can sometimes be managed with interventions like intracameral air or gas injection. However, if left unresolved, it can lead to graft opacification and failure.

Troubleshooting Guides

Issue 1: Persistent Corneal Edema Post-DALK

Potential Cause	Troubleshooting/Investigative Steps
Primary Graft Failure	- Evaluate donor tissue quality and preservation time. - Perform specular microscopy to assess endothelial cell density of the host. - Consider histopathological analysis of the explanted graft for signs of endothelial decompensation.
Surgical Trauma	- Review surgical records for any intraoperative complications, such as prolonged surgery time or excessive manipulation of the tissue.
Interface Fluid	- Use anterior segment optical coherence tomography (AS-OCT) to visualize the graft-host interface for any fluid accumulation. - If present, consider a venting incision or injection of a hypertonic solution to promote fluid resolution.
Elevated Intraocular Pressure (IOP)	- Monitor IOP closely. - If elevated, manage with appropriate anti-glaucoma medications.

Issue 2: Development of Interface Haze

Potential Cause	Troubleshooting/Investigative Steps
Fibroblast Proliferation	- Assess the degree of haze using slit-lamp biomicroscopy and AS-OCT. - In experimental models, consider topical corticosteroids to modulate the wound healing response. - For persistent, vision-impairing haze, mechanical scraping of the interface or phototherapeutic keratectomy (PTK) may be considered in a clinical setting.
Epithelial Ingrowth	- Look for a demarcated line or sheet of cells at the interface. - In-vivo confocal microscopy can confirm the presence of epithelial cells. - Management may involve lifting the graft and debriding the ingrowth.
Infection	- Perform a corneal scrape for microbiological culture and sensitivity if infection is suspected. - Initiate broad-spectrum topical antibiotics, and tailor treatment based on culture results.

Issue 3: Suspected Immunological Rejection

Potential Cause	Troubleshooting/Investigative Steps
Epithelial Rejection	- Look for a raised, linear epithelial rejection line. - Increase the frequency of topical corticosteroids.
Stromal Rejection	- Observe for subepithelial or stromal infiltrates (Krachmer spots) and localized graft edema. - In-vivo confocal microscopy can reveal inflammatory cell infiltration. - Intensify topical corticosteroid therapy. In severe cases, systemic immunosuppressants may be considered.

Quantitative Data Summary

Cause of Graft Failure	Incidence Rate in DALK (%)	Key Findings from Literature
Ocular Surface Diseases	37.8%	This is a leading cause of failure and includes limbal stem cell insufficiency, infectious keratitis, keratolysis, or persistent epithelial defect. [1][2]
Immunological Rejection	6-19.7%	The incidence of graft rejection in DALK is significantly lower than in PK.[4] Rejection episodes are a risk factor for subsequent graft failure.
Recurrence of Primary Disease	Varies by indication	For conditions like fungal keratitis, recurrence can be a significant cause of failure.
Graft Infection	Varies	Can occur at the graft-host interface and may require intensive medical therapy or surgical intervention.

Experimental Protocols

In-Vivo Confocal Microscopy for Diagnosis of Stromal Rejection

Objective: To identify and quantify inflammatory cell infiltration in the corneal stroma as an indicator of immunological rejection.

Methodology:

- **Anesthesia:** Instill one drop of topical proparacaine 0.5% into the eye.

- **Coupling Gel:** Apply a drop of sterile, high-viscosity gel to the tip of the confocal microscope objective.
- **Applanation:** Gently applanate the objective onto the central and peripheral cornea of the graft.
- **Image Acquisition:**
 - Perform a through-and-through scan of the entire corneal thickness to orient the layers.
 - Acquire high-magnification images (e.g., 400x) of the epithelial, sub-basal nerve plexus, anterior stroma, posterior stroma, and graft-host interface.
 - Focus on identifying hyper-reflective, dendritic-shaped cells (activated keratocytes and inflammatory cells) within the stroma.
- **Image Analysis:**
 - Quantify the density of inflammatory cells per square millimeter in each stromal layer.
 - Compare the cell density to that of a healthy, non-rejected DALK graft or the contralateral eye if available. A significant increase in inflammatory cell density is indicative of rejection.

Histopathological Analysis of a Failed DALK Graft

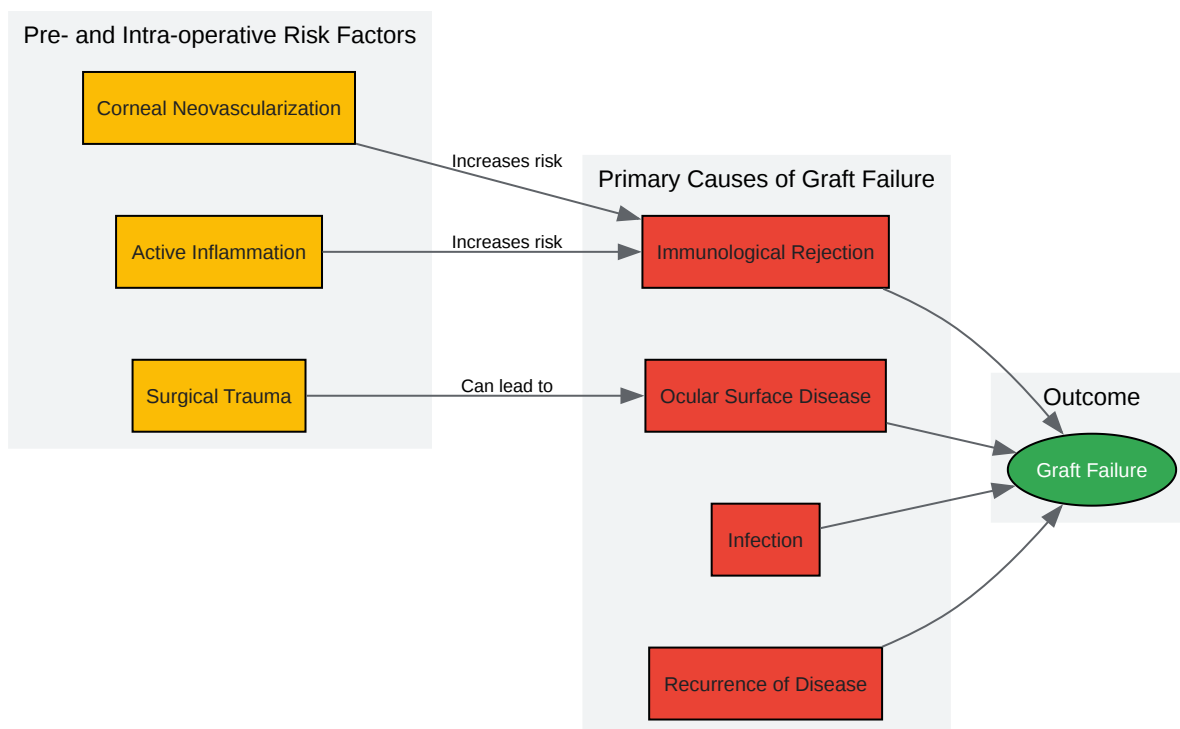
Objective: To determine the cellular and structural changes within a failed DALK graft to elucidate the cause of failure.

Methodology:

- **Specimen Fixation:** Immediately upon explantation, fix the corneal button in 10% neutral buffered formalin for at least 24 hours.
- **Gross Examination:** Document the size, shape, and any visible opacities or defects on the explanted graft.
- **Tissue Processing:**

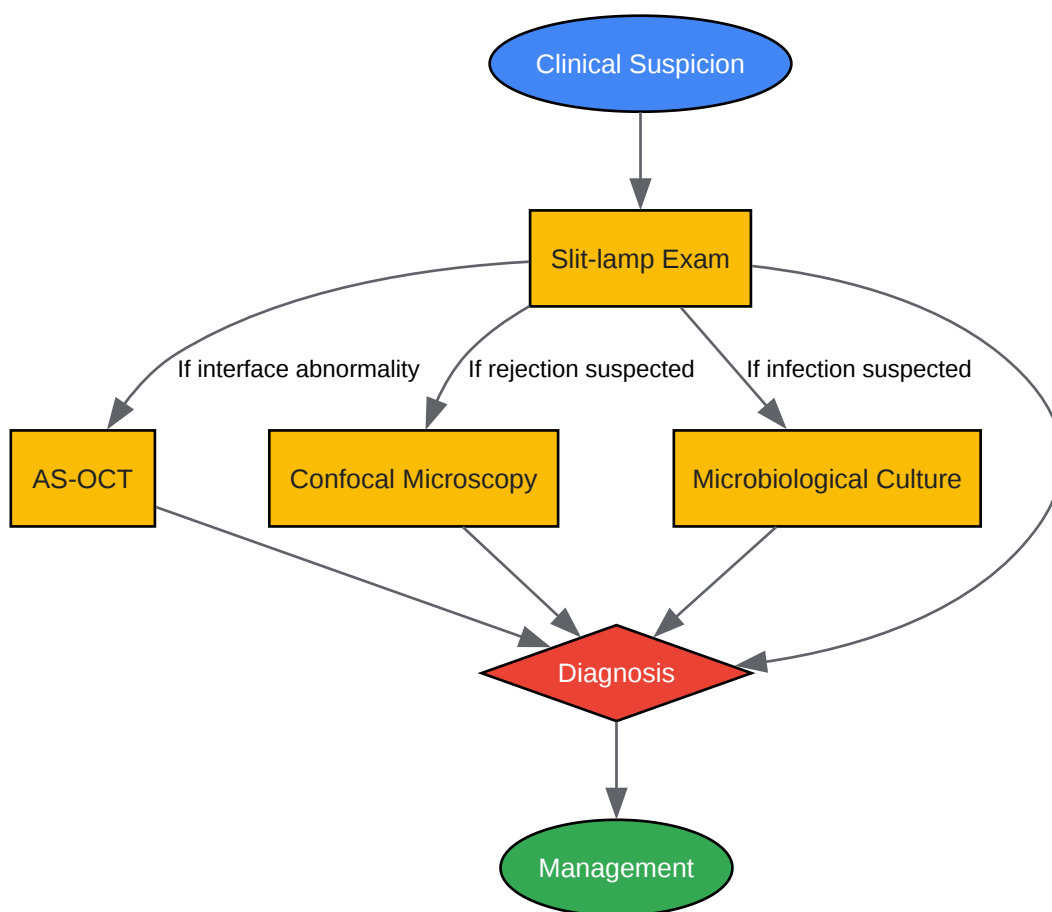
- Bisect the corneal button through the area of greatest interest.
- Process the tissue through a graded series of alcohols and xylene for dehydration and clearing.
- Embed the tissue in paraffin wax.
- Sectioning: Cut 4-5 μm thick sections using a microtome.
- Staining:
 - Hematoxylin and Eosin (H&E): For general morphology, visualization of cellular infiltrates, and assessment of stromal architecture.
 - Periodic Acid-Schiff (PAS): To highlight basement membranes, including Descemet's membrane, and to detect fungal elements.
 - Trichrome Stain (e.g., Masson's Trichrome): To assess for fibrosis and scarring at the graft-host interface.
- Microscopic Examination:
 - Examine the sections under a light microscope.
 - Assess for the presence and type of inflammatory cells (lymphocytes, plasma cells, neutrophils).
 - Evaluate the integrity of the epithelium and Bowman's layer.
 - Examine the stromal lamellae for disorganization, scarring, or vascularization.
 - Inspect the graft-host interface for any signs of separation, fibrosis, or cellular deposits.
 - Confirm the absence of host endothelium on the graft.

Visualizations



[Click to download full resolution via product page](#)

Caption: Risk factors leading to primary causes of DALK graft failure.



[Click to download full resolution via product page](#)

Caption: Diagnostic workflow for suspected DALK graft failure.

Need Custom Synthesis?

BenchChem offers custom synthesis for rare earth carbides and specific isotopic labeling.

Email: info@benchchem.com or [Request Quote Online](#).

References

- 1. Causes of corneal transplant failure: a multicentric study - PubMed [pubmed.ncbi.nlm.nih.gov]
- 2. researchgate.net [researchgate.net]
- 3. Corneal Graft Rejection - StatPearls - NCBI Bookshelf [ncbi.nlm.nih.gov]

- 4. emedicine.medscape.com [emedicine.medscape.com]
- To cite this document: BenchChem. [Technical Support Center: Deep Anterior Lamellar Keratoplasty (DALK) Graft Failure]. BenchChem, [2025]. [Online PDF]. Available at: [<https://www.benchchem.com/product/b15575147#causes-of-graft-failure-in-dalk>]

Disclaimer & Data Validity:

The information provided in this document is for Research Use Only (RUO) and is strictly not intended for diagnostic or therapeutic procedures. While BenchChem strives to provide accurate protocols, we make no warranties, express or implied, regarding the fitness of this product for every specific experimental setup.

Technical Support: The protocols provided are for reference purposes. Unsure if this reagent suits your experiment? [[Contact our Ph.D. Support Team for a compatibility check](#)]

Need Industrial/Bulk Grade? [Request Custom Synthesis Quote](#)

BenchChem

Our mission is to be the trusted global source of essential and advanced chemicals, empowering scientists and researchers to drive progress in science and industry.

Contact

Address: 3281 E Guasti Rd
Ontario, CA 91761, United States
Phone: (601) 213-4426
Email: info@benchchem.com