

Technical Support Center: Deep Anterior Lamellar Keratoplasty (DALK)

Author: BenchChem Technical Support Team. **Date:** December 2025

Compound of Interest

Compound Name: dALK-3

Cat. No.: B15575147

[Get Quote](#)

This technical support center provides troubleshooting guides and frequently asked questions (FAQs) for researchers, scientists, and drug development professionals encountering interface haze after Deep Anterior Lamellar Keratoplasty (DALK).

Frequently Asked Questions (FAQs)

Q1: What is interface haze after DALK?

Interface haze is a clouding or opacification at the surgical interface between the donor and recipient corneal tissue following a DALK procedure. This can range from a faint, visually insignificant haze to a dense opacity that severely limits vision.^[1] It can arise from various causes, including inflammation, scarring, retained surgical materials, or graft rejection.^{[2][3]}

Q2: What are the common causes of interface haze after DALK?

The primary causes of interface haze after DALK include:

- **Retained Viscoelastic:** Viscoelastic material used during surgery can be trapped at the interface, leading to a reticular pattern of haze.^{[2][4]}
- **Stromal Interface Irregularities:** An uneven or rough interface between the donor and host tissue can lead to opacity.^{[5][6]}
- **Graft Rejection:** Immune responses, including epithelial, subepithelial, and stromal rejection, can manifest as interface haze.^[3] The incidence of stromal rejection can be clinically

significant.[7]

- Persistent Epithelial Defects: A compromised epithelial layer on the graft can lead to underlying stromal opacities.[3]
- Inflammation: Postoperative inflammation, sometimes referred to as interface keratitis, can cause a diffuse haze.[8]
- Interface Neovascularization: The growth of new blood vessels at the graft-host interface can be a complication.[9]

Q3: Can interface haze be prevented?

Several intraoperative and postoperative strategies can help minimize the risk of interface haze:

- Meticulous Surgical Technique: Careful and complete removal of viscoelastic from the interface is crucial.[2][4] Creating a smooth stromal bed can also reduce the risk of irregularities.
- Prophylactic Medications:
 - Corticosteroids: Postoperative topical corticosteroids are used to control inflammation and prevent immune rejection.[3][7][10]
 - Mitomycin C (MMC): Intraoperative application of MMC, an anti-proliferative agent, has been shown to be effective in preventing haze, particularly after subsequent procedures like photorefractive keratectomy (PRK) over a DALK graft.[11][12][13][14]
- Ocular Surface Management: Pre-existing conditions like dry eye or blepharitis should be managed before surgery to reduce the risk of postoperative complications.[15]

Troubleshooting Guides

Issue 1: Visually significant haze is observed in the early postoperative period.

Possible Cause: Retained viscoelastic material at the graft-host interface.

Troubleshooting Steps:

- **Diagnosis:** The haze may appear in a fine, reticular pattern. Anterior segment imaging can help confirm the presence of retained material.[\[2\]](#)
- **Initial Management (Mild Haze):** For less extensive haze, observation may be sufficient, as it can clear over time.[\[2\]](#)[\[4\]](#)
- **Intervention (Extensive Haze):** If the haze is dense and visually significant, or if there is a visible separation between the donor and recipient cornea, surgical intervention is recommended.[\[2\]](#) This involves irrigating and aspirating the graft-host interface to remove the retained viscoelastic.[\[2\]](#)[\[4\]](#)

Issue 2: The patient develops acute stromal edema and/or neovascularization with associated haze.

Possible Cause: Stromal graft rejection.

Troubleshooting Steps:

- **Diagnosis:** The diagnosis is made based on the clinical signs of acute stromal edema or neovascularization in the absence of other confounding factors.[\[7\]](#)
- **Management:**
 - **Aggressive Topical Corticosteroids:** This is the primary treatment. A high-frequency regimen, such as prednisolone acetate 1% every one to three hours, is often initiated.[\[7\]](#)
 - **Systemic Corticosteroids:** In severe cases, or those that don't respond adequately to topical therapy, oral corticosteroids may be considered to control the inflammation.[\[8\]](#)
 - **Close Monitoring:** Patients require close follow-up to ensure resolution. Inadequate treatment can lead to a second rejection episode.[\[7\]](#)

Issue 3: Haze develops months after surgery, associated with stromal surface irregularities.

Possible Cause: Stromal scarring and interface irregularity.

Troubleshooting Steps:

- **Diagnosis:** Slit-lamp examination and corneal tomography are used to evaluate the regularity and transparency of the stromal interface.
- **Management:** The choice of intervention is tailored to the specific case to restore transparency while preserving the advantages of a lamellar graft.[\[5\]](#)[\[6\]](#)
 - **Phototherapeutic Keratectomy (PTK):** For superficial haze, PTK can be used to smooth the stromal bed. It is often combined with the application of Mitomycin C to prevent recurrence.[\[1\]](#)[\[16\]](#)
 - **Repeat Lamellar Keratoplasty:** In cases of significant interface opacity, a repeat DALK or an anterior lamellar graft exchange may be necessary.[\[6\]](#)
 - **Penetrating Keratoplasty (PKP):** This is typically reserved for cases where less invasive options are not suitable or have failed.[\[1\]](#)

Data Presentation

Table 1: Management Strategies for Post-DALK Interface Haze and Reported Outcomes

Management Strategy	Condition	Reported Outcome	Citation(s)
Observation	Mild Retained Viscoelastic Haze	Eventual clearing of haze and improved visual acuity (20/40 or better).	[2] [4]
Interface Irrigation & Aspiration	Extensive Retained Viscoelastic Haze	Quick resolution of haze.	[2] [4]
Aggressive Topical Corticosteroids (e.g., prednisolone acetate 1%)	Stromal Rejection	Complete resolution of all rejection episodes with treatment.	[7]
Repeat Keratoplasty (various techniques)	Stromal Interface Irregularity/Opacity	Best-corrected visual acuity improved from <20/200 to 20/40 or better.	[6]
Subconjunctival Bevacizumab	Interface Neovascularization	Improvement in hemorrhage and neovascularization.	[9]

Table 2: Example Protocols for Mitomycin C (MMC) Application in Preventing Haze

Procedure Context	MMC Concentration	Application Time	Key Finding	Citation(s)
PRK after DALK for Keratoconus	0.2 mg/mL (0.02%)	45 seconds	Safely and effectively corrects refractive errors post-DALK with minimal haze.	[11]
Prophylaxis for PRK in High Myopia	0.02%	2 minutes	Produced lower haze rates and better visual outcomes compared to no treatment.	[12]
PRK Haze Treatment	0.02%	1 minute	Used after scraping of haze to prevent recurrence.	[17]

Experimental Protocols

Methodology for Evaluating the Efficacy of Mitomycin C in Preventing Haze after PRK on a DALK Graft

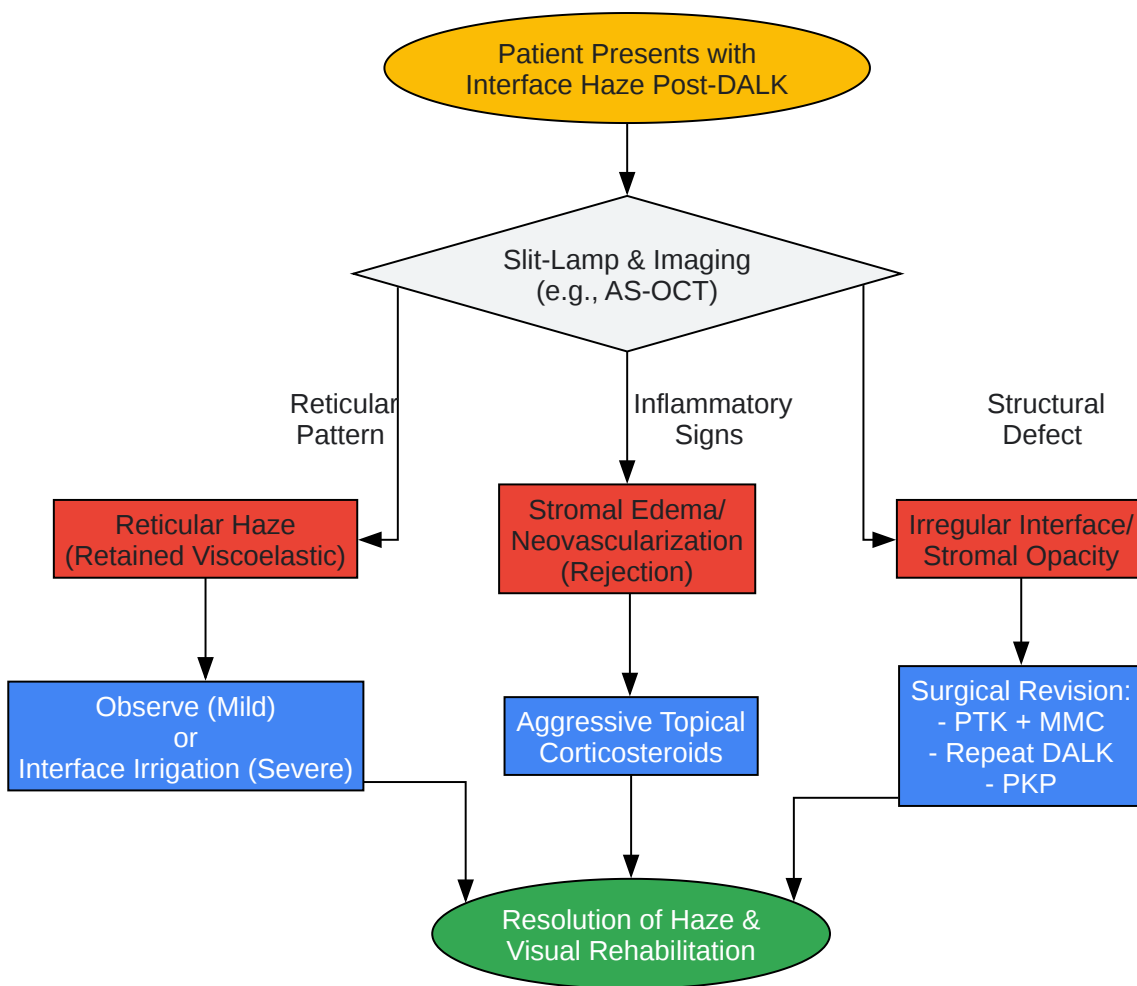
This protocol is a synthesized example based on methodologies described in the literature.[11] [12]

- Patient Selection:
 - Inclusion Criteria: Patients who have previously undergone DALK and subsequently require photorefractive keratectomy (PRK) for residual refractive error.
 - Exclusion Criteria: Pre-existing conditions that could confound haze assessment, such as herpetic keratitis or severe ocular surface disease.

- Preoperative Assessment:
 - Comprehensive ophthalmic examination including uncorrected and best-corrected visual acuity (BCVA), manifest refraction, slit-lamp biomicroscopy, and corneal tomography.
 - Endothelial cell density measurement.
- Surgical Procedure (PRK):
 - The corneal epithelium is removed.
 - Excimer laser ablation is performed based on the patient's refractive error. A planned undercorrection may be considered to account for the effects of MMC.[\[11\]](#)
- Intraoperative Application of Mitomycin C:
 - Immediately following laser ablation, a sterile micro sponge soaked in 0.02% (0.2 mg/mL) MMC solution is placed on the ablated stromal bed.
 - The sponge is left in place for a predetermined duration (e.g., 45 seconds).
 - The cornea is then thoroughly irrigated with a chilled balanced salt solution.
- Postoperative Care:
 - A bandage contact lens is placed.
 - A standard postoperative regimen of topical antibiotics and corticosteroids is prescribed. Corticosteroids are tapered over several weeks to months.
- Follow-up and Data Collection:
 - Patients are followed at regular intervals (e.g., 1 day, 1 week, 1, 3, 6, and 12 months).
 - At each visit, visual acuity, refraction, and slit-lamp examination are performed.
 - Corneal haze is graded using a standardized scale (e.g., Fantes scale, Grade 0 to 4).
 - Endothelial cell density is re-measured at the final follow-up.

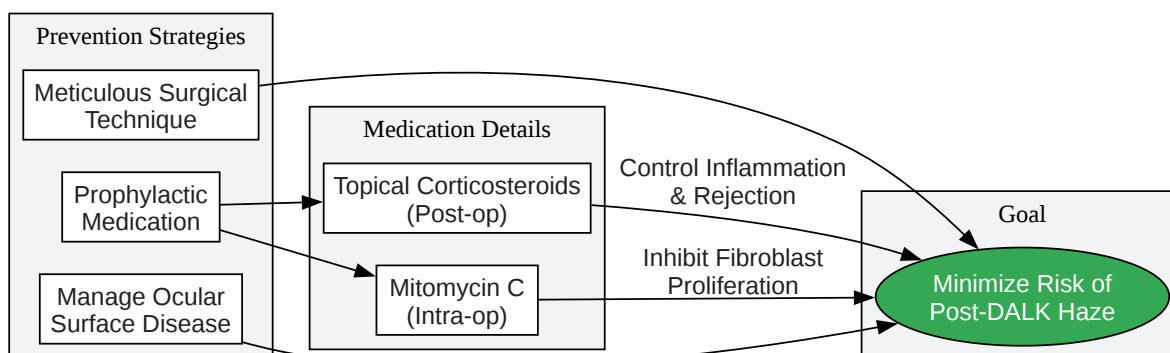
- Outcome Measures:
 - Primary: Incidence and grade of corneal haze at 6 and 12 months.
 - Secondary: Change in BCVA, refractive predictability (proportion of eyes within ± 0.50 D of target refraction), and change in endothelial cell density.

Visualizations



[Click to download full resolution via product page](#)

Caption: Troubleshooting workflow for post-DALK interface haze.



[Click to download full resolution via product page](#)

Caption: Logical relationships in preventing post-DALK haze.

Need Custom Synthesis?

BenchChem offers custom synthesis for rare earth carbides and specific isotopic labeling.

Email: info@benchchem.com or [Request Quote Online](#).

References

- 1. Clearing Up Corneal Haze | Corneal Physician [cornealphysician.com]
- 2. A cause of reticular interface haze and its management after descemet stripping endothelial keratoplasty - PubMed [pubmed.ncbi.nlm.nih.gov]
- 3. Approaches toward enhancing survival probability following deep anterior lamellar keratoplasty - PMC [pmc.ncbi.nlm.nih.gov]
- 4. researchgate.net [researchgate.net]
- 5. ophthalmology360.com [ophthalmology360.com]
- 6. researchgate.net [researchgate.net]
- 7. reviewofophthalmology.com [reviewofophthalmology.com]
- 8. urmc.rochester.edu [urmc.rochester.edu]

- 9. researchgate.net [researchgate.net]
- 10. vision-institute.com [vision-institute.com]
- 11. Photorefractive keratectomy with mitomycin C after deep anterior lamellar keratoplasty for keratoconus - PubMed [pubmed.ncbi.nlm.nih.gov]
- 12. Evaluation of the prophylactic use of mitomycin-C to inhibit haze formation after photorefractive keratectomy - PubMed [pubmed.ncbi.nlm.nih.gov]
- 13. Biological effects of mitomycin C on late corneal haze stromal fibrosis following PRK - PubMed [pubmed.ncbi.nlm.nih.gov]
- 14. Biological effects of Mitomycin C on late corneal haze stromal fibrosis following PRK - PMC [pmc.ncbi.nlm.nih.gov]
- 15. LASIK Interface Complications: Etiology, Management, & Outcomes - PMC [pmc.ncbi.nlm.nih.gov]
- 16. crstodayeurope.com [crstodayeurope.com]
- 17. Refractory interface haze developing after epithelial ingrowth following laser in situ keratomileusis and small aperture corneal inlay implantation - PMC [pmc.ncbi.nlm.nih.gov]
- To cite this document: BenchChem. [Technical Support Center: Deep Anterior Lamellar Keratoplasty (DALK)]. BenchChem, [2025]. [Online PDF]. Available at: [https://www.benchchem.com/product/b15575147#preventing-and-managing-interface-haze-after-dalk]

Disclaimer & Data Validity:

The information provided in this document is for Research Use Only (RUO) and is strictly not intended for diagnostic or therapeutic procedures. While BenchChem strives to provide accurate protocols, we make no warranties, express or implied, regarding the fitness of this product for every specific experimental setup.

Technical Support: The protocols provided are for reference purposes. Unsure if this reagent suits your experiment? [[Contact our Ph.D. Support Team for a compatibility check](#)]

Need Industrial/Bulk Grade? [Request Custom Synthesis Quote](#)

BenchChem

Our mission is to be the trusted global source of essential and advanced chemicals, empowering scientists and researchers to drive progress in science and industry.

Contact

Address: 3281 E Guasti Rd

Ontario, CA 91761, United States

Phone: (601) 213-4426

Email: info@benchchem.com