

Technical Support Center: Artifacts in CT Imaging of Basal Ganglia Calcification

Author: BenchChem Technical Support Team. **Date:** December 2025

Compound of Interest

Compound Name: *pFBC*

Cat. No.: *B15135574*

[Get Quote](#)

For Researchers, Scientists, and Drug Development Professionals

This technical support center provides troubleshooting guides and frequently asked questions (FAQs) to address common artifacts encountered during computed tomography (CT) imaging of basal ganglia calcification.

Frequently Asked Questions (FAQs)

Q1: What are the most common artifacts observed in CT imaging of basal ganglia calcification?

A1: The most prevalent artifacts are beam hardening artifacts, which manifest in two primary ways:

- **Streaking Artifacts:** Dark and bright streaks appearing between dense structures, such as calcifications or bone. In the context of basal ganglia calcification, these streaks can obscure the surrounding brain parenchyma.[\[1\]](#)[\[2\]](#)
- **Cupping Artifacts:** A false decrease in the CT number (Hounsfield Units) in the center of a uniform object, making it appear less dense. This can lead to an inaccurate assessment of the calcification's density.[\[1\]](#)[\[2\]](#)

Q2: What causes beam hardening artifacts in this context?

A2: CT scanners use a polychromatic X-ray beam, meaning it consists of photons with a range of energies. As the beam passes through dense material like a calcification, the lower-energy

photons are preferentially absorbed. This results in a "harder" beam with a higher average energy. The CT scanner's reconstruction algorithm assumes a monochromatic beam, leading to inaccuracies in the calculated attenuation and the manifestation of artifacts.[1][2][3]

Q3: Can these artifacts be mistaken for pathology?

A3: Yes, streaking artifacts, particularly in the posterior fossa near the dense petrous bones, can sometimes mimic or obscure underlying pathology such as hemorrhage or subtle ischemic changes.[2] It is crucial to recognize and mitigate these artifacts for an accurate diagnosis.

Q4: How can I differentiate between a small hemorrhage and a calcification, as both appear hyperdense on CT?

A4: Dual-energy CT (DECT) is a valuable tool for this purpose. By acquiring data at two different energy levels, DECT can differentiate materials based on their atomic number. Calcium and iron (in blood) have different energy-dependent attenuation profiles, allowing for their separation using material decomposition algorithms.[4][5] DECT can generate "virtual non-calcium" images, where the signal from calcium is suppressed, making it easier to identify hemorrhage.[4]

Troubleshooting Guides

Issue 1: Prominent streaking artifacts obscuring the tissue adjacent to the basal ganglia calcifications.

Potential Cause	Troubleshooting Step	Expected Outcome
Beam Hardening	Increase Tube Voltage (kVp): A higher kVp results in a more penetrating X-ray beam, which is less susceptible to beam hardening. [1]	Reduction in the severity of dark and bright streaks.
Utilize Dual-Energy CT (DECT): Acquire scans at two different energy levels. Reconstruct virtual monochromatic images at higher energy levels (e.g., 75 keV or higher for the posterior fossa) to reduce beam hardening artifacts. [6] [7]	Improved visualization of structures adjacent to calcifications with reduced streaking.	
Employ Iterative Reconstruction (IR) Algorithms: These advanced reconstruction methods can model the physics of the X-ray beam and noise statistics more accurately than traditional filtered back projection (FBP), leading to a reduction in artifacts. [1] [8]	Smoother image with fewer streaks and improved soft-tissue definition.	
Use Metal Artifact Reduction (MAR) Algorithms: Although designed for metallic implants, these algorithms can also be effective in reducing artifacts from dense calcifications. [1] [9]	Significant reduction in streaking artifacts, improving the diagnostic quality of the images.	

Issue 2: Inaccurate Hounsfield Unit (HU) measurements of the calcifications due to cupping artifacts.

Potential Cause	Troubleshooting Step	Expected Outcome
Beam Hardening	Apply Vendor-Specific Beam Hardening Correction: Modern CT scanners have built-in correction algorithms. Ensure these are enabled and properly calibrated. ^{[1][2]}	More uniform HU values across the calcification, providing a more accurate density measurement.
Utilize Iterative Reconstruction (IR): IR algorithms can help to correct for the non-linear effects of beam hardening, leading to more accurate HU values. ^[10]	Improved accuracy and consistency of HU measurements.	

Quantitative Data Summary

The following table summarizes the quantitative impact of various artifact reduction techniques. The values are indicative and can vary based on the scanner, patient anatomy, and the size and density of the calcifications.

Technique	Parameter	Quantitative Impact on Artifacts	Reference
Iterative Reconstruction (IR)	Strength Level	Can reduce image noise by 11-55% depending on the level used. A 24% dose reduction can be achieved with no loss of sharpness.	[8][10]
Dual-Energy CT (DECT)	Virtual Monochromatic Energy	Reconstruction at 75 keV can reduce beam hardening artifacts in the posterior fossa.	[6]
Metal Artifact Reduction (MAR)	Algorithm Type (e.g., SEMAR, Smart-MAR, iMAR, OMAR)	Can reduce the average absolute error in HU by 3.3% to 28.8%, depending on the algorithm and the implant/calcification characteristics.	[9][11]

Experimental Protocols

Protocol 1: Dual-Energy CT (DECT) for Artifact Reduction and Material Differentiation

- Patient Positioning: Position the patient's head in the gantry, ensuring it is as close to the isocenter as possible to minimize off-axis artifacts.
- Scan Acquisition:
 - Perform a scout/topogram image for planning.
 - Acquire a dual-energy scan of the head. Typical kVp settings are 80/140 kVp or 100/150 kVp, depending on the scanner manufacturer.

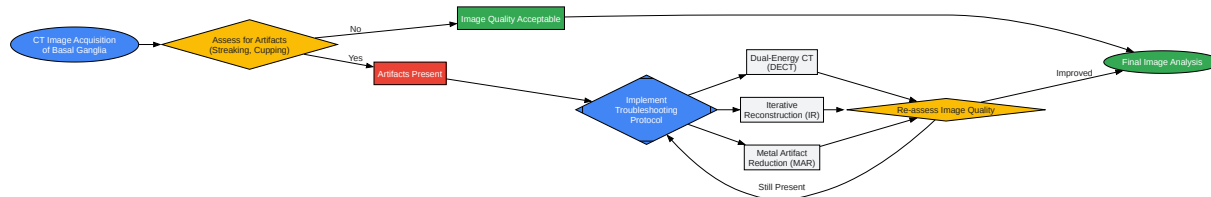
- Image Reconstruction:
 - Reconstruct standard weighted-average images (often at a simulated 120 kVp).
 - Generate virtual monochromatic images (VMI). For beam hardening reduction, reconstruct VMIs at higher energy levels (e.g., 75-120 keV).[7]
 - Generate material decomposition images, including virtual non-calcium (VNCa) and calcium overlay images, to differentiate between hemorrhage and calcification.[4]
- Image Analysis:
 - Review the high-keV VMIs for reduced streaking and cupping artifacts around the basal ganglia calcifications.
 - Analyze the VNCa images to confirm or exclude the presence of hemorrhage.

Protocol 2: Iterative Reconstruction (IR) for Artifact Reduction

- Patient Positioning and Scan Acquisition: Follow standard head CT protocols for patient positioning and acquisition parameters (e.g., kVp, mAs).
- Image Reconstruction:
 - Select an iterative reconstruction algorithm available on your scanner (e.g., SAFIRE, iDose, ASiR, VEO, ADMIRE).[12]
 - Choose an appropriate IR strength level. Higher levels generally provide more noise and artifact reduction but may result in an overly smooth or "plastic-like" image appearance. A moderate strength level is often a good starting point. For example, with SAFIRE, strength level 4 has been shown to be effective.[8]
 - Use a medium smooth convolution kernel (e.g., J30 for IR, equivalent to H30s for FBP). [10]
 - Reconstruct images at the desired slice thickness.

- Image Analysis:
 - Compare the IR images to standard FBP reconstructions to appreciate the reduction in noise and artifacts.
 - Assess the soft tissue detail around the calcifications, which should be improved in the IR images.

Visualizations



[Click to download full resolution via product page](#)

Caption: Workflow for identifying and troubleshooting artifacts in CT imaging.

Caption: The mechanism of beam hardening artifact formation.

Need Custom Synthesis?

BenchChem offers custom synthesis for rare earth carbides and specific isotopic labeling.

Email: info@benchchem.com or [Request Quote Online](#).

References

- 1. radiopaedia.org [radiopaedia.org]
- 2. radiologycafe.com [radiologycafe.com]
- 3. Hounsfield Unit - StatPearls - NCBI Bookshelf [ncbi.nlm.nih.gov]
- 4. researchgate.net [researchgate.net]
- 5. pubs.rsna.org [pubs.rsna.org]
- 6. radiopaedia.org [radiopaedia.org]
- 7. Dual energy CT: a step ahead in brain and spine imaging - PMC [pmc.ncbi.nlm.nih.gov]
- 8. radiologybusiness.com [radiologybusiness.com]
- 9. Comparison of quantitative measurements of four manufacturer's metal artifact reduction techniques for CT imaging with a self-made acrylic phantom - PubMed [pubmed.ncbi.nlm.nih.gov]
- 10. Iterative Reconstruction in Head CT: Image Quality of Routine and Low-Dose Protocols in Comparison with Standard Filtered Back-Projection - PMC [pmc.ncbi.nlm.nih.gov]
- 11. Quantitative comparison of commercial and non-commercial metal artifact reduction techniques in computed tomography - PubMed [pubmed.ncbi.nlm.nih.gov]
- 12. eurosafeimaging.org [eurosafeimaging.org]
- To cite this document: BenchChem. [Technical Support Center: Artifacts in CT Imaging of Basal Ganglia Calcification]. BenchChem, [2025]. [Online PDF]. Available at: [https://www.benchchem.com/product/b15135574#artifacts-in-ct-imaging-of-basal-ganglia-calcification]

Disclaimer & Data Validity:

The information provided in this document is for Research Use Only (RUO) and is strictly not intended for diagnostic or therapeutic procedures. While BenchChem strives to provide accurate protocols, we make no warranties, express or implied, regarding the fitness of this product for every specific experimental setup.

Technical Support: The protocols provided are for reference purposes. Unsure if this reagent suits your experiment? [[Contact our Ph.D. Support Team for a compatibility check](#)]

Need Industrial/Bulk Grade? [Request Custom Synthesis Quote](#)

BenchChem

Our mission is to be the trusted global source of essential and advanced chemicals, empowering scientists and researchers to drive progress in science and industry.

Contact

Address: 3281 E Guasti Rd

Ontario, CA 91761, United States

Phone: (601) 213-4426

Email: info@benchchem.com