

# Technical Support Center: Artifacts in 99mTc-PSMA-I&S SPECT Imaging

**Author:** BenchChem Technical Support Team. **Date:** December 2025

## Compound of Interest

Compound Name: PSMA I&S TFA

Cat. No.: B15623230

[Get Quote](#)

This technical support center provides troubleshooting guides and frequently asked questions (FAQs) to address common issues encountered during 99mTc-PSMA-I&S SPECT imaging experiments.

## Troubleshooting Guides

### Common Artifacts and Solutions

#### Issue: Patient Motion Artifacts

- Question: My SPECT images appear blurry or show misregistration between the SPECT and CT components. What could be the cause and how can I prevent this?
- Answer: Patient motion, including respiratory motion, is a common cause of image degradation in SPECT imaging.<sup>[1][2]</sup> This is particularly noticeable near the diaphragm.<sup>[1][3]</sup> To minimize motion artifacts, ensure the patient is comfortable and well-instructed before the scan.<sup>[2]</sup> Using motion correction algorithms available in most SPECT processing software can also help reduce the severity of these artifacts.<sup>[2]</sup> For respiratory motion, shallow breathing techniques can be recommended to the patient for better image fusion.<sup>[4]</sup>

#### Issue: "Halo" Artifact around Kidneys and Bladder

- Question: I am observing a photopenic area or "halo" around the kidneys and bladder, which have very high tracer uptake. Is this normal and can it be mitigated?

- Answer: Yes, this is a known phenomenon called a halo artifact.[3][5] 99mTc-PSMA-I&S is excreted through the urinary system, leading to intense activity in the kidneys and bladder.[6] This high activity can overwhelm the system's ability to correct for scatter and septal penetration, creating a "halo" that may obscure adjacent structures like lymph nodes.[3] While challenging to eliminate completely, ensuring adequate patient hydration and encouraging bladder voiding before imaging can help reduce urinary activity.

#### Issue: Unintended Focal Uptake (False Positives)

- Question: I am seeing focal uptake of 99mTc-PSMA-I&S in tissues other than the prostate or known metastatic sites. What are the possible causes?
- Answer: PSMA expression is not exclusive to prostate cancer cells.[1][5] Unintended uptake can be due to a variety of benign and malignant conditions, leading to potential false-positive findings. These can include:
  - Inflammatory and Benign Conditions: Prostatitis, benign prostatic hyperplasia, fractures, Paget's disease, and osteomyelitis can all show PSMA uptake.[1][3] Inflammatory uptake can also be seen post-surgery or radiation therapy.[3]
  - Other Tumors: Renal cell carcinoma, transitional cell carcinoma, and neuroendocrine tumors have been reported to show PSMA avidity.[4][5]
  - Physiological Uptake: Normal biodistribution of PSMA includes uptake in the lacrimal and salivary glands, liver, spleen, small intestine, and kidneys.[7] Sympathetic ganglia, such as celiac ganglia, can also show uptake and be mistaken for lymph node metastases.[4]

#### Issue: "Hot-Clot" Artifact in the Lungs

- Question: A focal point of high uptake is visible in the lung parenchyma on the SPECT images, but there is no corresponding lesion on the CT. What could this be?
- Answer: This may be a "hot-clot" artifact. It is thought to be caused by the agglutination of the radiopharmaceutical with erythrocytes during injection, forming microemboli that get trapped in the pulmonary capillaries.[4] This can mimic a lung metastasis. Careful injection technique, avoiding aspiration of blood into the syringe, can help prevent this.[4]

**Table: Summary of Potential Artifacts in PSMA Imaging**

Artifact Type	Description	Potential Cause(s)	Suggested Solution(s)
Motion Artifacts	Blurring or misregistration of images.[1][3]	Patient movement, respiratory motion.[1][2][3]	Ensure patient comfort, use motion correction software, instruct on shallow breathing.[2][4]
Halo Artifact	Photopenic area around organs with high tracer uptake (kidneys, bladder).[3][5]	High radioactivity concentration causing reconstruction issues.[3]	Adequate patient hydration, pre-imaging bladder voiding.
Attenuation Artifacts	Reduced counts in areas due to photon absorption by overlying tissue (e.g., soft tissue, metal implants).[2][8]	Photon attenuation by dense tissues.[2]	Use of CT-based attenuation correction is standard in SPECT/CT.[2]
"Hot-Clot" Artifact	Focal tracer uptake in the lungs without a corresponding anatomical lesion.[4]	Microemboli from radiopharmaceutical agglutination with blood cells during injection.[4]	Careful injection technique to avoid blood aspiration.[4]
Extravasation Artifact	High tracer activity at the injection site, potentially with lymphatic tracking.[8]	Infiltration of the radiopharmaceutical outside the vein.[8]	Careful intravenous injection technique, proper flushing of the line.[8]

## Experimental Protocol for <sup>99m</sup>Tc-PSMA-I&S SPECT/CT

This protocol is a synthesis of methodologies reported in the literature.[6][7][9][10]

- Radiopharmaceutical Preparation:

- Reconstitute a PSMA-I&S kit with freshly eluted 99mTc-pertechnetate (e.g., 1.48–2.96 GBq).[9]
- Heat the vial at 100°C for approximately 20 minutes.[9]
- Allow to cool before quality control and patient administration.
- Patient Preparation:
  - Ensure patients are well-hydrated.
  - To improve bowel visualization and reduce artifacts, an oral contrast agent may be administered starting 60 minutes prior to the scan.[6][7]
  - Have the patient void immediately before imaging to reduce bladder activity.
- Tracer Administration:
  - Administer a mean activity of approximately  $666 \pm 102$  MBq of 99mTc-PSMA-I&S intravenously.[6][7][10]
- Image Acquisition:
  - Imaging is typically performed 4-6 hours post-injection.[6][9] Some studies have performed imaging at multiple time points (e.g., 1, 3, 5, and 21 hours) to assess pharmacokinetics.[11]
  - Acquire whole-body SPECT images. A typical protocol might involve 96 projections over 360°, with a 10-second acquisition time per frame, into a 128x128 matrix.[7]
  - Follow the SPECT acquisition with a low-dose CT scan for attenuation correction and anatomical localization.[7]

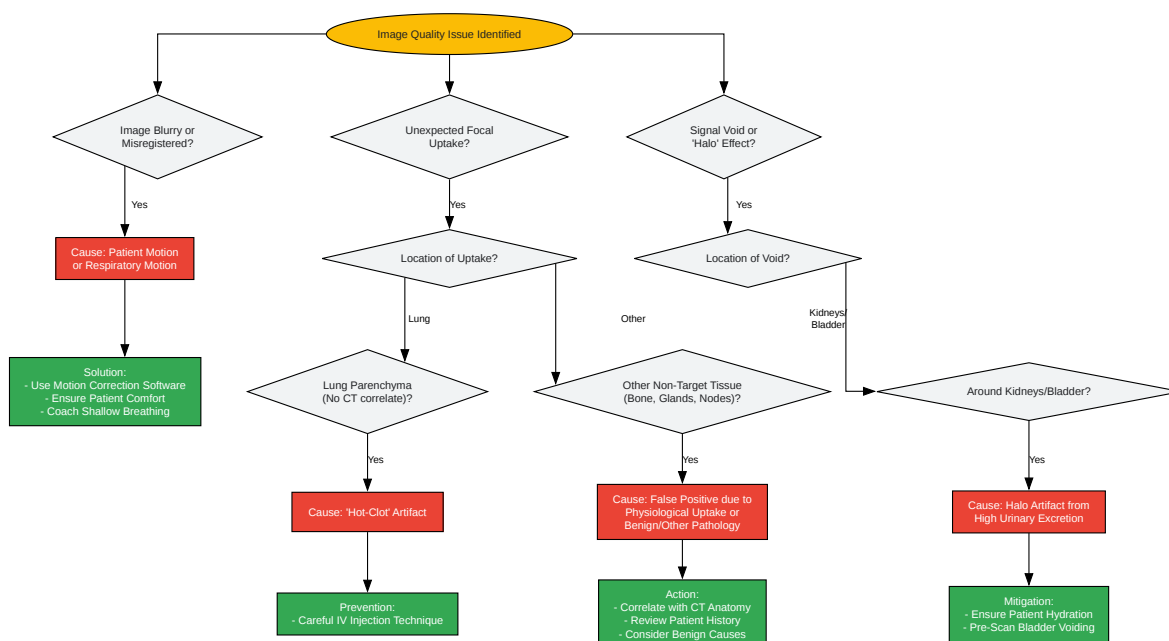
## Frequently Asked Questions (FAQs)

- Q1: Why is there physiological uptake of 99mTc-PSMA-I&S in the salivary and lacrimal glands?

- A1: PSMA is expressed in various normal tissues, including the salivary and lacrimal glands, which leads to physiological tracer uptake in these areas.[\[7\]](#) This is an expected finding and should not be mistaken for pathology.
- Q2: What is the typical tumor-to-background ratio for 99mTc-PSMA-I&S, and when is the optimal imaging time?
  - A2: 99mTc-PSMA-I&S demonstrates a relatively slow whole-body clearance, which contributes to efficient tracer uptake in tumor lesions over time.[\[11\]](#) This results in steadily increasing lesion-to-background ratios up to 21 hours post-injection.[\[11\]](#) Imaging at later time points, such as 4-6 hours, often provides excellent lesion contrast.[\[9\]](#)[\[11\]](#)
- Q3: How does the detection rate of 99mTc-PSMA-I&S SPECT/CT vary with PSA levels?
  - A3: The detection rate of 99mTc-PSMA-I&S SPECT/CT is dependent on PSA levels. For patients with biochemical recurrence, detection rates are lower at very low PSA levels (e.g., 20% for PSA < 1 ng/mL) and increase significantly at higher PSA levels (e.g., 82.9% for PSA > 4 ng/mL and 100% for PSA > 10 ng/mL).[\[12\]](#)
- Q4: Can 99mTc-PSMA-I&S SPECT/CT be used for primary staging of prostate cancer?
  - A4: Yes, studies have shown that 99mTc-PSMA-I&S SPECT/CT is useful for the primary staging of high-risk prostate cancer and for restaging in cases of advanced recurrence.[\[13\]](#) [\[14\]](#) It has demonstrated high sensitivity and specificity for detecting primary prostate cancer and metastatic lesions.[\[9\]](#)[\[10\]](#)
- Q5: Are there any adverse effects associated with 99mTc-PSMA-I&S injection?
  - A5: Based on available studies, no adverse effects have been observed in patients after the injection of 99mTc-PSMA-I&S.[\[6\]](#)[\[7\]](#)

## Visual Troubleshooting Workflow

### Graphviz Diagram: Troubleshooting Workflow for 99mTc-PSMA-I&S SPECT Artifacts



[Click to download full resolution via product page](#)

## Caption for the Diagram

A troubleshooting workflow for identifying and addressing common artifacts in 99mTc-PSMA-I&S SPECT imaging.

### Need Custom Synthesis?

BenchChem offers custom synthesis for rare earth carbides and specific isotopic labeling.

Email: [info@benchchem.com](mailto:info@benchchem.com) or [Request Quote Online](#).

## References

- 1. Normal Variants, Pitfalls, and Artifacts in Ga-68 Prostate Specific Membrane Antigen (PSMA) PET/CT Imaging - PMC [pmc.ncbi.nlm.nih.gov]
- 2. Recognizing and preventing artifacts with SPECT and PET imaging | Radiology Key [radiologykey.com]
- 3. Frontiers | Normal Variants, Pitfalls, and Artifacts in Ga-68 Prostate Specific Membrane Antigen (PSMA) PET/CT Imaging [frontiersin.org]
- 4. irjnm.tums.ac.ir [irjnm.tums.ac.ir]
- 5. researchgate.net [researchgate.net]
- 6. Diagnostic value of [99mTc]Tc-PSMA-I&S-SPECT/CT for the primary staging and restaging of prostate cancer - PMC [pmc.ncbi.nlm.nih.gov]
- 7. Mediso - Diagnostic value of [99mTc]Tc-PSMA-I&S-SPECT/CT for the primary staging and restaging of prostate cancer [mediso.com]
- 8. Nuclear Medicine Artifacts - StatPearls - NCBI Bookshelf [ncbi.nlm.nih.gov]
- 9. Frontiers | [99mTc]Tc-PSMA-I&S SPECT/CT quantitative parameters for risk stratification and metastasis prediction in primary prostate cancer: a retrospective study [frontiersin.org]
- 10. Diagnostic value of [99mTc]Tc-PSMA-I&S-SPECT/CT for the primary staging and restaging of prostate cancer - PubMed [pubmed.ncbi.nlm.nih.gov]
- 11. jnm.snmjournals.org [jnm.snmjournals.org]
- 12. researchgate.net [researchgate.net]
- 13. urotoday.com [urotoday.com]

- 14. [99cmTc]Tc-PSMA-I&S-SPECT/CT: experience in prostate cancer imaging in an outpatient center - PMC [pmc.ncbi.nlm.nih.gov]
- To cite this document: BenchChem. [Technical Support Center: Artifacts in 99mTc-PSMA-I&S SPECT Imaging]. BenchChem, [2025]. [Online PDF]. Available at: [https://www.benchchem.com/product/b15623230#artifacts-in-99mtc-psma-i-s-spect-imaging]

---

#### Disclaimer & Data Validity:

The information provided in this document is for Research Use Only (RUO) and is strictly not intended for diagnostic or therapeutic procedures. While BenchChem strives to provide accurate protocols, we make no warranties, express or implied, regarding the fitness of this product for every specific experimental setup.

**Technical Support:** The protocols provided are for reference purposes. Unsure if this reagent suits your experiment? [[Contact our Ph.D. Support Team for a compatibility check](#)]

**Need Industrial/Bulk Grade?** [Request Custom Synthesis Quote](#)

## BenchChem

Our mission is to be the trusted global source of essential and advanced chemicals, empowering scientists and researchers to drive progress in science and industry.

#### Contact

Address: 3281 E Guasti Rd  
Ontario, CA 91761, United States  
Phone: (601) 213-4426  
Email: [info@benchchem.com](mailto:info@benchchem.com)