

Technical Support Center: Addressing Patient-Related Artifacts in Tc-99m Imaging Studies

Author: BenchChem Technical Support Team. **Date:** December 2025

Compound of Interest

Compound Name: *Technetium Tc-99m*

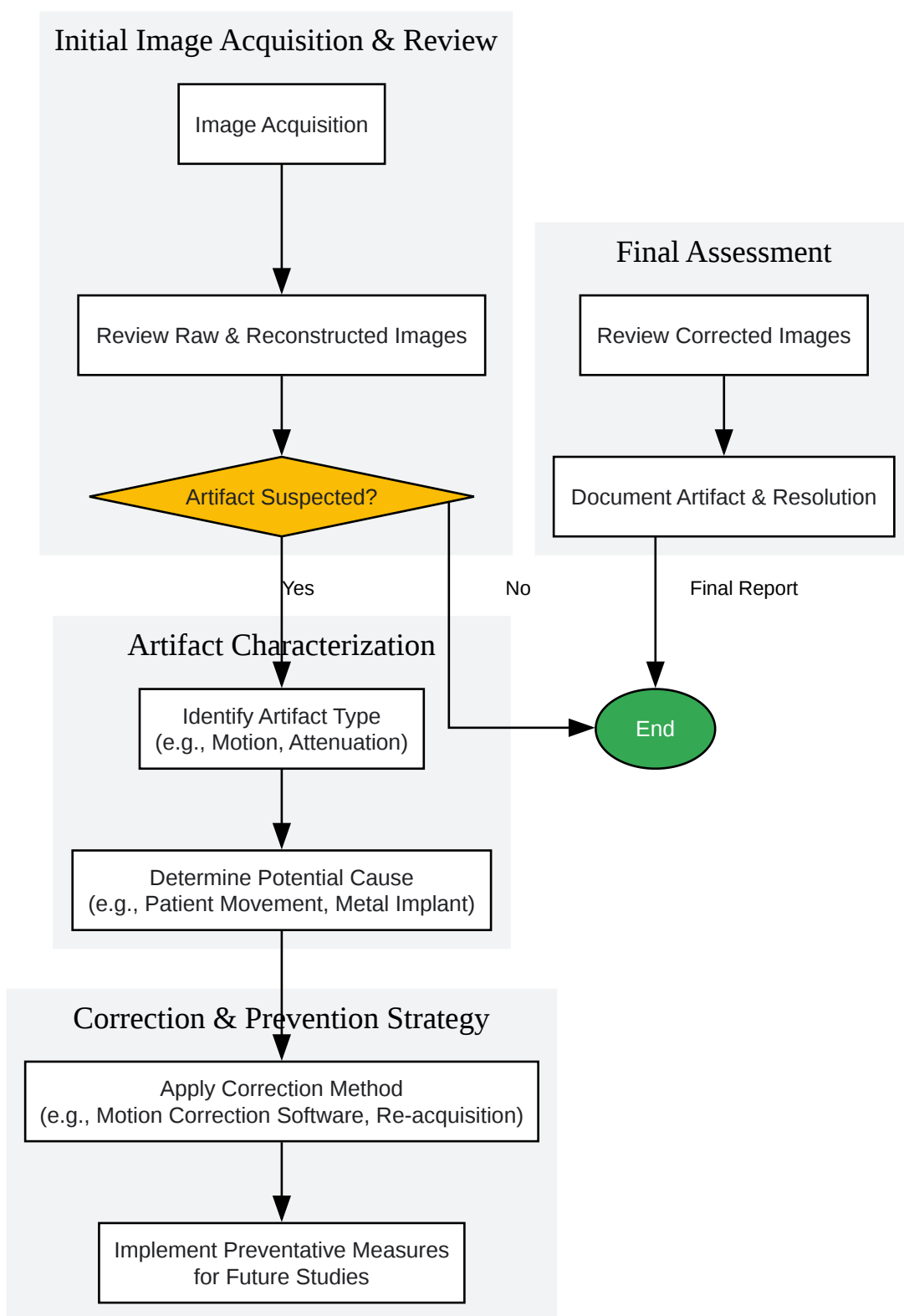
Cat. No.: *B10795670*

[Get Quote](#)

This technical support center provides troubleshooting guides and frequently asked questions (FAQs) to help researchers, scientists, and drug development professionals identify, understand, and mitigate patient-related artifacts in Technetium-99m (Tc-99m) imaging studies.

General Troubleshooting Workflow

The first step in addressing any potential image artifact is a systematic evaluation. The following workflow provides a general guideline for identifying and resolving patient-related artifacts.



[Click to download full resolution via product page](#)

Caption: General workflow for identifying and addressing artifacts.

FAQs and Troubleshooting Guides

Category 1: Motion Artifacts

Patient motion is a frequent cause of artifacts in SPECT studies, leading to image degradation and potentially inaccurate diagnoses.^{[1][2]}

Q1: What do motion artifacts look like in Tc-99m SPECT images?

A: Motion artifacts typically manifest as blurring or a "hurricane sign," where the heart or organ of interest appears distorted.^[3] This can lead to misalignments in reconstructed images, creating artificial defects that may be misinterpreted as pathology.^{[4][5]} For example, in myocardial perfusion imaging, patient motion can create artificial septal defects.^[4]

Q2: What are the primary causes of patient motion during a scan?

A: Motion can be voluntary or involuntary.^[6]

- Voluntary motion: This includes the patient changing position, often due to discomfort during long acquisition times.^{[1][6][7]}
- Involuntary motion: This includes physiological movements like breathing, cardiac contractions, or bowel movements.^{[1][6]} "Upward creep" of the heart is a specific motion artifact that can occur during stress-redistribution SPECT.^[3]

Q3: How can I identify if patient motion has occurred?

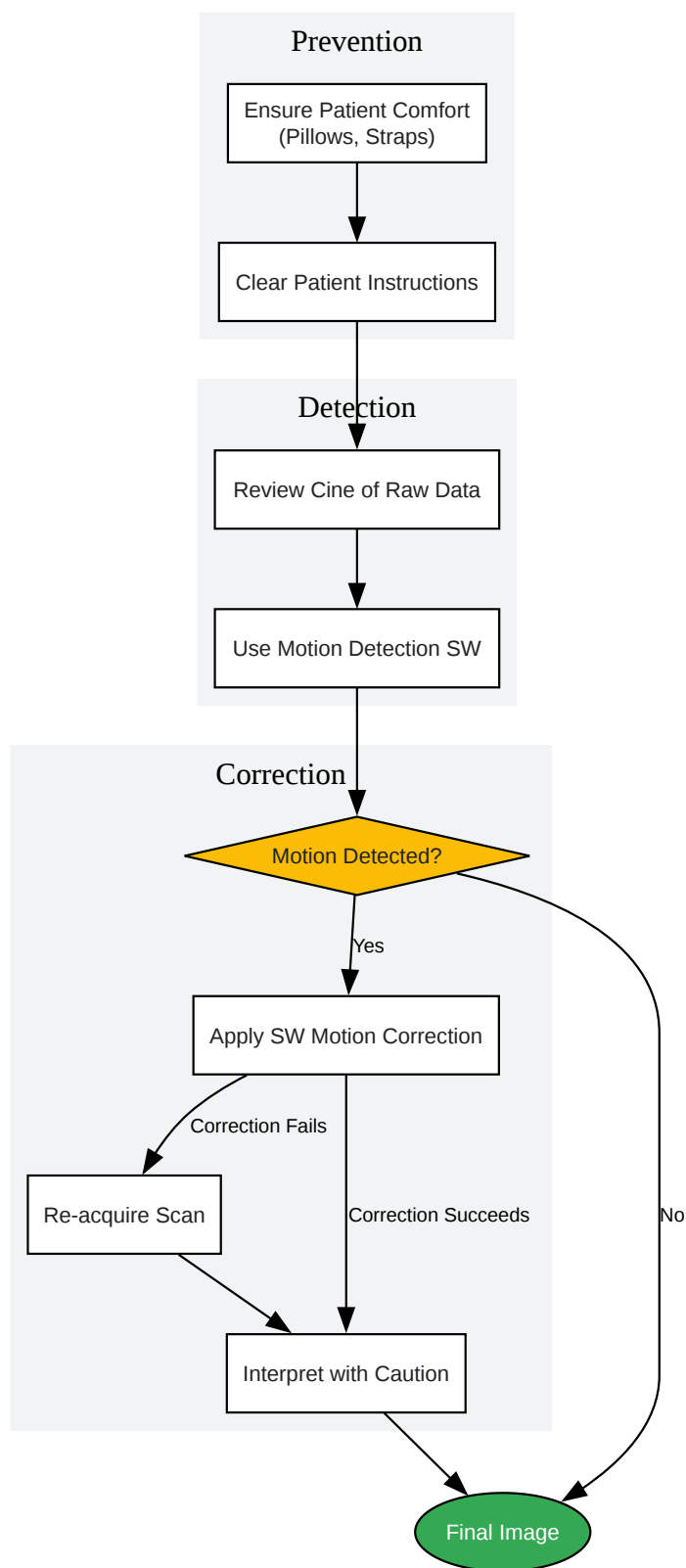
A: A key step is to review the raw projection images in a cinematic display.^[1] Look for abrupt shifts in the position of the organ of interest between frames.^[4] Some systems also provide co-registration images or motion graphs that can help detect displacement.^[4]

Q4: What are the recommended protocols for preventing and correcting motion artifacts?

A: Prevention is the most effective strategy.^[3] However, when motion occurs, several correction methods are available.

Experimental Protocol: Motion Artifact Mitigation

- Patient Preparation and Comfort:
 - Thoroughly explain the procedure to the patient to improve cooperation.[\[1\]](#)
 - Ensure the patient is in a comfortable and stable position. Use arm-holding devices, cushions, or belts to minimize the potential for movement.[\[3\]](#)[\[8\]](#)[\[9\]](#)
 - Keep scan times as short as reasonably achievable.[\[6\]](#)[\[7\]](#)
- Motion Detection:
 - Visually inspect the raw data (cine review) for any signs of patient motion before the patient leaves the imaging lab.[\[4\]](#)
 - Utilize any available motion detection software or tools provided by the imaging system.
- Correction Strategies:
 - Software-Based Correction: Many modern systems have software algorithms that can correct for motion by re-aligning the projection frames.[\[2\]](#)[\[4\]](#)
 - Re-acquisition: If significant motion is detected before the patient has left, and the radiopharmaceutical's half-life allows, the best solution is often to re-acquire the images after ensuring the patient is stable.[\[4\]](#) This is feasible with Tc-99m based agents due to their relatively long half-life of about six hours.[\[4\]](#)



[Click to download full resolution via product page](#)

Caption: Workflow for managing motion artifacts.

Category 2: Attenuation Artifacts

Photon attenuation by the patient's own tissues is one of the most common sources of artifacts in SPECT imaging.^[1] It can cause non-uniformities in the image that may mimic or obscure true perfusion defects or lesions.

Q5: What causes attenuation artifacts?

A: Attenuation occurs when photons emitted from the Tc-99m are absorbed or scattered by overlying tissue before they reach the gamma camera. This reduces the number of counts detected from certain regions.^[1] Common causes include:

- Soft Tissue: Particularly in obese patients or women with large breasts.^{[1][5]}
- Diaphragm: The left hemidiaphragm can cause decreased counts in the inferior wall of the heart, especially in obese male patients.^[1]
- External/Internal Objects: Non-anatomical structures like belt buckles, pacemakers, breast implants, or orthopedic devices can cause significant attenuation.^{[5][10]}

Q6: How can I differentiate an attenuation artifact from a true pathological finding?

A: Reviewing the raw rotating planar images is crucial to identify potential sources of attenuation.^[1] Attenuation artifacts often do not conform to a specific coronary artery distribution in cardiac studies.^[1] When available, comparing non-attenuation corrected (NAC) and attenuation-corrected (AC) images can help identify artifacts introduced by the correction process itself.^[8] For diaphragmatic attenuation, imaging the patient in the prone position in addition to the supine position can show if the "defect" resolves or changes, which is indicative of an artifact.^[1]

Q7: What is the protocol for minimizing soft-tissue attenuation artifacts?

A: Several techniques can be employed to reduce the impact of soft-tissue attenuation.

Experimental Protocol: Reducing Soft-Tissue Attenuation

- Patient Positioning:

- For suspected diaphragmatic attenuation in myocardial perfusion studies, acquire images in both supine and prone positions. Complete resolution or significant improvement of an inferior wall defect on prone imaging suggests an attenuation artifact.[1]
- For large or pendulous breasts, carefully position the breast away from the area being imaged, if possible.[7]
- Use of Attenuation Correction (AC):
 - If available, use SPECT/CT systems to generate an attenuation map from the CT data. This map is then used to correct the emission data.[8]
 - Always review both the non-corrected and attenuation-corrected images. Artifacts can sometimes be introduced by the AC process, especially in the presence of motion or misregistration between the SPECT and CT scans.[8]
- Radiotracer Choice:
 - Tc-99m labeled tracers are generally preferred over Thallium-201 as they are less susceptible to attenuation artifacts due to the higher energy of their photons (140 keV).[1][11]

Q8: How do metal implants affect Tc-99m imaging?

A: Metal implants, such as dental fillings or hip prostheses, cause severe streaking artifacts on CT images used for attenuation correction.[9][12] This can lead to an overestimation of activity in the corrected SPECT images, potentially creating false-positive findings.[9] Specialized metal artifact reduction (MAR) software can significantly improve the accuracy of attenuation correction around metal implants.[12] In a phantom study, MAR software reduced quantification errors from a range of -41.1% to +20.0% down to a range of -22.8% to +14.2%.[12]

Artifact Source	Appearance on SPECT Image	Recommended Action
Breast Tissue	Decreased counts in anterior/anterolateral walls[5][11]	Prone imaging, breast positioning, attenuation correction[1][7]
Diaphragm	Decreased counts in inferior/inferolateral walls[1][5]	Prone imaging, review of raw images, attenuation correction[1]
Metal Implants	Streaks or areas of falsely increased/decreased uptake (on AC images)[9][12]	Use Metal Artifact Reduction (MAR) software, review NAC images[8][12]
External Objects	Photopenic (cold) defects corresponding to object location[10]	Remove all external metal/dense objects before scanning[10]

Category 3: Injection- and Radiopharmaceutical-Related Artifacts

The quality of the radiopharmaceutical injection is critical for obtaining high-quality images.[13] Improper techniques can introduce artifacts that mimic or obscure pathology.[13]

Q9: What is radiopharmaceutical extravasation and how does it affect the images?

A: Extravasation, or infiltration, is the leakage of the radiopharmaceutical into the subcutaneous tissue at the injection site instead of entering the venous system.[10][13] This is a common occurrence, reported in up to 15-17.5% of injections.[13][14]

- Appearance: It typically appears as a "hot spot" of intense activity at the injection site.[13]
- Consequences: It can lead to altered biodistribution, such as uptake in local lymph nodes, which may be misinterpreted as a positive finding.[10][11][15] It also reduces the amount of tracer reaching the target organ, which can degrade image quality or lead to quantification errors.[13]

Caption: Causes and consequences of radiopharmaceutical extravasation.

Q10: How can I prevent and manage extravasation?

A: Careful injection technique is paramount. Using proper IV access and flushing techniques can help mitigate this issue.[13] If extravasation is suspected, it is often a good practice to image the injection site to confirm.[16] Acquiring additional views, such as a lateral image, can help differentiate soft-tissue uptake from uptake in underlying bone.[10][13]

Q11: What is a contamination artifact?

A: Contamination artifacts are among the most common in nuclear medicine and occur when the radiotracer is found in unexpected places, such as on the patient's skin or clothing.[10] A frequent cause is urine contamination, which can obscure anatomy in the pelvic region.[5][10]

Q12: How do I handle suspected urine contamination?

A:

- Confirm the source: Ask the patient about potential incontinence.
- Decontaminate: Have the patient remove the contaminated clothing and wash the affected skin area.[10]
- Re-image: Repeat the acquisition of the affected area. Acquiring a lateral view can often make the external nature of the contamination more apparent.[10]
- Prevention: To minimize bladder activity that can obscure pelvic structures, ensure the patient voids immediately before the scan.[17]

This guide provides a starting point for troubleshooting common patient-related artifacts. A thorough understanding of these potential pitfalls is essential for ensuring the diagnostic accuracy of Tc-99m imaging studies.[10][18]

Need Custom Synthesis?

BenchChem offers custom synthesis for rare earth carbides and specific isotopic labeling.

Email: info@benchchem.com or [Request Quote Online](#).

References

- 1. Recognizing and preventing artifacts with SPECT and PET imaging | Radiology Key [radiologykey.com]
- 2. [ceur-ws.org](#) [ceur-ws.org]
- 3. Quantitative Assessment of Motion Artifacts and Validation of a New Motion-Correction Program for Myocardial Perfusion SPECT | Journal of Nuclear Medicine [jnm.snmjournals.org]
- 4. [youtube.com](#) [youtube.com]
- 5. [radiologycafe.com](#) [radiologycafe.com]
- 6. [med.emory.edu](#) [med.emory.edu]
- 7. [medapparatus.com](#) [medapparatus.com]
- 8. Morphology supporting function: attenuation correction for SPECT/CT, PET/CT, and PET/MR imaging - PMC [pmc.ncbi.nlm.nih.gov]
- 9. Multi-modality nuclear medicine imaging: artefacts, pitfalls and recommendations - PMC [pmc.ncbi.nlm.nih.gov]
- 10. Nuclear Medicine Artifacts - StatPearls - NCBI Bookshelf [ncbi.nlm.nih.gov]
- 11. Artifacts and Pitfalls in Myocardial Perfusion Imaging | Journal of Nuclear Medicine Technology [tech.snmjournals.org]
- 12. [researchgate.net](#) [researchgate.net]
- 13. [researchgate.net](#) [researchgate.net]
- 14. Detection of Excess Presence of ^{99m}Tc-MDP Near Injection Site—A Case Report - PMC [pmc.ncbi.nlm.nih.gov]
- 15. Consequences of radiopharmaceutical extravasation and therapeutic interventions: a systematic review - PMC [pmc.ncbi.nlm.nih.gov]
- 16. Artifacts in Nuclear Medicine with Identifying and resolving artifacts. | PDF [slideshare.net]
- 17. [scholarscompass.vcu.edu](#) [scholarscompass.vcu.edu]
- 18. Patient-related pitfalls and artifacts in nuclear medicine imaging - PubMed [pubmed.ncbi.nlm.nih.gov]
- To cite this document: BenchChem. [Technical Support Center: Addressing Patient-Related Artifacts in Tc-99m Imaging Studies]. BenchChem, [2025]. [Online PDF]. Available at:

[<https://www.benchchem.com/product/b10795670#addressing-patient-related-artifacts-in-tc-99m-imaging-studies>]

Disclaimer & Data Validity:

The information provided in this document is for Research Use Only (RUO) and is strictly not intended for diagnostic or therapeutic procedures. While BenchChem strives to provide accurate protocols, we make no warranties, express or implied, regarding the fitness of this product for every specific experimental setup.

Technical Support: The protocols provided are for reference purposes. Unsure if this reagent suits your experiment? [[Contact our Ph.D. Support Team for a compatibility check](#)]

Need Industrial/Bulk Grade? [Request Custom Synthesis Quote](#)

BenchChem

Our mission is to be the trusted global source of essential and advanced chemicals, empowering scientists and researchers to drive progress in science and industry.

Contact

Address: 3281 E Guasti Rd
Ontario, CA 91761, United States
Phone: (601) 213-4426
Email: info@benchchem.com