

Technical Support Center: ^{99m}Tc-Sestamibi Imaging of Small Lesions

Author: BenchChem Technical Support Team. **Date:** December 2025

Compound of Interest

Compound Name: ^{99m}Tc-Sestamibi

Cat. No.: B1243785

[Get Quote](#)

This technical support center provides troubleshooting guidance and answers to frequently asked questions for researchers, scientists, and drug development professionals working with **^{99m}Tc-Sestamibi** imaging, particularly for the challenging application of detecting small lesions.

Troubleshooting Guide

This guide addresses common issues encountered during **^{99m}Tc-Sestamibi** imaging experiments.

Problem	Potential Cause	Recommended Solution
Poor Image Quality: Low Contrast / High Noise	1. Suboptimal radiochemical purity of 99mTc-Sestamibi.	1. Perform rigorous quality control on the radiopharmaceutical. The radiochemical purity should be $\geq 90\%$. [1] Use validated methods like thin-layer chromatography (TLC) or a Sep-Pak cartridge system.
2. Incorrect patient/subject preparation.	2. Ensure the subject has fasted for 4-6 hours prior to injection to minimize hepatobiliary uptake that can interfere with imaging. [2] Consider peripheral warming to increase blood flow and tracer uptake.	
3. Inappropriate imaging parameters (e.g., collimator, acquisition time).	3. For small lesions, a high-resolution or ultra-high-resolution collimator is recommended to improve spatial resolution, even at the cost of lower sensitivity. [3] [4] Increase acquisition time to compensate for lower counts.	
4. Patient or subject motion during the scan.	4. Use appropriate restraints and ensure the subject is comfortable to minimize movement. Motion correction software can be used, but severe motion may require re-acquisition. [5]	
False-Negative Results: Lesion Not Visualized	1. Small lesion size (<1 cm).	1. Optimize the imaging protocol for small lesion detection by using a high-

resolution collimator and SPECT/CT for better localization.[\[6\]](#) Consider delayed imaging (2-4 hours post-injection) as the tracer may wash out more slowly from abnormal tissue compared to surrounding healthy tissue.[\[7\]](#)[\[8\]](#)[\[9\]](#)

2. Low mitochondrial content in the lesion.	2. ^{99m} Tc-Sestamibi uptake is dependent on mitochondrial density. [7] [10] [11] If a lesion is known to have low mitochondrial content, this imaging agent may not be suitable.
---	--

3. P-glycoprotein (P-gp) expression in the lesion.	3. P-gp is a drug efflux pump that can remove ^{99m} Tc-Sestamibi from cells, leading to reduced accumulation. [9] [10] Consider alternative imaging agents if high P-gp expression is suspected.
--	---

4. Co-existing conditions (e.g., thyroid disease in parathyroid imaging).	4. For parathyroid imaging, co-existing thyroid nodules or thyroiditis can lead to false-negative results. [11] A subtraction technique with ^{99m} Tc-pertechnetate or ¹²³ I can help differentiate parathyroid from thyroid tissue. [12]
---	--

High Background Activity	1. Significant hepatobiliary or gastrointestinal uptake.	1. Ensure adequate fasting. [2] Administering water or other fluids can help promote
--------------------------	--	--

clearance from the hepatobiliary system. In some cases, delayed imaging can allow for background clearance. The use of iodinated oral contrast has been shown to reduce scatter from bowel activity.[13]

-
- | | |
|--|--|
| 2. Infiltrated injection of the radiopharmaceutical. | 2. Carefully check the injection site for any signs of infiltration. An image of the injection site can confirm this. Significant infiltration will require re-injection and re-imaging. |
|--|--|
-

Frequently Asked Questions (FAQs)

1. What is the minimum acceptable radiochemical purity for **99mTc-Sestamibi**?

The minimum acceptable radiochemical purity for **99mTc-Sestamibi** is typically 90% or higher. [1] It is crucial to perform quality control before administration to ensure accurate imaging results.

2. How does lesion size affect the sensitivity of **99mTc-Sestamibi** imaging?

The sensitivity of **99mTc-Sestamibi** imaging is significantly influenced by lesion size. For smaller lesions, particularly those less than 1 cm, the sensitivity is reduced.[6] One study on parathyroid adenomas showed a true-positive rate of 74% for lesions between 1.9 and 3.5 cm, which dropped to 40% for lesions between 0.3 and 1.8 cm.[14]

3. What is the difference between early and delayed imaging, and which is better for small lesions?

Early imaging is typically performed 15-60 minutes post-injection, while delayed imaging is performed 2-4 hours post-injection.[7][15] For small lesions, delayed imaging is often superior

as it allows for the washout of the tracer from surrounding normal tissue, which can improve the target-to-background ratio and make the lesion more conspicuous.[7][8][9]

4. Which collimator should I use for imaging small lesions?

For imaging small lesions, a high-resolution (HR) or ultra-high-resolution (UHR) collimator is generally recommended.[3][4] While these collimators have lower sensitivity (i.e., they detect fewer photons), they provide better spatial resolution, which is critical for distinguishing small objects.

5. Can patient preparation significantly impact the quality of a **99mTc-Sestamibi** scan?

Yes, patient preparation is critical. Fasting for 4-6 hours before the injection of **99mTc-Sestamibi** is important to reduce uptake in the liver and gallbladder, which can otherwise interfere with the images.[2] Additionally, keeping the patient warm can increase peripheral blood flow and potentially enhance tracer delivery to the target tissue.

Quantitative Data Summary

Table 1: Impact of Lesion Size on **99mTc-Sestamibi** Imaging Sensitivity

Lesion Size	Reported Sensitivity	Application
< 1 cm	Decreased	Breast Cancer[6]
0.3 - 1.8 cm	40%	Parathyroid Adenoma[14]
1.9 - 3.5 cm	74%	Parathyroid Adenoma[14]

Table 2: Diagnostic Accuracy of **99mTc-Sestamibi** SPECT/CT for Benign Renal Lesions

Parameter	Value (95% CI)
Sensitivity	86% (66-95%)
Specificity	90% (80-95%)
Data from a meta-analysis of four studies with 117 renal lesions.	

Table 3: Comparison of Collimators for SPECT Imaging

Collimator Type	Primary Advantage	Primary Disadvantage	Best Suited For
High-Sensitivity (HS)	High count rate	Lower spatial resolution	Cardiac SPECT
High-Resolution (HR)	Good spatial resolution	Lower count rate	Small lesion detection in oncology[3]
Ultra-High-Resolution (UHR)	Excellent spatial resolution	Very low count rate	Imaging very small structures

Experimental Protocols

Protocol 1: Quality Control of ^{99m}Tc-Sestamibi using a Sep-Pak Alumina N Cartridge

This protocol provides a rapid method for determining the radiochemical purity of ^{99m}Tc-Sestamibi.

Materials:

- ^{99m}Tc-Sestamibi preparation
- Sep-Pak Alumina N cartridge
- 5 mL 0.9% Sodium Chloride (NaCl) solution
- 10 mL 100% Ethanol (EtOH)
- Dose calibrator
- Lead shielding

Procedure:

- Equilibrate a fresh Sep-Pak cartridge by slowly passing 5 mL of 0.9% NaCl solution through it.
- Using a 1 cc syringe and a small needle, load 0.1 mL of the **99mTc-Sestamibi** solution directly onto the column through the long-neck end of the Sep-Pak.
- Assay the activity of the loaded Sep-Pak in a dose calibrator.
- Elute the column with 10 mL of 100% EtOH. Collect the eluate.
- Push a small volume of air through the Sep-Pak to ensure all the eluate is collected.
- Assay the activity of the eluate and the Sep-Pak separately in the dose calibrator.
- Calculate the radiochemical purity (RCP) using the following formula: $RCP (\%) = \frac{\text{Activity in Eluate}}{\text{Activity in Eluate} + \text{Activity remaining on Sep-Pak}} \times 100$

Protocol 2: 99mTc-Sestamibi SPECT/CT Imaging Protocol for Small Lesion Detection

This protocol is optimized for the detection of small, focal areas of **99mTc-Sestamibi** uptake.

Patient/Subject Preparation:

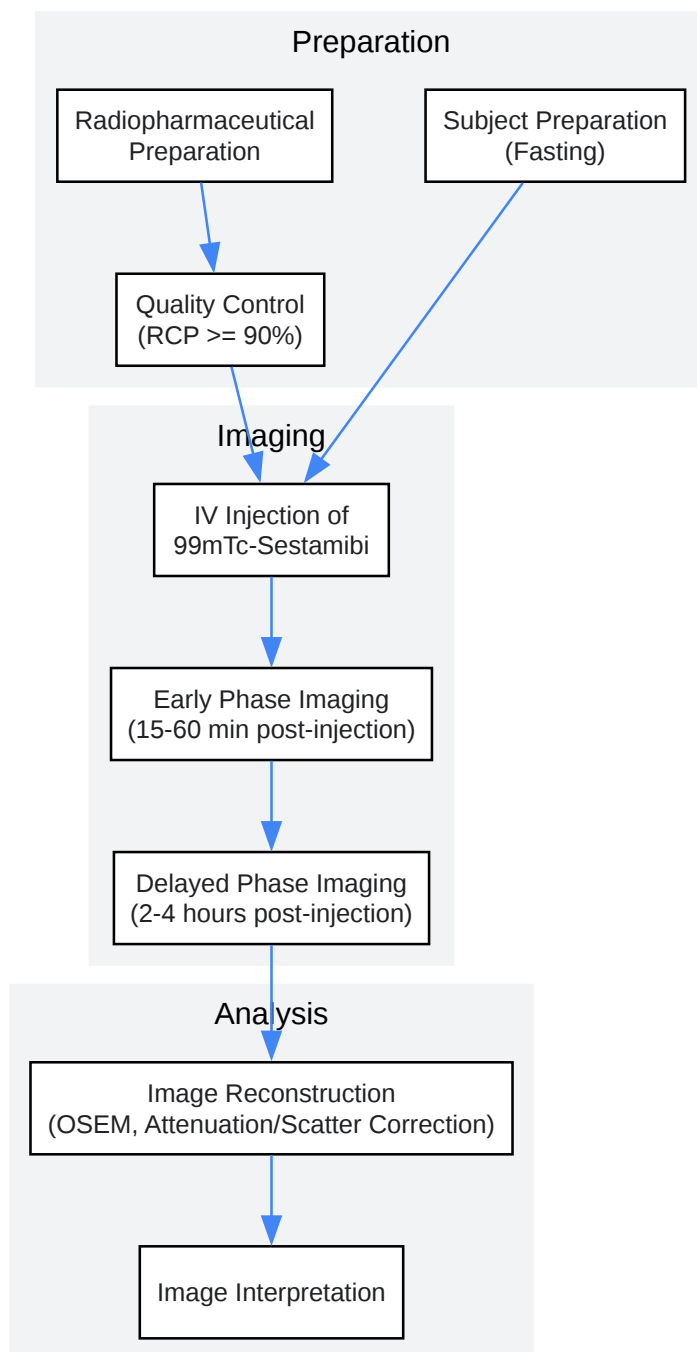
- Fast for a minimum of 4-6 hours prior to the study.[\[2\]](#)
- Ensure adequate hydration.
- Administer 740-1110 MBq (20-30 mCi) of **99mTc-Sestamibi** intravenously.[\[16\]](#)

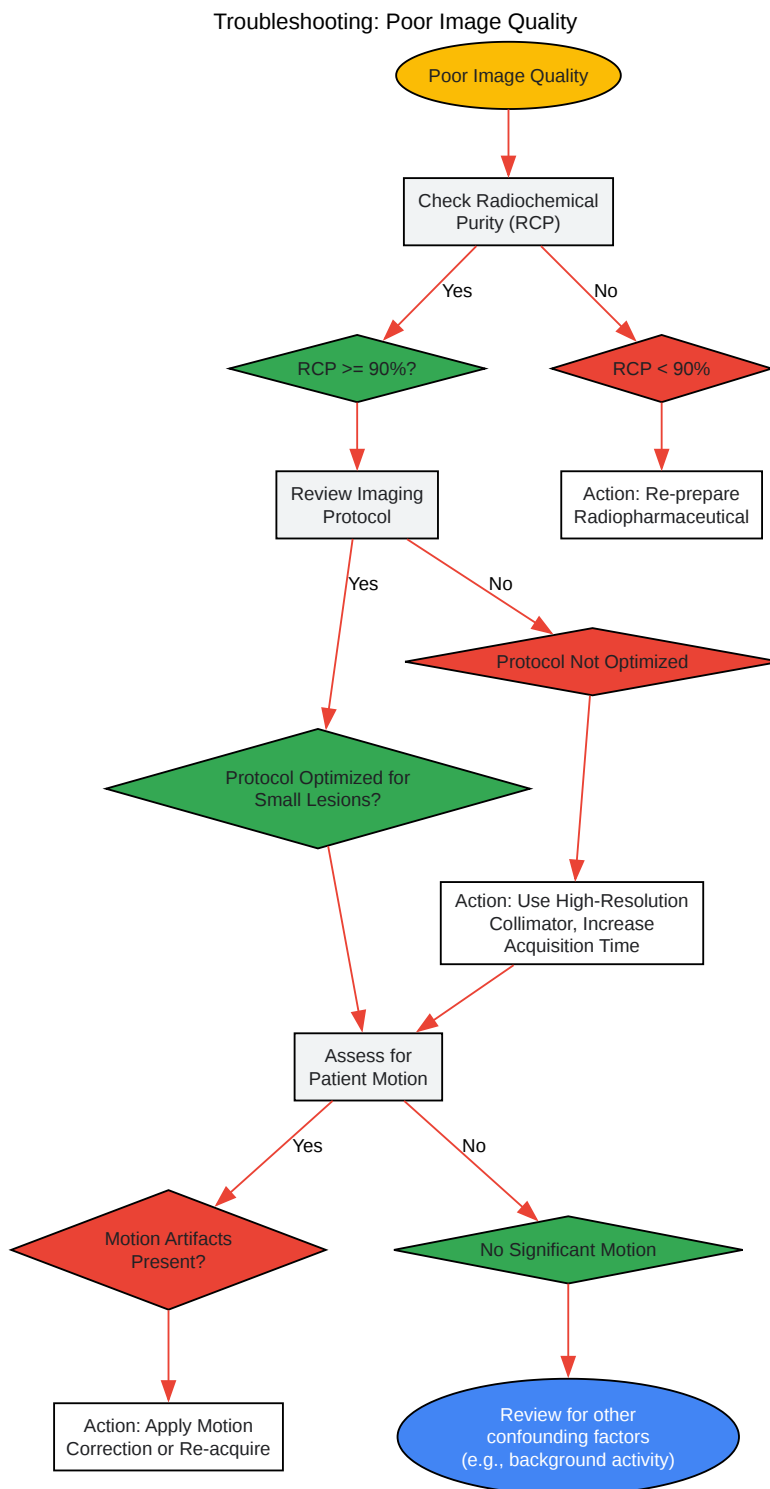
Imaging Protocol:

- Early Phase Imaging (optional, but can be useful for comparison):
 - Acquire planar and SPECT/CT images 15-60 minutes post-injection.
- Delayed Phase Imaging:

- Acquire planar and SPECT/CT images 2-4 hours post-injection.[\[7\]](#)[\[8\]](#)[\[9\]](#)
- SPECT/CT Acquisition Parameters:
 - Collimator: Low-energy high-resolution (LEHR) or ultra-high-resolution (UHR).[\[3\]](#)[\[4\]](#)
 - Energy Window: 140 keV with a 15-20% window.
 - Matrix: 128x128.
 - Rotation: 360 degrees.
 - Projections: 64 or 128 projections.
 - Acquisition Time per Projection: Adjust to obtain adequate counts (e.g., 20-30 seconds).
 - CT Parameters: Use a low-dose CT protocol for anatomical localization and attenuation correction.
- Image Reconstruction:
 - Use an iterative reconstruction algorithm (e.g., OSEM).
 - Apply attenuation and scatter correction.

Visualizations

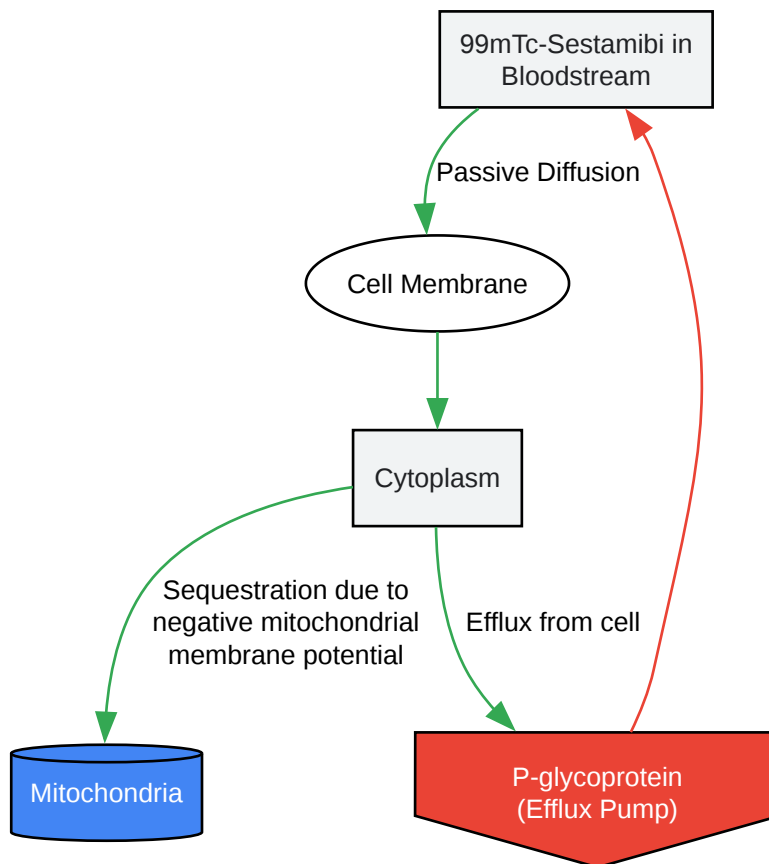
Experimental Workflow: ^{99m}Tc -Sestamibi Imaging[Click to download full resolution via product page](#)Caption: Workflow for **^{99m}Tc -Sestamibi** imaging experiments.



[Click to download full resolution via product page](#)

Caption: Decision tree for troubleshooting poor image quality.

99mTc-Sestamibi Cellular Uptake and Retention



[Click to download full resolution via product page](#)

Need Custom Synthesis?

BenchChem offers custom synthesis for rare earth carbides and specific isotopic labeling.

Email: info@benchchem.com or [Request Quote Online](#).

References

- 1. rads.web.unc.edu [rads.web.unc.edu]
- 2. 99mTc-sestamibi SPECT/CT for the characterization of renal masses: a pictorial guide - PMC [pmc.ncbi.nlm.nih.gov]

- 3. High-Resolution Versus High-Sensitivity SPECT Imaging With Geometric Blurring Compensation for Various Parallel-Hole Collimation Geometries - PMC [pmc.ncbi.nlm.nih.gov]
- 4. jnm.snmjournals.org [jnm.snmjournals.org]
- 5. researchgate.net [researchgate.net]
- 6. Diagnostic accuracy of 99mTc-sestamibi breast imaging: multicenter trial results - PubMed [pubmed.ncbi.nlm.nih.gov]
- 7. radiopaedia.org [radiopaedia.org]
- 8. Quantitative analysis of technetium-99m-sestamibi uptake and washout in parathyroid scintigraphy supports dual mechanisms of lesion conspicuity - PubMed [pubmed.ncbi.nlm.nih.gov]
- 9. researchgate.net [researchgate.net]
- 10. Technetium 99m Sestamibi - StatPearls - NCBI Bookshelf [ncbi.nlm.nih.gov]
- 11. False-negative 99mTc-sestamibi scans: factors and outcomes in primary hyperparathyroidism - PMC [pmc.ncbi.nlm.nih.gov]
- 12. researchgate.net [researchgate.net]
- 13. Simple techniques to reduce bowel activity in cardiac SPECT imaging - PubMed [pubmed.ncbi.nlm.nih.gov]
- 14. Determinants of Tc-99m sestamibi SPECT scan sensitivity in primary hyperparathyroidism - PubMed [pubmed.ncbi.nlm.nih.gov]
- 15. Technetium (99mTc) sestamibi - Wikipedia [en.wikipedia.org]
- 16. drugs.com [drugs.com]
- To cite this document: BenchChem. [Technical Support Center: 99mTc-Sestamibi Imaging of Small Lesions]. BenchChem, [2025]. [Online PDF]. Available at: [https://www.benchchem.com/product/b1243785#overcoming-challenges-in-99mtc-sestamibi-imaging-of-small-lesions]

Disclaimer & Data Validity:

The information provided in this document is for Research Use Only (RUO) and is strictly not intended for diagnostic or therapeutic procedures. While BenchChem strives to provide accurate protocols, we make no warranties, express or implied, regarding the fitness of this product for every specific experimental setup.

Technical Support: The protocols provided are for reference purposes. Unsure if this reagent suits your experiment? [[Contact our Ph.D. Support Team for a compatibility check](#)]

Need Industrial/Bulk Grade? [Request Custom Synthesis Quote](#)

BenchChem

Our mission is to be the trusted global source of essential and advanced chemicals, empowering scientists and researchers to drive progress in science and industry.

Contact

Address: 3281 E Guasti Rd

Ontario, CA 91761, United States

Phone: (601) 213-4426

Email: info@benchchem.com