

# Technical Support Center: 1-Aminocyclobutanecarboxylic Acid (ACBC) PET Scans

**Author:** BenchChem Technical Support Team. **Date:** December 2025

## Compound of Interest

Compound Name: 1-Aminocyclobutanecarboxylic acid

Cat. No.: B3417913

[Get Quote](#)

Welcome to the technical support center for **1-Aminocyclobutanecarboxylic acid** (ACBC), also known as Fluciclovine F-18, PET scan imaging. This resource provides troubleshooting guides and frequently asked questions (FAQs) to help researchers, scientists, and drug development professionals address common artifacts and challenges encountered during their experiments.

## Frequently Asked Questions (FAQs) & Troubleshooting Guides

### Category 1: Physiological Variants & Benign Uptake

Question 1: What are the common patterns of normal physiological uptake of **1-Aminocyclobutanecarboxylic acid**, and how can they be distinguished from pathological findings?

Answer: Understanding the normal biodistribution of ACBC is crucial for accurate scan interpretation. Intense physiological uptake is typically observed in the liver and pancreas.[1][2][3] Moderate uptake is common in the bone marrow and salivary glands, while variable mild to moderate activity can be seen in the pituitary gland and bowel.[3][4] Unlike FDG, ACBC shows minimal uptake in the brain and has low renal excretion in the early imaging window.[3][4]

To differentiate physiological from pathological uptake, consider the following:

- **Location and Symmetry:** Physiological uptake often follows expected anatomical distributions and is typically symmetric (e.g., in salivary glands).
- **Intensity:** While organs like the liver and pancreas show high uptake, suspicious lesions should be evaluated relative to background tissues like blood pool and bone marrow.[1][5]
- **Clinical Context:** Correlate findings with the patient's clinical history and other imaging modalities.

Question 2: How can I differentiate between malignant uptake and benign prostatic hyperplasia (BPH) in the prostate bed?

Answer: Benign prostatic hyperplasia (BPH) can demonstrate variable ACBC uptake, potentially mimicking malignancy.[3] While there is no definitive cutoff, malignant lesions often exhibit more focal and intense uptake compared to the more diffuse and moderate uptake that can be seen with BPH. Correlation with MRI, which can provide anatomical detail of the prostate zones and identify suspicious nodules, is often recommended for equivocal cases.

Question 3: We observed unexpected uptake in the inguinal lymph nodes. Is this indicative of metastasis?

Answer: While metastatic spread to inguinal lymph nodes is possible, it is highly unlikely in most cases of prostate cancer.[6] Moderate, often bilateral, uptake in inguinal lymph nodes is a common finding and is typically considered benign or reactive (inflammatory).[5][6] Clinical correlation is key; in the absence of other signs of disease in that lymphatic drainage region, such uptake is generally not interpreted as metastatic.

## Category 2: Technical & Procedural Artifacts

Question 4: What are the best practices to minimize urinary activity in the bladder and ureters that may obscure the pelvic region?

Answer: Although ACBC has low urinary excretion, accumulation in the bladder and ureters can still interfere with the evaluation of the prostate fossa.[3][5] Mild to moderate bladder activity may be seen in 5-10% of patients.[3] To minimize this artifact:

- Patient Hydration: Ensure the patient is well-hydrated.
- Voiding Schedule: It is recommended that patients avoid voiding for at least 30-60 minutes prior to the injection of the radiotracer.[7] Higher bladder activity has been reported in patients who voided immediately before the injection.[7]
- Delayed Imaging: If initial images are inconclusive due to urinary activity, delayed imaging may be considered to allow for further clearance.
- Ureter Identification: Carefully trace the course of the ureters on fused PET/CT images to distinguish ureteric activity from true nodal disease.[5][7]

Question 5: How can we prevent or correct for motion and respiratory artifacts?

Answer: Motion artifacts, which cause misregistration between the PET and CT images, can lead to inaccurate localization of uptake or the creation of false lesions.[8][9][10]

- Patient Comfort and Instruction: Ensure the patient is comfortable on the scanner bed. Clearly instruct the patient to remain still and breathe shallowly during the acquisition.[8][11]
- Immobilization: Use immobilization devices if necessary.
- Acquisition Protocol: For respiratory motion, which particularly affects the liver dome and lung bases, acquiring the CT scan during shallow, quiet breathing rather than a deep-inspiration breath-hold can better match the PET acquisition, which is performed over several minutes of normal breathing.[5][12]
- Post-Processing: If misregistration is detected, some software allows for manual re-registration of the PET and CT datasets.[9] Reviewing non-attenuation-corrected (NAC) images can also help confirm if a finding is genuine or an artifact, as NAC images are not affected by misregistration artifacts.[8]

Question 6: What is the impact of CT contrast agents on ACBC PET scans, and how should their use be managed?

Answer: High-density oral or intravenous CT contrast agents can lead to attenuation correction artifacts, where the software may overcorrect for attenuation, resulting in artificially high uptake

values in adjacent areas.[\[5\]](#)[\[6\]](#)

- **Protocol Timing:** If IV contrast is necessary for a diagnostic CT, it is recommended to perform the PET acquisition before the contrast-enhanced CT scan.[\[5\]](#)[\[6\]](#) This also minimizes any potential diuretic effect of the contrast agent on the radiotracer distribution.[\[6\]](#)
- **Review of Images:** Always review the CT images for the presence of dense contrast material that could be causing an artifact on the PET data.

## Quantitative Data Summary

The following table summarizes typical Standardized Uptake Values (SUV) for ACBC in normal tissues to aid in differentiating physiological from pathological uptake. Note that these values can vary based on the scanner, reconstruction parameters, and patient-specific factors.

Tissue / Organ	Typical SUVmax / SUVmean Range	Reference
Normal Physiological Uptake		
Liver	High	[1][2][3]
Pancreas	High	[1][2][3]
Bone Marrow	Moderate	[1][3][5]
Salivary Glands	Moderate	[3][4]
Pituitary Gland	Mild to Moderate	[3][4]
Bowel	Variable Mild to Moderate	[3][4]
Muscle	Mild (increases over time)	[1][3]
Lungs	Less than blood pool	[1][3]
Brain	Minimal / Less than blood pool	[3][4]
Common Benign Findings		
Reactive Inguinal Lymph Nodes	Moderate	[5][6]
Benign Prostatic Hyperplasia (BPH)	Variable	[3]
Inflammatory Processes	Can show uptake	[3][6]

## Experimental Protocols

Adherence to standardized protocols is critical for minimizing artifacts and ensuring high-quality, reproducible data.

### Patient Preparation Protocol

- Fasting: Patients should fast for a minimum of 4 hours prior to the scan to reduce background physiological activity.[7]

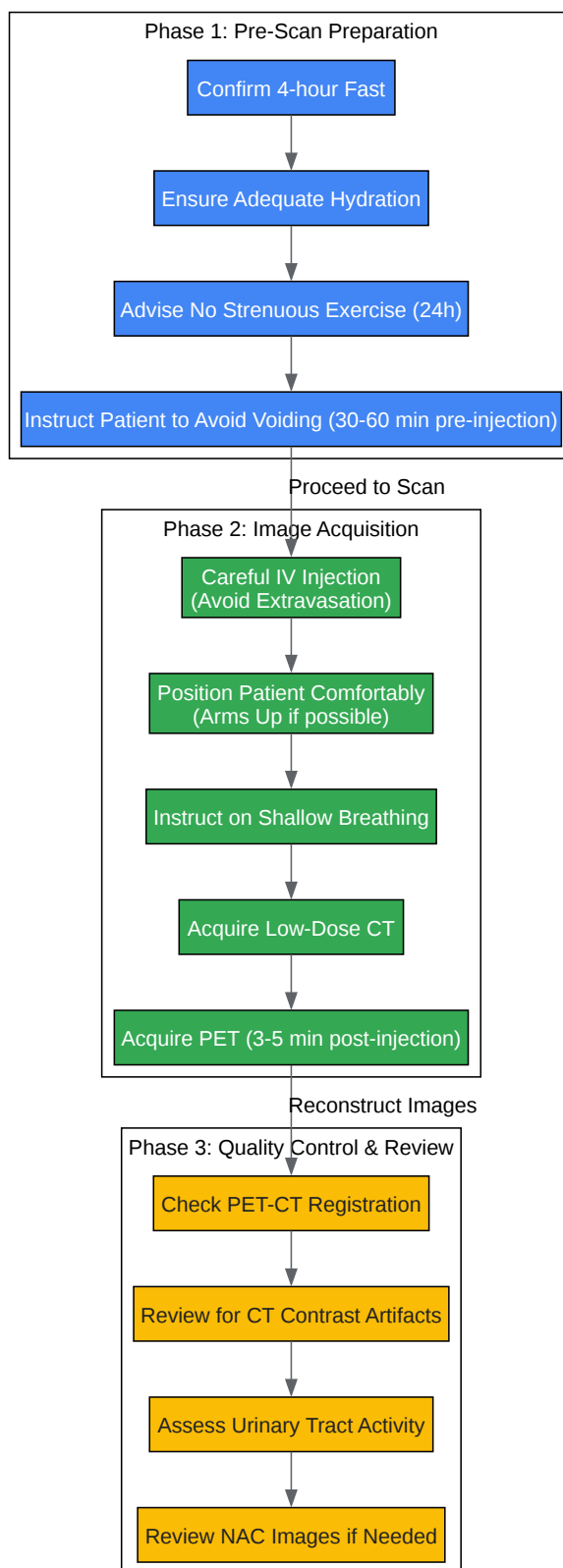
- Hydration: Encourage good hydration by asking the patient to drink plain water. This can help with radiotracer distribution and clearance.[13][14]
- Physical Activity: Patients should avoid strenuous physical activity for 24 hours before the scan to prevent non-specific muscle uptake.[13][15]
- Voiding: Instruct the patient not to empty their bladder for at least 30-60 minutes before the radiotracer injection.[7]
- Medications: Patients can typically take their usual medications.[16]

## Image Acquisition Protocol

- Radiotracer Injection: Administer a standard dose of Fluciclovine F-18 intravenously. Record the injection site, time, and net administered dose for accurate SUV calculations.[6] Avoid extravasation, as this can create a local "hot spot" artifact.[4]
- Uptake Period: The optimal time for imaging is between 3 to 5 minutes post-injection due to the rapid kinetics of ACBC.[1][5]
- Patient Positioning: Position the patient supine on the scanner bed. If imaging the chest or abdomen, positioning with the arms up can reduce beam hardening artifacts on the CT.[8][12]
- CT Scan: Perform a low-dose CT scan from the skull base to the mid-thigh for attenuation correction and anatomical localization. Use a shallow-breathing protocol for the CT acquisition to better match the PET scan.[5][11]
- PET Scan: Begin the PET acquisition immediately following the CT scan, covering the same anatomical range.

## Visual Guides & Workflows

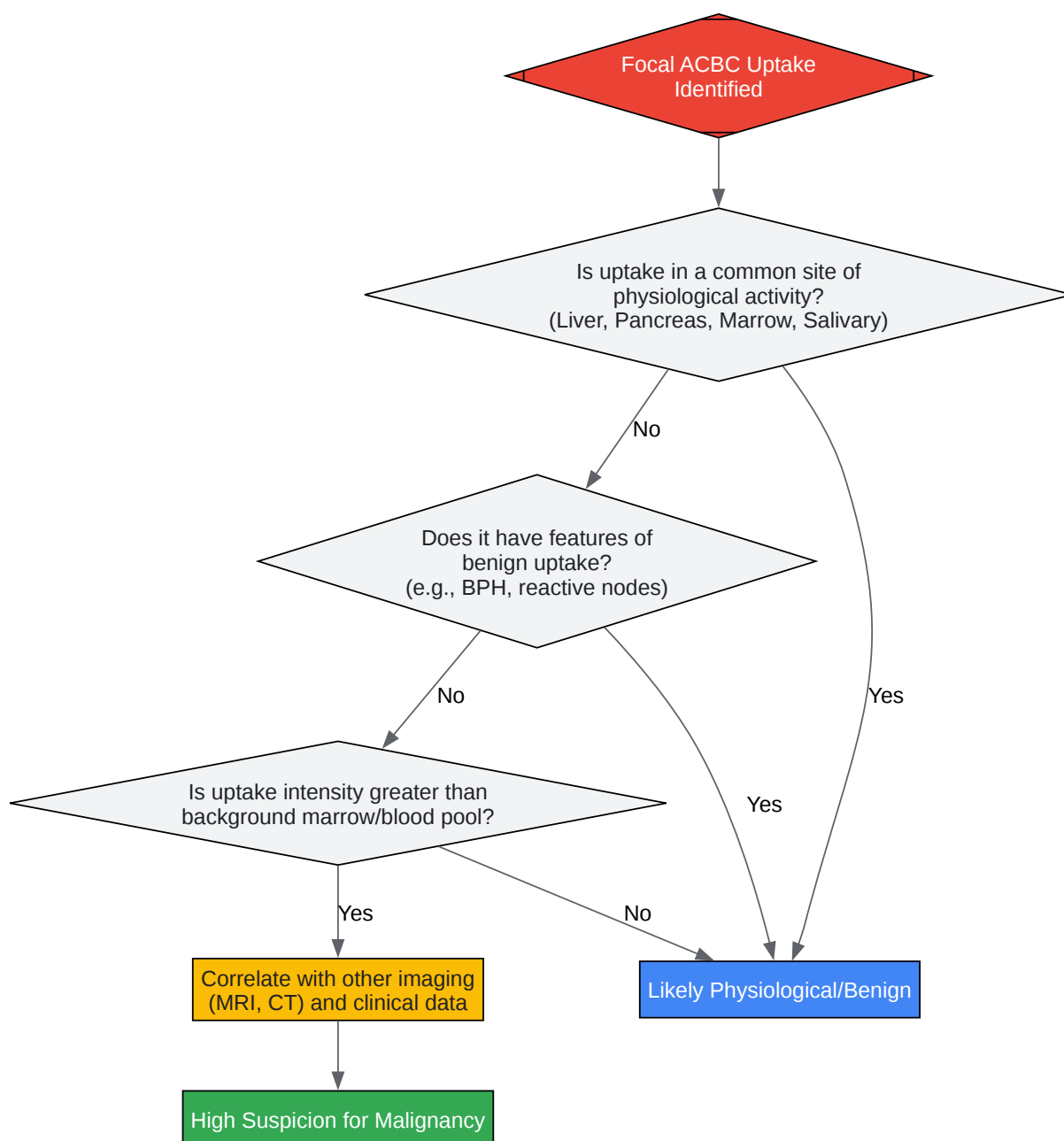
### Diagram 1: Artifact Mitigation Workflow



[Click to download full resolution via product page](#)

Caption: Workflow for minimizing common artifacts in ACBC PET/CT scans.

## Diagram 2: Differentiating Pathological vs. Physiological Uptake





[Click to download full resolution via product page](#)

Caption: Decision pathway for interpreting focal ACBC uptake.

#### Need Custom Synthesis?

BenchChem offers custom synthesis for rare earth carbides and specific isotopic labeling.

Email: [info@benchchem.com](mailto:info@benchchem.com) or [Request Quote Online](#).

## References

- 1. researchgate.net [researchgate.net]
- 2. Characterising 18F-fluciclovine uptake in breast cancer through the use of dynamic PET/CT imaging - PMC [pmc.ncbi.nlm.nih.gov]
- 3. Anti-1-amino-3-18F-fluorocyclobutane-1-carboxylic acid: physiologic uptake patterns, incidental findings, and variants that may simulate disease - PubMed [pubmed.ncbi.nlm.nih.gov]
- 4. med.emory.edu [med.emory.edu]
- 5. tech.snmjournals.org [tech.snmjournals.org]
- 6. tech.snmjournals.org [tech.snmjournals.org]
- 7. tech.snmjournals.org [tech.snmjournals.org]
- 8. cme.lww.com [cme.lww.com]
- 9. asnc.org [asnc.org]
- 10. Recognizing and preventing artifacts with SPECT and PET imaging | Radiology Key [radiologykey.com]
- 11. gravitas.acr.org [gravitas.acr.org]
- 12. PET/CT Artifacts - PMC [pmc.ncbi.nlm.nih.gov]
- 13. missouricancer.com [missouricancer.com]
- 14. PET/CT Scan: How to Prepare, What to Expect & Safety Tips [radiology.ucsf.edu]
- 15. flcancer.com [flcancer.com]
- 16. How to Prepare for Your PET/CT Scan - General Directions | Brown University Health [brownhealth.org]

- To cite this document: BenchChem. [Technical Support Center: 1-Aminocyclobutanecarboxylic Acid (ACBC) PET Scans]. BenchChem, [2025]. [Online PDF]. Available at: [<https://www.benchchem.com/product/b3417913#common-artifacts-in-1-aminocyclobutanecarboxylic-acid-pet-scans>]

---

### Disclaimer & Data Validity:

The information provided in this document is for Research Use Only (RUO) and is strictly not intended for diagnostic or therapeutic procedures. While BenchChem strives to provide accurate protocols, we make no warranties, express or implied, regarding the fitness of this product for every specific experimental setup.

**Technical Support:** The protocols provided are for reference purposes. Unsure if this reagent suits your experiment? [[Contact our Ph.D. Support Team for a compatibility check](#)]

**Need Industrial/Bulk Grade?** [Request Custom Synthesis Quote](#)

## BenchChem

Our mission is to be the trusted global source of essential and advanced chemicals, empowering scientists and researchers to drive progress in science and industry.

### Contact

Address: 3281 E Guasti Rd  
Ontario, CA 91761, United States  
Phone: (601) 213-4426  
Email: [info@benchchem.com](mailto:info@benchchem.com)