

Technical Support Center: 19-Iodocholesterol 3-acetate Scintigraphy

Author: BenchChem Technical Support Team. **Date:** December 2025

Compound of Interest

Compound Name: 19-Iodocholesterol 3-acetate

Cat. No.: B1208695

[Get Quote](#)

This technical support center provides troubleshooting guidance and frequently asked questions (FAQs) for researchers, scientists, and drug development professionals utilizing **19-Iodocholesterol 3-acetate** (also known as NP-59) scintigraphy.

Troubleshooting Guide

This guide addresses specific issues that may arise during your experiments, leading to potential artifacts and pitfalls in your imaging results.

Issue 1: Suboptimal or Absent Adrenal Gland Visualization

- Question: We performed scintigraphy, but the adrenal glands are not visible or show very poor uptake of the radiotracer. What could be the cause?
- Answer: Several factors can lead to poor or absent visualization of the adrenal glands. A primary reason could be the presence of an adrenocortical carcinoma, which often does not concentrate NP-59 sufficiently to be visualized.[1] Additionally, certain medications can interfere with the uptake of iodocholesterol. It is crucial to ensure that patients have discontinued any interfering drugs prior to the procedure.[2] Another possibility is a technical error in the administration of the radiopharmaceutical or a malfunction in the imaging equipment. A thorough review of the patient's medication history and the experimental protocol is recommended.

Issue 2: Unexpected or Misleading Tracer Uptake

- Question: We are observing unilateral uptake in a patient with Cushing's syndrome, which we interpreted as a benign adenoma. Could this be a misinterpretation?
- Answer: Yes, this could be a significant pitfall. While unilateral visualization on an NP-59 scan in a patient with Cushing's syndrome is often indicative of a benign adrenocortical adenoma, it is not a definitive diagnosis.[1] Well-differentiated cortisol-secreting adrenocortical carcinomas (ACCs) can also demonstrate intense uptake of NP-59, leading to a misinterpretation of the lesion as benign.[1] This can have serious implications for the patient's surgical management. Therefore, in the context of Cushing's syndrome or other states of adrenocortical hormone excess, unilateral uptake in an adrenal tumor should not be automatically considered benign.[1]
- Question: We observed bilateral asymmetrical uptake of the radiotracer. How should this be interpreted?
- Answer: Bilateral asymmetric uptake of NP-59 can be challenging to interpret and may not definitively distinguish between an adenoma with a partially suppressed contralateral gland and asymmetrical bilateral hyperplasia.[3][4] This pattern requires careful correlation with clinical, biochemical, and other imaging findings, such as CT or MRI, to arrive at an accurate diagnosis.

Issue 3: Discordant Results with Other Imaging Modalities

- Question: The results from our 19-Iodocholesterol scintigraphy are inconsistent with the findings from a recent CT scan. How should we proceed?
- Answer: Discordance between functional imaging with NP-59 and anatomical imaging with CT is not uncommon. For instance, a CT scan may identify a nodule that does not show uptake on scintigraphy, or vice versa. In cases of primary aldosteronism, scintigraphy has been shown to correctly distinguish between unilateral and bilateral lesions in a higher percentage of cases than CT alone.[5] This is because CT may not detect smaller adenomas or may misinterpret bilateral hyperplasia as a single nodule.[5] When results are discordant, a comprehensive evaluation including clinical and biochemical data is essential. In some complex cases, adrenal venous sampling (AVS) may be necessary to resolve the discrepancy, although NP-59 scintigraphy is often considered a valuable non-invasive alternative.[3][6][7]

Frequently Asked Questions (FAQs)

Q1: What are the most common artifacts in 19-Iodocholesterol scintigraphy?

A1: The most common artifacts include:

- Subdiaphragmatic radioactivity: Uptake in the liver, gallbladder, and bowel can interfere with the visualization of the adrenal glands, particularly the right adrenal gland.[8] This can lead to false-positive or false-negative interpretations.
- Free radioiodine uptake: Inadequate thyroid blockade can result in the uptake of free ^{131}I by the thyroid gland, which can obscure imaging of the adrenal glands, especially in the anterior view.
- Patient motion: Movement during the long acquisition times can lead to blurred images and misregistration artifacts.

Q2: Which medications can interfere with 19-Iodocholesterol uptake?

A2: A variety of medications can interfere with the biodistribution of 19-Iodocholesterol and should be discontinued prior to the study. These include:

- Spironolactone and eplerenone[9]
- Corticosteroids (e.g., dexamethasone, unless used for suppression protocols)[2]
- Oral contraceptives[2]
- Diuretics[2]
- Propranolol[2]
- Ketoconazole[2]
- Cholestyramine[2]
- Some hypolipemic agents[2]

- Recent administration of iodinated contrast media[10]

Q3: What is the purpose of dexamethasone suppression in NP-59 scintigraphy?

A3: Dexamethasone suppression is a critical component of the protocol, particularly when evaluating for primary aldosteronism or hyperandrogenism.[3] Dexamethasone suppresses the pituitary-adrenal axis, reducing ACTH-dependent uptake of iodocholesterol in normal adrenal tissue and in cases of bilateral adrenal hyperplasia.[3] This enhances the visualization of adrenal adenomas, which function autonomously and continue to take up the tracer despite dexamethasone administration.

Q4: How does the diagnostic accuracy of 19-Iodocholesterol scintigraphy vary for different adrenal disorders?

A4: The accuracy of NP-59 scintigraphy is dependent on the specific clinical indication. It has been reported to have high accuracy, approaching 100%, for Cushing's syndrome and hyperandrogenism.[11][12] However, its accuracy is lower in cases of primary aldosteronism and euadrenal tumors, with reported ranges around 71% and 75%, respectively.[11][12]

Quantitative Data Summary

The following tables summarize key quantitative data related to the performance of 19-Iodocholesterol scintigraphy.

Table 1: Diagnostic Accuracy of NP-59 Scintigraphy in Adrenal Disorders

Clinical Condition	Sensitivity	Specificity	Positive Predictive Value	Negative Predictive Value	Accuracy	Reference
Primary Aldosteronism (APA Detection)	83.3%	44.4%	92.3%	-	71%	[3] [11]
Cushing's Syndrome	-	-	-	-	100%	[11] [12]
Hyperandrogenism	-	-	-	-	100%	[11] [12]
Euadrenal Tumors	-	-	-	-	75%	[11] [12]
Adrenal Adenomas (General)	100%	71%	94%	100%	95%	[13]

APA: Aldosterone-Producing Adenoma

Table 2: Impact of SPECT/CT on Diagnostic Performance for APA Detection

Imaging Modality	Area Under the Curve (AUC)	p-value (vs. Planar)
Planar Imaging	0.5379	-
SPECT	0.6742	0.1575
SPECT/CT	0.7424	0.0390

Data from a study on patients with inconclusive AVS and CT results.[\[14\]](#)

Experimental Protocols

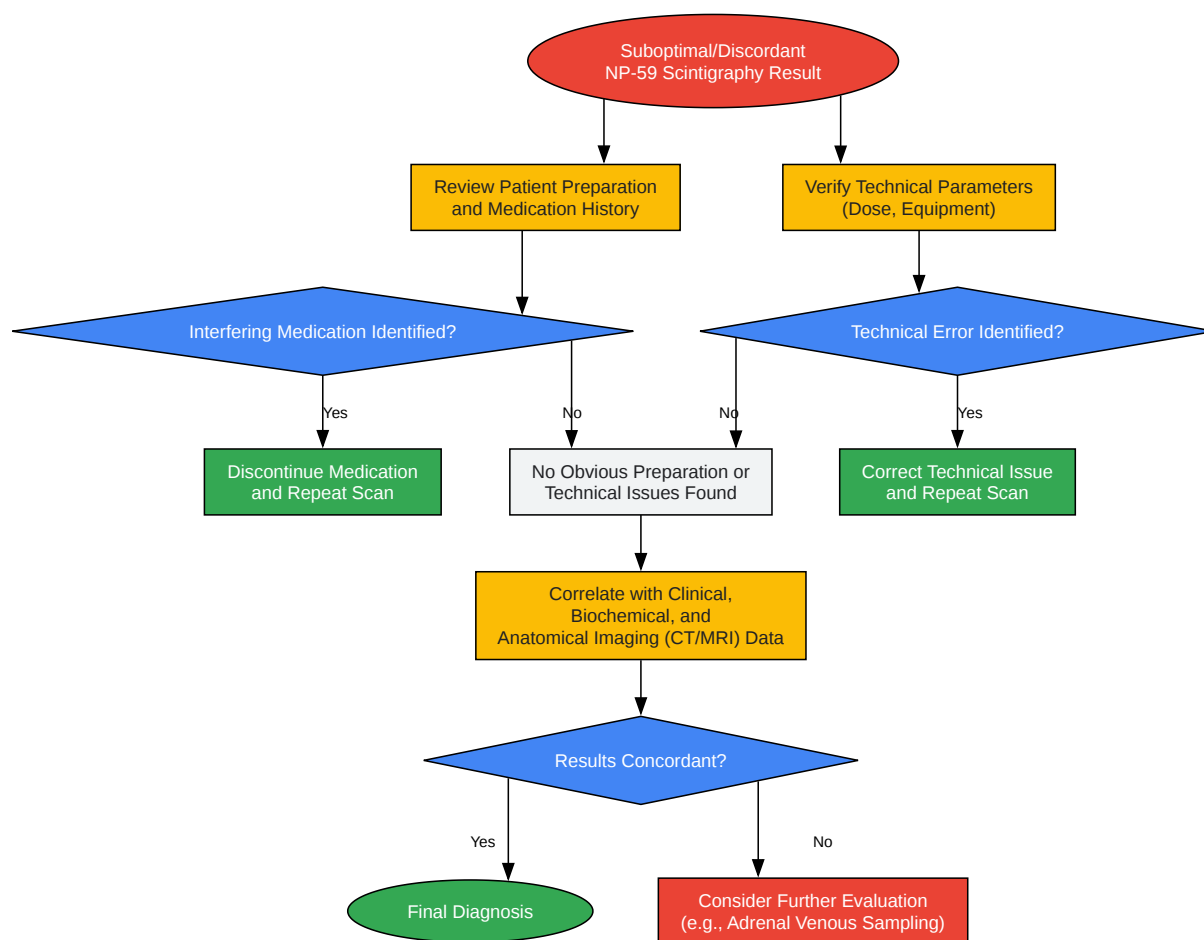
1. Patient Preparation Protocol

- Medication Review: Discontinue all interfering medications at least 48 hours prior to the investigation, and in some cases, for longer periods (e.g., spironolactone).[2]
- Thyroid Blockade: To prevent uptake of free ^{131}I by the thyroid gland, administer a thyroid blocking agent.[2][15]
 - Option A: Lugol's solution (1 ml daily) for 8 days, starting 1 day before tracer injection.[6]
 - Option B: Potassium iodide (100-150 mg per day) or potassium perchlorate (200-400 mg per day) for 5-10 days, starting the day before tracer injection.[2]
- Dexamethasone Suppression (if indicated): For suspected primary aldosteronism or hyperandrogenism, administer dexamethasone to suppress ACTH-dependent tracer uptake. A common regimen is 1 mg orally four times daily, starting 7 days before tracer injection and continuing throughout the imaging period.[6]

2. Radiopharmaceutical Administration and Imaging Protocol

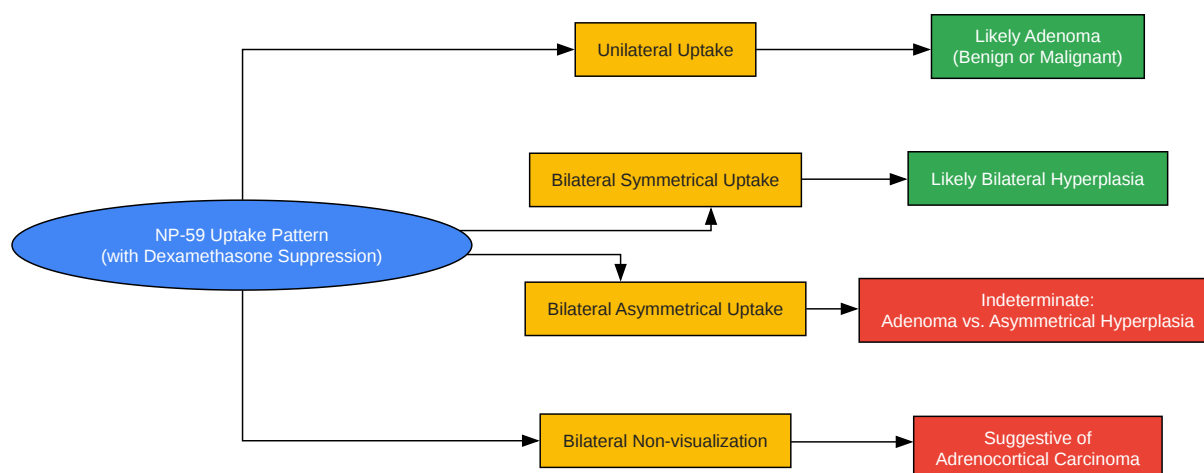
- Radiopharmaceutical: Administer 37 MBq (1 mCi) of ^{131}I -6 β -iodomethyl-19-norcholesterol (NP-59) intravenously.
- Imaging Schedule:
 - Acquire planar anterior and posterior images on days 3, 4, and 5 after tracer injection.[3] Some protocols may extend imaging to day 7.[6][9]
 - Imaging duration is typically 20 minutes (1200 seconds) per view.[6]
- SPECT/CT Imaging (Optional but Recommended):
 - If available, perform SPECT/CT imaging to improve localization and diagnostic accuracy.[3][14]
 - SPECT/CT can be performed on a single day, typically day 3 or 4.[6]

Visualizations



[Click to download full resolution via product page](#)

Caption: Troubleshooting workflow for suboptimal or discordant NP-59 scintigraphy results.



[Click to download full resolution via product page](#)

Caption: Interpretation pathway for different NP-59 uptake patterns.

Need Custom Synthesis?

BenchChem offers custom synthesis for rare earth carbides and specific isotopic labeling.

Email: info@benchchem.com or [Request Quote Online](#).

References

- 1. Adrenal scintigraphy of well-differentiated (functioning) adrenocortical carcinomas: potential surgical pitfalls - PubMed [pubmed.ncbi.nlm.nih.gov]
- 2. European Nuclear Medicine Guide [nucmed-guide.app]
- 3. Diagnostic value of adrenal iodine-131 6-beta-iodomethyl-19-norcholesterol scintigraphy for primary aldosteronism: a retrospective study at a medical center in North Taiwan - PMC [pmc.ncbi.nlm.nih.gov]

- 4. academic.oup.com [academic.oup.com]
- 5. Efficacy of iodine-131 6beta-methyl-iodo-19-norcholesterol scintigraphy and computed tomography in patients with primary aldosteronism - PubMed [pubmed.ncbi.nlm.nih.gov]
- 6. hkjr.org [hkjr.org]
- 7. 131I-6β-iodomethyl-19-norcholesterol adrenal scintigraphy as an alternative to adrenal venous sampling in differentiating aldosterone-producing adenoma from bilateral idiopathic hyperaldosteronism - PubMed [pubmed.ncbi.nlm.nih.gov]
- 8. Subdiaphragmatic activity-related artifacts in myocardial perfusion scintigraphy - PMC [pmc.ncbi.nlm.nih.gov]
- 9. [131I]6β-Iodomethyl-19-norcholesterol SPECT/CT for the Lateralization of Mineralocorticoid Overproduction in Primary Aldosteronism - PMC [pmc.ncbi.nlm.nih.gov]
- 10. Preparing For Your Procedure | Capital Health Hospitals [capitalhealth.org]
- 11. Diagnostic accuracy and pitfalls of [iodine-131]6-beta-iodomethyl-19-norcholesterol (NP-59) imaging - PubMed [pubmed.ncbi.nlm.nih.gov]
- 12. jnm.snmjournals.org [jnm.snmjournals.org]
- 13. Diagnostic accuracy of radionuclide imaging using 131I nor-cholesterol or meta-iodobenzylguanidine in patients with hypersecreting or non-hypersecreting adrenal tumours - PubMed [pubmed.ncbi.nlm.nih.gov]
- 14. jnm.snmjournals.org [jnm.snmjournals.org]
- 15. Thyroidal accumulation of 131I during adrenal gland scintigraphy with 131I-19-iodocholesterol: effects of thyroid blocking agents - PubMed [pubmed.ncbi.nlm.nih.gov]
- To cite this document: BenchChem. [Technical Support Center: 19-Iodocholesterol 3-acetate Scintigraphy]. BenchChem, [2025]. [Online PDF]. Available at: [<https://www.benchchem.com/product/b1208695#artifacts-and-pitfalls-in-19-iodocholesterol-3-acetate-scintigraphy>]

Disclaimer & Data Validity:

The information provided in this document is for Research Use Only (RUO) and is strictly not intended for diagnostic or therapeutic procedures. While BenchChem strives to provide accurate protocols, we make no warranties, express or implied, regarding the fitness of this product for every specific experimental setup.

Technical Support: The protocols provided are for reference purposes. Unsure if this reagent suits your experiment? [[Contact our Ph.D. Support Team for a compatibility check](#)]

Need Industrial/Bulk Grade? [Request Custom Synthesis Quote](#)

BenchChem

Our mission is to be the trusted global source of essential and advanced chemicals, empowering scientists and researchers to drive progress in science and industry.

Contact

Address: 3281 E Guasti Rd
Ontario, CA 91761, United States
Phone: (601) 213-4426
Email: info@benchchem.com