

# Technical Support Center: 18F-PSMA-1007

## Uptake in Benign Lesions

**Author:** BenchChem Technical Support Team. **Date:** December 2025

### Compound of Interest

Compound Name: 18F-Psma 1007

Cat. No.: B11934056

[Get Quote](#)

This technical support center provides troubleshooting guides and frequently asked questions (FAQs) to assist researchers, scientists, and drug development professionals in addressing the challenges of 18F-PSMA-1007 uptake in benign lesions.

## Frequently Asked Questions (FAQs)

**Q1:** We are observing 18F-PSMA-1007 uptake in tissues that are not pathologically confirmed as malignant prostate cancer. What are the common types of benign lesions that can show uptake?

**A1:** It is well-documented that 18F-PSMA-1007 can accumulate in various benign lesions, which can sometimes lead to false-positive findings. Common sites of benign uptake include:

- **Bone Lesions:** Healing fractures, degenerative changes such as osteophytes and arthritis, Paget's disease, fibrous dysplasia, and hemangiomas are frequently reported to show 18F-PSMA-1007 uptake.[\[1\]](#)[\[2\]](#)[\[3\]](#)[\[4\]](#)[\[5\]](#)
- **Ganglia:** Sympathetic ganglia, including celiac, stellate, and sacral ganglia, are common sites of physiologic uptake.[\[6\]](#)[\[7\]](#)[\[8\]](#)[\[9\]](#)
- **Inflammatory Conditions:** Tissues with active inflammation can exhibit tracer uptake. This includes benign prostatic hyperplasia (BPH) with chronic inflammation, which can sometimes show high-grade uptake mimicking malignancy.[\[10\]](#)[\[11\]](#)

- Vascular Structures and Neoplasms: PSMA is expressed in the neovasculature of some tumors. Benign vascular tumors like angioliomas have also been shown to have uptake due to PSMA expression in capillaries.[\[12\]](#)[\[13\]](#)
- Other Tissues: Non-specific uptake has also been noted in lymph nodes and other soft tissues.[\[6\]](#)

Q2: What are the proposed mechanisms for <sup>18</sup>F-PSMA-1007 uptake in these benign conditions?

A2: The uptake of <sup>18</sup>F-PSMA-1007 in benign lesions is not fully understood but is thought to be multifactorial:

- PSMA Expression in Neovasculature: Prostate-specific membrane antigen (PSMA) is not exclusive to prostate cancer cells and is known to be expressed in the endothelium of new blood vessels (neovasculature) associated with various pathological processes, including inflammation and tissue repair.[\[14\]](#)
- Inflammatory Cell Infiltration: Activated immune cells, such as macrophages and lymphocytes present in inflammatory lesions, may contribute to PSMA-ligand uptake.[\[14\]](#) For instance, high-grade uptake in benign prostatic hyperplasia has been associated with chronic inflammatory infiltrates.[\[11\]](#)
- Tissue Remodeling and Repair: Processes involving tissue repair, such as in bone fractures, exhibit increased metabolic activity and angiogenesis, which can lead to PSMA-ligand accumulation.[\[2\]](#)[\[3\]](#)
- Direct PSMA Expression: Some benign tissues and tumors, like angioliomas, have been shown to express PSMA directly in their capillaries.[\[12\]](#)[\[13\]](#)

Q3: Is the incidence of benign lesion uptake higher with <sup>18</sup>F-PSMA-1007 compared to other PSMA-targeted radiotracers?

A3: Yes, studies have indicated that <sup>18</sup>F-PSMA-1007 has a higher incidence of uptake in benign lesions compared to <sup>68</sup>Ga-labeled PSMA ligands.[\[1\]](#)[\[6\]](#)[\[14\]](#) This could be attributed to several factors, including the lower positron energy and higher spatial resolution of <sup>18</sup>F, potentially leading to better detection of smaller or lower-expressing lesions.[\[8\]](#)[\[14\]](#)

## Troubleshooting Guides

### Issue 1: Differentiating Benign from Malignant Bone Uptake

Symptoms: Focal bone uptake of  $^{18}\text{F}$ -PSMA-1007 is observed on PET/CT in a pattern that is not definitively characteristic of metastasis.

Possible Causes:

- Metastatic disease from prostate cancer.
- Benign bone lesions such as healing fractures, degenerative arthritis, osteophytes, Schmorl's nodes, Paget's disease, fibrous dysplasia, or intra-osseous hemangiomas.[2]

Troubleshooting Steps:

- Correlate with Low-Dose CT: Carefully examine the corresponding low-dose CT images for any morphological correlates. Benign conditions often have recognizable features (e.g., signs of old fractures, degenerative changes).[1] However, be aware that not all benign uptakes have a clear CT correlate.
- Quantitative Analysis (SUVmax): While there is an overlap, SUVmax values can be helpful. Malignant lesions generally exhibit higher SUVmax values than benign ones. One study suggested an optimal SUVmax cutoff of 7.71 to differentiate metastases from benign lesions.[15] However, this should be used with caution as high-grade inflammation can also lead to high SUVmax values.[10][11]
- Consider Patient History: A history of trauma may suggest that uptake in the ribs or other bones could be due to healing fractures.[3][16]
- Follow-up Imaging: If the nature of the lesion remains unclear, follow-up imaging can be instrumental. Benign lesions are expected to remain stable or resolve, whereas malignant lesions may progress.
- Biopsy: In cases where the finding significantly impacts treatment decisions and cannot be clarified by other means, a biopsy for histopathological confirmation is the gold standard.

## Quantitative Data Summary

The following tables summarize the Standardized Uptake Values (SUV) for 18F-PSMA-1007 in benign and malignant lesions as reported in various studies.

Table 1: 18F-PSMA-1007 SUVmax in Benign vs. Malignant Lesions

Lesion Type	Median SUVmax (Range)	Study
Benign Lesions	5.3 (3.0–42.7)	Rauschner et al.[6]
Suspected Tumor	9.4 (2.7–234.4)	Rauschner et al.[6]
Benign Lesions	3.14 (mean)	An et al.[15]
Metastases	10.72 (mean)	An et al.[15]

Table 2: 18F-PSMA-1007 SUV in Sympathetic Ganglia

Ganglion Location	Mean SUVmax ± SD	Mean SUVmean ± SD	Study
Coeliac	3.13 ± 0.85	2.28 ± 0.64	Mamlins et al.[7][9]
Cervical	2.73 ± 0.69	1.62 ± 0.43	Mamlins et al.[7][9]
Sacral	1.67 ± 0.50	1.15 ± 0.33	Mamlins et al.[7][9]

## Detailed Experimental Protocols

### Protocol 1: Immunohistochemistry for PSMA Expression in Tissue Samples

This protocol is designed to verify the expression of Prostate-Specific Membrane Antigen (PSMA) in tissue sections, which can help elucidate the mechanism of 18F-PSMA-1007 uptake.

#### 1. Tissue Preparation:

- Fix fresh tissue samples in 10% neutral buffered formalin for 24-48 hours.
- Dehydrate the samples through a graded series of ethanol.
- Clear the samples in xylene.
- Embed the samples in paraffin wax.
- Cut 4-5  $\mu\text{m}$  thick sections using a microtome and mount them on positively charged slides.

## 2. Deparaffinization and Rehydration:

- Bake slides at 60°C for 1 hour.
- Deparaffinize sections in xylene (2 changes, 5 minutes each).
- Rehydrate through graded ethanol (100%, 95%, 70%), 5 minutes each.
- Rinse with distilled water.

## 3. Antigen Retrieval:

- Perform heat-induced epitope retrieval (HIER) using a citrate buffer (pH 6.0) or EDTA buffer (pH 9.0).
- Heat the slides in the retrieval solution at 95-100°C for 20-30 minutes.
- Allow slides to cool to room temperature.

## 4. Staining:

- Block endogenous peroxidase activity with 3% hydrogen peroxide for 10 minutes.
- Rinse with phosphate-buffered saline (PBS).
- Block non-specific binding with a protein block (e.g., 5% normal goat serum) for 30 minutes.
- Incubate with a primary antibody against PSMA (e.g., rabbit anti-PSMA monoclonal antibody) overnight at 4°C.
- Rinse with PBS.
- Incubate with a secondary antibody (e.g., HRP-conjugated goat anti-rabbit IgG) for 1 hour at room temperature.
- Rinse with PBS.
- Develop the signal using a DAB (3,3'-diaminobenzidine) substrate kit.
- Counterstain with hematoxylin.

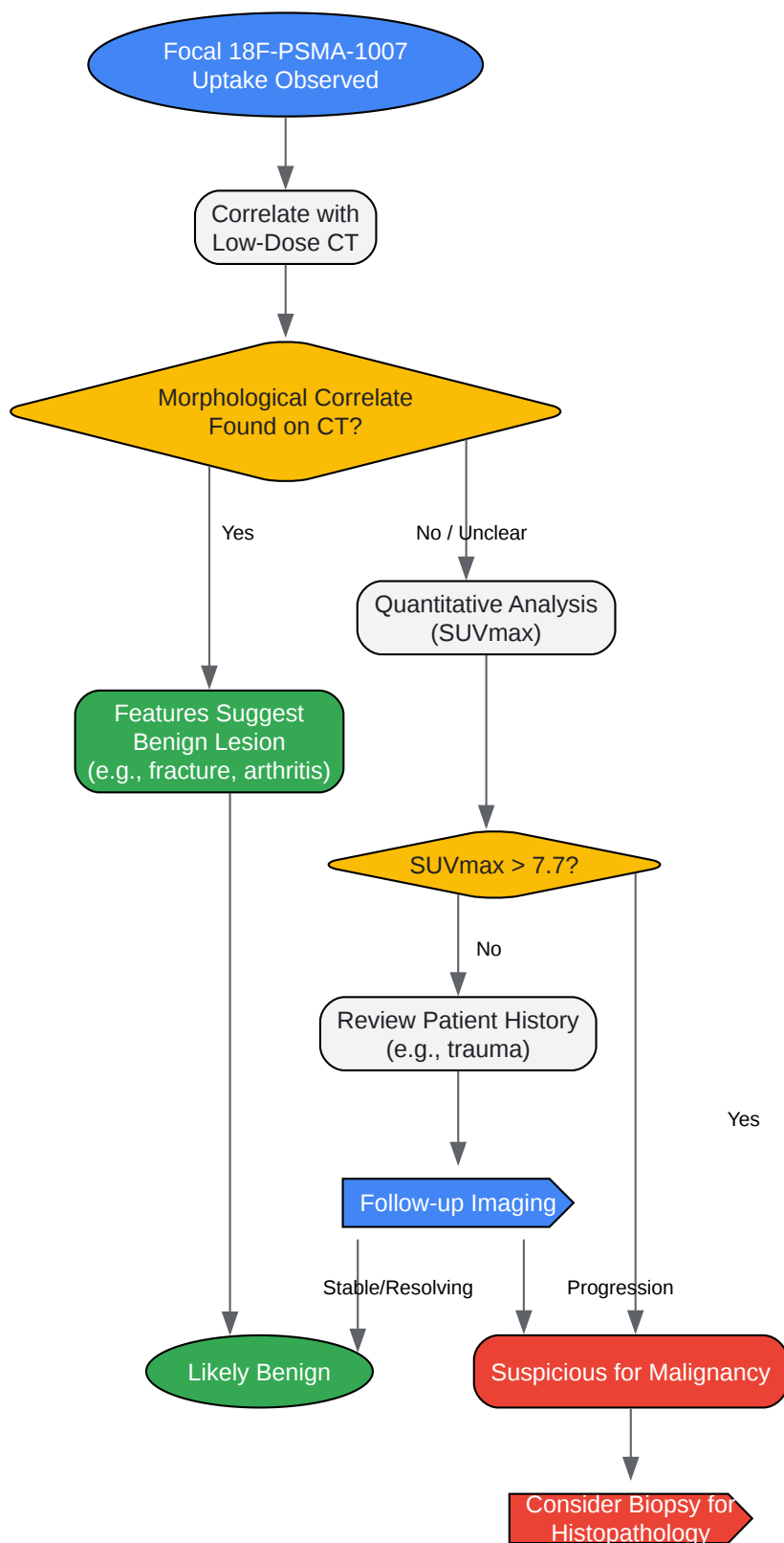
## 5. Dehydration and Mounting:

- Dehydrate sections through graded ethanol and xylene.
- Mount with a permanent mounting medium.

#### 6. Analysis:

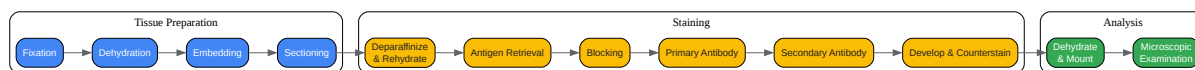
- Examine the slides under a microscope. PSMA-positive cells will show brown staining. Evaluate the intensity and localization (membranous, cytoplasmic) of the staining.

## Visualizations



[Click to download full resolution via product page](#)

Caption: Workflow for troubleshooting unspecific 18F-PSMA-1007 bone uptake.



[Click to download full resolution via product page](#)

Caption: Experimental workflow for PSMA immunohistochemistry.

### Need Custom Synthesis?

BenchChem offers custom synthesis for rare earth carbides and specific isotopic labeling.

Email: [info@benchchem.com](mailto:info@benchchem.com) or [Request Quote Online](#).

## References

1. Skeletal <sup>18</sup>F-PSMA-1007 uptake in prostate cancer patients - PMC [pmc.ncbi.nlm.nih.gov]
2. jnm.snmjournals.org [jnm.snmjournals.org]
3. researchgate.net [researchgate.net]
4. mdpi.com [mdpi.com]
5. researchgate.net [researchgate.net]
6. academic.oup.com [academic.oup.com]
7. PSMA-1007 Uptake in Ganglia of the Sympathetic Trunk and Its Intra-individual Reproducibility - PMC [pmc.ncbi.nlm.nih.gov]
8. Intra-Individual Comparison of Physiologic [68Ga]Ga-PSMA-11 and [18F]PSMA-1007 Uptake in Ganglia in Patients with Prostate Cancer: A Retrospective, Monocentric Analysis [mdpi.com]
9. PSMA-1007 Uptake in Ganglia of the Sympathetic Trunk and Its Intra-individual Reproducibility - PubMed [pubmed.ncbi.nlm.nih.gov]
10. researchgate.net [researchgate.net]
11. High-grade <sup>18</sup>F-PSMA-1007 Uptake of Benign Prostatic Hyperplasia With Chronic Inflammation - PubMed [pubmed.ncbi.nlm.nih.gov]



- 12. 18F-PSMA-1007 PET/CT uptake in multiple angiolipomas caused by PSMA expression in capillaries: a case report - Wang - Translational Andrology and Urology [tau.amegroups.org]
- 13. researchgate.net [researchgate.net]
- 14. Focal unspecific bone uptake on [18F]-PSMA-1007 PET: a multicenter retrospective evaluation of the distribution, frequency, and quantitative parameters of a potential pitfall in prostate cancer imaging - PMC [pmc.ncbi.nlm.nih.gov]
- 15. Intra-Individual Comparison of 18F-PSMA-1007 and 18F-FDG PET/CT in the Evaluation of Patients With Prostate Cancer - PMC [pmc.ncbi.nlm.nih.gov]
- 16. Rib Fractures Mimicking Bone Metastases in 18F-PSMA-1007 PET/CT for Prostate Cancer - PubMed [pubmed.ncbi.nlm.nih.gov]
- To cite this document: BenchChem. [Technical Support Center: 18F-PSMA-1007 Uptake in Benign Lesions]. BenchChem, [2025]. [Online PDF]. Available at: [https://www.benchchem.com/product/b11934056#addressing-challenges-of-18f-psma-1007-uptake-in-benign-lesions]

---

### Disclaimer & Data Validity:

The information provided in this document is for Research Use Only (RUO) and is strictly not intended for diagnostic or therapeutic procedures. While BenchChem strives to provide accurate protocols, we make no warranties, express or implied, regarding the fitness of this product for every specific experimental setup.

**Technical Support:** The protocols provided are for reference purposes. Unsure if this reagent suits your experiment? [[Contact our Ph.D. Support Team for a compatibility check](#)]

**Need Industrial/Bulk Grade?** [Request Custom Synthesis Quote](#)

## BenchChem

Our mission is to be the trusted global source of essential and advanced chemicals, empowering scientists and researchers to drive progress in science and industry.

### Contact

Address: 3281 E Guasti Rd  
Ontario, CA 91761, United States  
Phone: (601) 213-4426  
Email: [info@benchchem.com](mailto:info@benchchem.com)

