

Suboptimal hepatobiliary phase enhancement with Eob-dtpa

Author: BenchChem Technical Support Team. **Date:** December 2025

Compound of Interest

Compound Name: Eob-dtpa

Cat. No.: B3021170

[Get Quote](#)

Technical Support Center: Gd-EOB-DTPA Enhanced MRI

Welcome to the technical support center for Gadolinium ethoxybenzyl diethylenetriamine pentaacetic acid (Gd-**EOB-DTPA**, Eovist®/Primovist®) enhanced Magnetic Resonance Imaging (MRI). This resource is designed for researchers, scientists, and drug development professionals to troubleshoot and optimize hepatobiliary phase (HBP) imaging.

Frequently Asked Questions (FAQs)

Q1: What are the primary causes of suboptimal hepatobiliary phase (HBP) enhancement?

A1: Suboptimal HBP enhancement can stem from two main categories of factors: patient-related physiological conditions and technical imaging parameters. Patient-related factors are primarily linked to liver function, as Gd-**EOB-DTPA** is taken up by functional hepatocytes.^{[1][2]} Key physiological causes include:

- **Impaired Liver Function:** Conditions such as cirrhosis or chronic liver disease reduce the number of functional hepatocytes available to uptake the contrast agent.^{[1][3]}
- **Elevated Bilirubin Levels:** Gd-**EOB-DTPA** and bilirubin compete for the same organic anion-transporting polypeptides (OATP1B1 and OATP1B3) for uptake into hepatocytes.^{[4][5][6]} Elevated serum bilirubin can significantly decrease hepatic enhancement.^{[1][4]}

- Biliary Obstruction: A blockage in the bile ducts can lead to reduced uptake and excretion of the contrast agent.[7]
- Drug-Induced Liver Injury (DILI): Certain drugs can inhibit the hepatobiliary transporters responsible for Gd-**EOB-DTPA** uptake and excretion.[5]

Technical factors that can be optimized include:

- Timing of HBP Acquisition: The standard 20-minute delay may be too short for patients with impaired liver function or too long for those with normal function.[2]
- Contrast Agent Injection Rate: The rate of injection can influence the quality of the dynamic phases, which can indirectly impact the overall study quality.[8][9]
- MRI Sequence Parameters: Factors like the flip angle can be adjusted to optimize signal in the HBP.[6]

Q2: How does serum bilirubin level quantitatively affect HBP enhancement?

A2: Serum total bilirubin is a strong predictor of suboptimal HBP image quality.[1][4] Gd-**EOB-DTPA** uptake is mediated by the same transporters as bilirubin, leading to competitive inhibition.[4][5] One study identified a total bilirubin cutoff value of 2.1 mg/dL as a predictor for low functional liver imaging score (FLIS), with high sensitivity and specificity.[4] Another study found that total bilirubin and albumin levels, when used in a machine learning model, could predict insufficient hepatic enhancement with high accuracy.[10]

Q3: What is the recommended timing for acquiring HBP images?

A3: The optimal timing for HBP imaging is not a one-size-fits-all parameter and should be adapted based on the patient's liver function.[2]

- Normal Liver Function: A 10 to 15-minute delay is often sufficient.[2][11] Some research indicates that in patients with normal liver function, optimal contrast-to-noise ratios are achieved at 10 minutes, with no significant improvement at 20 minutes.[11]
- Cirrhosis or Impaired Liver Function: The delay time may need to be extended to 20 or even 30 minutes to allow for adequate uptake of the contrast agent by the reduced mass of

functional hepatocytes.[2][12] In cases of severely impaired function, super delayed phase imaging (e.g., 60 minutes) might be beneficial.[13][14]

Q4: Can the injection protocol be modified to improve image quality?

A4: Yes, modifying the injection protocol can impact image quality, particularly for the arterial phase, which is crucial for characterizing hypervascular lesions.[9][15] Due to the smaller volume of Gd-**EOB-DTPA** administered compared to conventional extracellular agents, achieving optimal arterial enhancement can be challenging.[6][15] Studies have shown that a slower injection rate of 1 mL/s may provide better aortic enhancement in the arterial phase compared to a faster rate of 2 mL/s or 3 mL/s.[8][9]

Q5: What are some common artifacts or pitfalls to be aware of in HBP imaging?

A5: Several pitfalls can lead to misinterpretation of HBP images. Nontumorous lesions can appear hypointense, mimicking malignancy. These include:

- Focal Fat Deposition: Areas of steatosis may show reduced enhancement.[7]
- Confluent Fibrosis: Fibrotic tissue has decreased hepatocyte function and will appear hypointense.[16]
- Radiation-Induced Liver Injury: Areas of the liver that have undergone radiation therapy can exhibit hepatocyte dysfunction and subsequent hypointensity.[7]
- Bile Duct Obstruction: The affected liver segment can show diminished Gd-**EOB-DTPA** uptake.[7]
- Transient Tachypnea: A notable adverse reaction to Gd-**EOB-DTPA** is transient shortness of breath, which can cause motion artifacts during the critical arterial phase in about 10-15% of patients.[12][17][18]

Troubleshooting Guides

Issue 1: Poor or No Hepatic Parenchymal Enhancement in the HBP

This guide provides a systematic approach to troubleshooting insufficient liver enhancement.

Caption: Troubleshooting workflow for suboptimal HBP enhancement.

Data Summary Tables

Table 1: Patient Factors Correlated with Relative Liver Enhancement

Clinical Parameter	Correlation with HBP Enhancement	Significance (p-value)	Reference
Chronic Liver Disease	Negative	0.002	[1]
Total Bilirubin (T-Bil)	Negative	0.001	[1]
Albumin	Positive	0.001	[1]
Aspartate Aminotransferase (AST)	Negative	0.002	[1]
Prothrombin Activity	Positive	0.008	[1]
Child-Pugh Classification	Negative	Statistically Significant	[19]
Indocyanine Green (ICG) Test	Positive	Statistically Significant	[19]

Table 2: Recommended HBP Acquisition Timings

Patient Population	Recommended Delay Time (post-injection)	Rationale	Reference
Normal Liver Function	10 - 15 minutes	Sufficient time for uptake; avoids unnecessarily long scan times.	[2]
Known Cirrhosis	20 - 30 minutes	Allows more time for reduced functional hepatocyte mass to uptake the agent.	[2]
Biliary Obstruction / Severe Dysfunction	> 30 minutes (consider up to 60-120 min)	Maximizes the opportunity for any residual hepatocyte function to contribute to enhancement.	[6]

Experimental Protocols & Methodologies

Optimized Gd-EOB-DTPA Enhanced Liver MRI Protocol

This protocol is a general guideline and should be adapted based on available scanner hardware and institutional preferences.

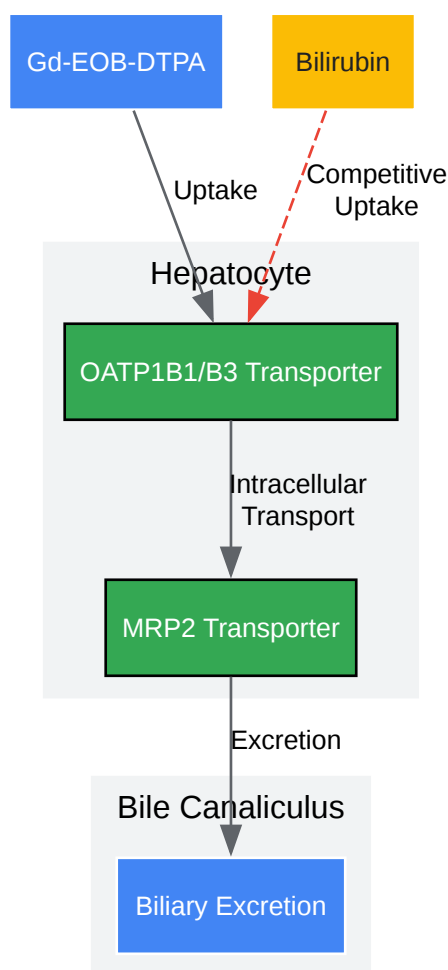
- Patient Preparation:
 - Patients should be NPO (nothing by mouth) for at least 4 hours prior to the exam to promote gallbladder filling and reduce bowel peristalsis.[17]
- Contrast Agent Administration:
 - Dose: 0.025 mmol/kg body weight (equivalent to 0.1 mL/kg).[6][19]
 - Injection Rate: 1-2 mL/s followed by a saline flush.[18] A slower rate of 1 mL/s is recommended to improve arterial phase quality.[9]

- MRI Sequences (Pre- and Post-Contrast):
 - Pre-contrast:
 - Axial T2-weighted single-shot fast spin-echo (SSFSE) with fat suppression.
 - Axial T1-weighted in-and-out-of-phase gradient echo (GRE).
 - Diffusion-Weighted Imaging (DWI) with b-values (e.g., 50, 400, 800 s/mm²) and ADC map.
 - Dynamic Post-contrast (3D T1-weighted GRE with fat suppression, e.g., VIBE, LAVA):
 - Late Arterial Phase: Timed with a bolus track or fixed delay (approx. 30-35 seconds post-injection).[\[12\]](#) Be aware of potential transient tachypnea which can cause motion artifacts.[\[15\]](#)[\[18\]](#)
 - Portal Venous Phase: Approximately 60-75 seconds post-injection.[\[12\]](#)[\[17\]](#)
 - Transitional Phase: Approximately 3 minutes post-injection.[\[12\]](#)
 - Hepatobiliary Phase (3D T1-weighted GRE with fat suppression):
 - Acquire at the individualized, appropriate delay time (see Table 2).[\[2\]](#)[\[12\]](#) This is a critical sequence; repeat if image quality is compromised by motion.[\[17\]](#)

Signaling Pathways and Workflows

Physiological Pathway of Gd-EOB-DTPA

This diagram illustrates the mechanism of uptake and excretion of Gd-**EOB-DTPA**, highlighting points where function can be impaired.



[Click to download full resolution via product page](#)

Caption: Gd-**EOB-DTPA** uptake and excretion pathway in hepatocytes.

Need Custom Synthesis?

BenchChem offers custom synthesis for rare earth carbides and specific isotopic labeling.

Email: info@benchchem.com or [Request Quote Online](#).

References

- 1. Potential clinical factors affecting hepatobiliary enhancement at Gd-EOB-DTPA-enhanced MR imaging - PubMed [pubmed.ncbi.nlm.nih.gov]

- 2. Optimization of hepatobiliary phase imaging in gadoxetic acid-enhanced magnetic resonance imaging: a narrative review - PMC [pmc.ncbi.nlm.nih.gov]
- 3. Gd-EOB-DTPA-enhanced MRI for the assessment of liver function and volume in liver cirrhosis - PMC [pmc.ncbi.nlm.nih.gov]
- 4. Total Bilirubin Level as a Predictor of Suboptimal Image Quality of the Hepatobiliary Phase of Gadoxetic Acid-Enhanced MRI in Patients with Extrahepatic Bile Duct Cancer - PMC [pmc.ncbi.nlm.nih.gov]
- 5. Assessment of gadoxetate DCE-MRI as a biomarker of hepatobiliary transporter inhibition - PMC [pmc.ncbi.nlm.nih.gov]
- 6. geiselmed.dartmouth.edu [geiselmed.dartmouth.edu]
- 7. Pitfalls in Gd-EOB-DTPA-Enhanced Liver Magnetic Resonance Imaging With an Emphasis on Nontumorous Lesions - PMC [pmc.ncbi.nlm.nih.gov]
- 8. Comparison of three different injection methods for arterial phase of Gd-EOB-DTPA enhanced MR imaging of the liver - PubMed [pubmed.ncbi.nlm.nih.gov]
- 9. Optimization of the dynamic, Gd-EOB-DTPA-enhanced MRI of the liver: the effect of the injection rate - PubMed [pubmed.ncbi.nlm.nih.gov]
- 10. Prediction of insufficient hepatic enhancement during the Hepatobiliary phase of Gd-EOB DTPA-enhanced MRI using machine learning classifier and feature selection algorithms - PubMed [pubmed.ncbi.nlm.nih.gov]
- 11. MR liver imaging with Gd-EOB-DTPA: a delay time of 10 minutes is sufficient for lesion characterisation - PMC [pmc.ncbi.nlm.nih.gov]
- 12. radiopaedia.org [radiopaedia.org]
- 13. [Optimal scan timing for Gd-EOB-DTPA enhanced liver dynamic MR imaging] - PubMed [pubmed.ncbi.nlm.nih.gov]
- 14. Super delayed phase imaging in gadoxetic acid-enhanced MRI: investigating factors contributing to improved liver contrast - PMC [pmc.ncbi.nlm.nih.gov]
- 15. Troubleshooting Arterial-Phase MR Images of Gadoxetate Disodium-Enhanced Liver - PMC [pmc.ncbi.nlm.nih.gov]
- 16. Focal hepatic lesions in Gd-EOB-DTPA enhanced MRI: the atlas - PMC [pmc.ncbi.nlm.nih.gov]
- 17. tranow.com [tranow.com]
- 18. mriquestions.com [mriquestions.com]

- 19. Liver parenchymal enhancement of hepatocyte-phase images in Gd-EOB-DTPA-enhanced MR imaging: which biological markers of the liver function affect the enhancement? - PubMed [pubmed.ncbi.nlm.nih.gov]
- To cite this document: BenchChem. [Suboptimal hepatobiliary phase enhancement with Eob-dtpa]. BenchChem, [2025]. [Online PDF]. Available at: [https://www.benchchem.com/product/b3021170#suboptimal-hepatobiliary-phase-enhancement-with-eob-dtpa]

Disclaimer & Data Validity:

The information provided in this document is for Research Use Only (RUO) and is strictly not intended for diagnostic or therapeutic procedures. While BenchChem strives to provide accurate protocols, we make no warranties, express or implied, regarding the fitness of this product for every specific experimental setup.

Technical Support: The protocols provided are for reference purposes. Unsure if this reagent suits your experiment? [[Contact our Ph.D. Support Team for a compatibility check](#)]

Need Industrial/Bulk Grade? [Request Custom Synthesis Quote](#)

BenchChem

Our mission is to be the trusted global source of essential and advanced chemicals, empowering scientists and researchers to drive progress in science and industry.

Contact

Address: 3281 E Guasti Rd
Ontario, CA 91761, United States
Phone: (601) 213-4426
Email: info@benchchem.com