

Strategies to reduce inflammation following a pars plana vitreous tap.

Author: BenchChem Technical Support Team. **Date:** December 2025

Compound of Interest

Compound Name: CP-67015

Cat. No.: B1669555

[Get Quote](#)

Technical Support Center: Ocular Research Division

Welcome to the Technical Support Center for Ocular Research. This resource provides troubleshooting guides and frequently asked questions (FAQs) for researchers, scientists, and drug development professionals utilizing pars plana vitreous tap in their experimental workflows. Our goal is to help you minimize and manage inflammation to ensure the integrity of your research specimens and the welfare of your animal models.

Frequently Asked Questions (FAQs)

Q1: What are the primary causes of inflammation following a pars plana vitreous tap?

A1: Inflammation after a pars plana vitreous tap is typically a result of mechanical disruption of the blood-ocular barrier and introduction of inflammatory mediators. Key causes include:

- **Mechanical Trauma:** The insertion of a needle or vitrectomy instrument through the conjunctiva, sclera, and vitreous can trigger a localized inflammatory cascade. This can activate resident immune cells and lead to the release of pro-inflammatory cytokines.
- **Hemorrhage:** Minor vitreous hemorrhage can occur during the procedure, and the presence of blood in the vitreous is a potent inflammatory stimulus.^[1]

- **Introduction of Contaminants:** Even with aseptic technique, there is a risk of introducing contaminants that can trigger an inflammatory response. This can range from sterile inflammation to infectious endophthalmitis.[2][3]
- **Underlying Ocular Conditions:** In animal models with pre-existing ocular disease, the inflammatory response to the procedure may be exaggerated.

Q2: How can I differentiate between sterile (non-infectious) and infectious inflammation post-procedure?

A2: Differentiating between sterile and infectious inflammation is critical for appropriate management. Key distinguishing features are summarized below:

Feature	Sterile Inflammation	Infectious Endophthalmitis
Onset	Typically rapid, often within 24-48 hours post-procedure.[4][5]	Generally slower, appearing 2-7 days post-procedure.[4]
Pain	Can range from none to moderate.	Often associated with significant and worsening pain.[4]
Clinical Signs	May present with anterior chamber reaction, vitritis (vitreous haze), and mild to moderate conjunctival injection. Hypopyon is less common.[3]	Often presents with severe conjunctival injection, chemosis, hypopyon, and dense vitritis, leading to a significant decrease in vision.[4]
Response to Corticosteroids	Typically responds well to topical or systemic corticosteroid therapy.	May show some initial response to steroids, but will ultimately worsen without appropriate antimicrobial treatment.
Vitreous Culture	Negative for microbial growth.[3]	Positive for bacteria or fungi. However, culture-negative endophthalmitis can occur.

If there is any doubt, it is crucial to manage the condition as infectious endophthalmitis until proven otherwise to prevent irreversible vision loss in the animal model.[3][4] This may involve performing a vitreous culture and administering broad-spectrum intravitreal antibiotics.[3]

Q3: What are the recommended needle gauges and insertion techniques to minimize trauma?

A3: To minimize mechanical trauma and subsequent inflammation, consider the following:

- **Needle Gauge:** Smaller gauge needles (e.g., 30-gauge or 32-gauge) are associated with less reflux of vitreous and potentially less trauma compared to larger needles like 27-gauge. [6]
- **Insertion Technique:** A beveled needle should be inserted through the pars plana, typically 3.5-4 mm posterior to the limbus. A tangential, tunneled scleral insertion is preferred to a perpendicular entry to promote self-sealing of the wound.
- **Automated Vitrectomy Cutter:** For larger volume vitreous sampling, a small-gauge (e.g., 25-gauge) vitrectomy cutter can be used. This may reduce vitreous traction compared to simple needle aspiration.[7]

Troubleshooting Guide

Observed Issue	Potential Cause	Recommended Action
Significant Vitreous Haze within 48 hours	Sterile inflammatory response, possibly due to excessive mechanical trauma or minor hemorrhage.	- Administer topical corticosteroids (e.g., dexamethasone 0.1% or prednisolone acetate 1%) or NSAIDs (e.g., ketorolac 0.5%).- For severe inflammation, consider a short course of systemic anti-inflammatory medication, consulting with a veterinarian.- Monitor for signs of infection.
Progressive Worsening of Inflammation after 48 hours with Hypopyon	High suspicion of infectious endophthalmitis.	- Immediately perform a vitreous tap for microbiological culture and sensitivity testing.- Administer broad-spectrum intravitreal antibiotics (e.g., vancomycin and ceftazidime). [3]- Consult with a veterinarian for systemic antibiotic therapy if indicated.
Intraoperative or Immediate Postoperative Vitreous Hemorrhage	Damage to a retinal or ciliary body blood vessel.	- If minor, it may resolve spontaneously. The inflammatory response to blood can be managed with corticosteroids.- For significant hemorrhage obscuring the fundus view, a follow-up pars plana vitrectomy may be necessary to clear the hemorrhage and prevent long-term complications like tractional retinal detachment. [1]

Elevated Intraocular Pressure (IOP)	Inflammation-induced trabeculitis, blockage of the trabecular meshwork by inflammatory cells or debris, or a response to corticosteroid treatment.	- Measure IOP regularly post-procedure.- Administer topical aqueous suppressants (e.g., beta-blockers or alpha-agonists).- If steroid-induced, consider switching to a less potent steroid or an NSAID for inflammation control.
-------------------------------------	--	--

Data on Anti-Inflammatory Strategies

The following tables summarize quantitative data on the efficacy of various anti-inflammatory agents in reducing ocular inflammation.

Table 1: Comparison of Postoperative Inflammation Control with Topical NSAIDs and Corticosteroids

Drug Class	Agent	Efficacy in Reducing Inflammation	IOP Effects	Reference
NSAID	Diclofenac	Equally effective as betamethasone in macular hole and epiretinal membrane surgery.	Better IOP control compared to betamethasone.	[8]
Corticosteroid	Betamethasone	Equally effective as diclofenac in macular hole and epiretinal membrane surgery.	Significantly higher postoperative IOP.	[8]

Table 2: Vitreous Concentrations of Topical NSAIDs

NSAID (Topical Administration)	Mean Vitreous Concentration (ng/mL)	Note	Reference
Indomethacin 0.5%	0.46	Higher concentrations in pseudophakic eyes.	[9]
Nepafenac 0.1%	0.29	Higher concentrations in pseudophakic eyes.	[9]
Bromfenac 0.09%	0.30	Higher concentrations in pseudophakic eyes.	[9]

Table 3: Efficacy of Intravitreal Dexamethasone Implant in Postoperative Macular Edema

Parameter	Before DEX Implant	1 Month After DEX Implant	p-value	Reference
Mean Visual Acuity (logMAR)	0.74 ± 0.34	Not specified	-	[10]
Mean Central Macular Thickness (μm)	608 ± 129	300 ± 90	< 0.01	[10]

Experimental Protocols

Protocol 1: Pars Plana Vitreous Tap via Needle Aspiration (Rodent Model)

- Anesthesia and Preparation:
 - Administer general anesthesia to the animal according to the institutionally approved protocol.
 - Apply a topical anesthetic (e.g., proparacaine hydrochloride 0.5%) to the ocular surface.
 - Disinfect the periocular area and conjunctival sac with a dilute povidone-iodine solution (e.g., 5%).

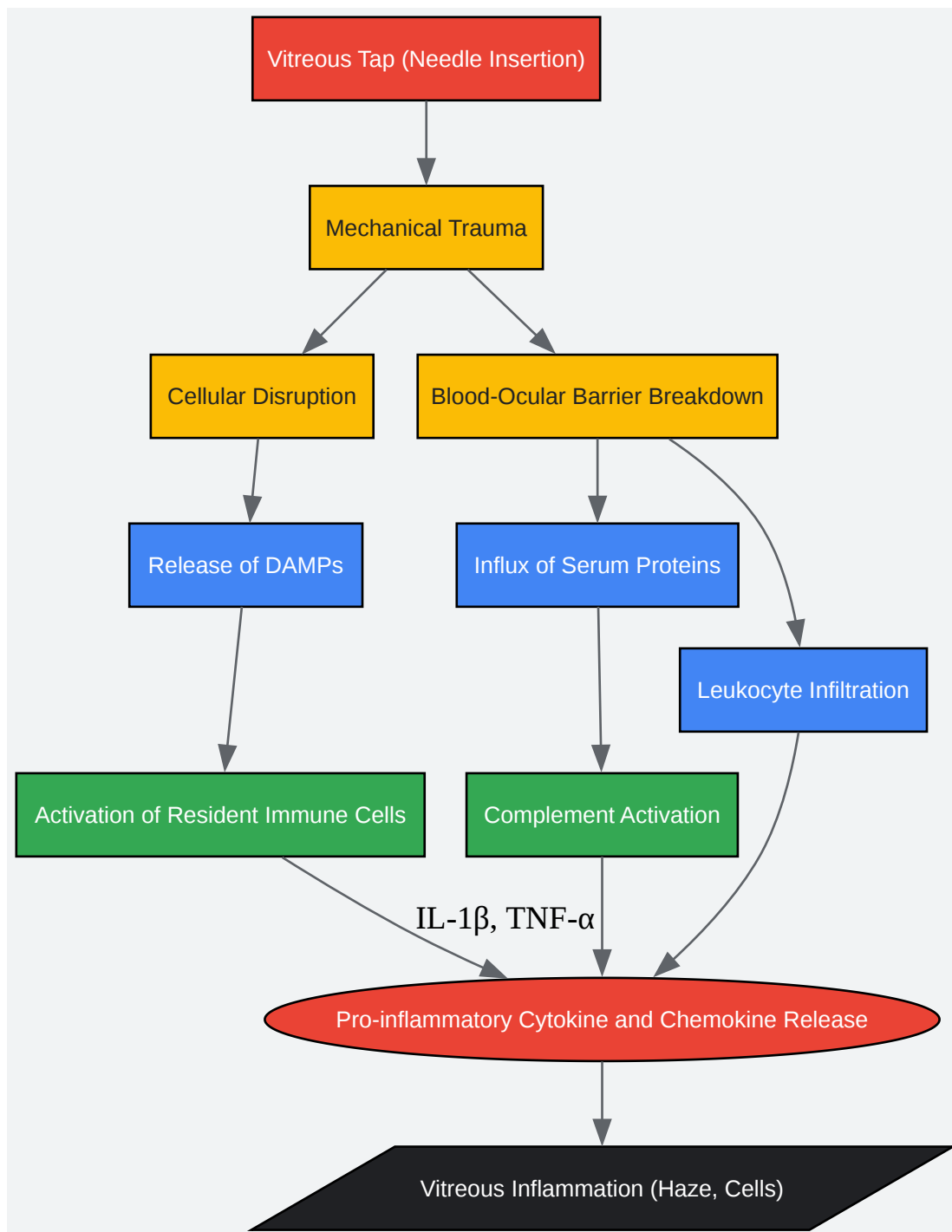
- Procedure:
 - Using a sterile 30-gauge or smaller needle attached to a 1 mL syringe, enter the eye through the pars plana (approximately 1-1.5 mm posterior to the limbus in a rodent).
 - Direct the needle posteriorly towards the optic nerve to avoid lens injury.
 - Gently aspirate 0.1-0.2 mL of vitreous humor.
 - Withdraw the needle and apply gentle pressure to the globe with a sterile cotton applicator to prevent leakage.
- Post-Procedure Care:
 - Apply a topical antibiotic ointment to the eye.
 - Monitor the animal for signs of pain or distress.
 - Administer prophylactic topical anti-inflammatory drops (corticosteroid or NSAID) as per the experimental design.

Protocol 2: Quantification of Vitreous Inflammatory Cells

- Sample Collection:
 - Collect vitreous humor as described in Protocol 1.
- Cell Counting:
 - Immediately after collection, dilute the vitreous sample with a suitable buffer (e.g., phosphate-buffered saline).
 - Use a hemocytometer to count the number of inflammatory cells (e.g., neutrophils, lymphocytes, macrophages) under a microscope.
 - Alternatively, use flow cytometry for more detailed cellular analysis and phenotyping.
- Data Analysis:

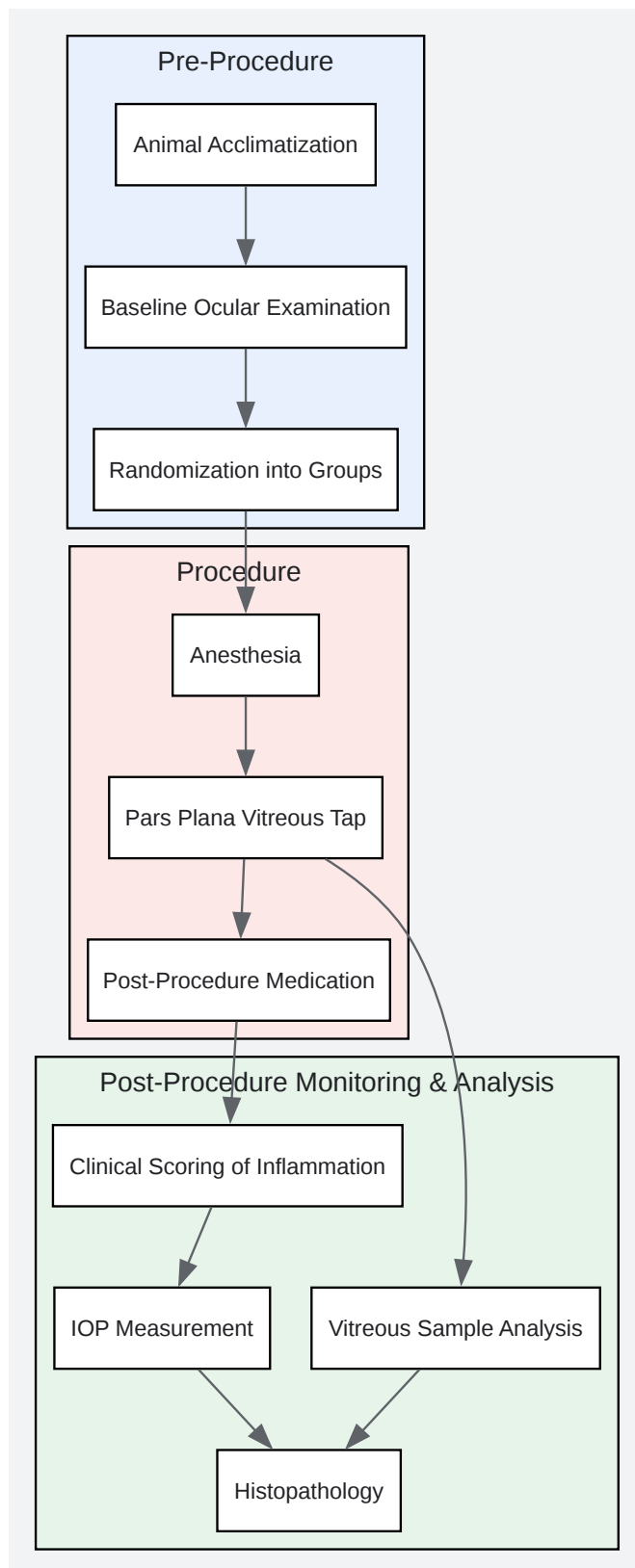
- Express the results as cells per microliter of vitreous humor.
- Compare cell counts between treatment and control groups.

Visualizations



[Click to download full resolution via product page](#)

Caption: Inflammatory cascade following a pars plana vitreous tap.



[Click to download full resolution via product page](#)

Caption: Experimental workflow for vitreous tap and inflammation analysis.

Need Custom Synthesis?

BenchChem offers custom synthesis for rare earth carbides and specific isotopic labeling.

Email: info@benchchem.com or [Request Quote Online](#).

References

- 1. Posterior perforating eye injury. Experimental animal model - PubMed [pubmed.ncbi.nlm.nih.gov]
- 2. discovery.ucl.ac.uk [discovery.ucl.ac.uk]
- 3. Sterile Endophthalmitis after Intravitreal Injections - PMC [pmc.ncbi.nlm.nih.gov]
- 4. Differential diagnosis of endophthalmitis after intravitreal drug injection for age related macular degeneration: sterile vs. infectious - PubMed [pubmed.ncbi.nlm.nih.gov]
- 5. researchgate.net [researchgate.net]
- 6. iovs.arvojournals.org [iovs.arvojournals.org]
- 7. changcataract.com [changcataract.com]
- 8. Intravitreal Devices for the Treatment of Vitreous Inflammation - PMC [pmc.ncbi.nlm.nih.gov]
- 9. tandfonline.com [tandfonline.com]
- 10. karger.com [karger.com]
- To cite this document: BenchChem. [Strategies to reduce inflammation following a pars plana vitreous tap.]. BenchChem, [2025]. [Online PDF]. Available at: [https://www.benchchem.com/product/b1669555#strategies-to-reduce-inflammation-following-a-pars-plana-vitreous-tap]

Disclaimer & Data Validity:

The information provided in this document is for Research Use Only (RUO) and is strictly not intended for diagnostic or therapeutic procedures. While BenchChem strives to provide accurate protocols, we make no warranties, express or implied, regarding the fitness of this product for every specific experimental setup.

Technical Support: The protocols provided are for reference purposes. Unsure if this reagent suits your experiment? [[Contact our Ph.D. Support Team for a compatibility check](#)]

Need Industrial/Bulk Grade? [Request Custom Synthesis Quote](#)

BenchChem

Our mission is to be the trusted global source of essential and advanced chemicals, empowering scientists and researchers to drive progress in science and industry.

Contact

Address: 3281 E Guasti Rd

Ontario, CA 91761, United States

Phone: (601) 213-4426

Email: info@benchchem.com