

Strategies to minimize hyperpigmentation after sodium morrhuate sclerotherapy.

Author: BenchChem Technical Support Team. **Date:** December 2025

Compound of Interest

Compound Name: Sodium Morrhuate

Cat. No.: B15560553

[Get Quote](#)

Technical Support Center: Sodium Morrhuate Sclerotherapy

This technical support guide provides researchers, scientists, and drug development professionals with strategies to minimize hyperpigmentation, a common adverse event following **sodium morrhuate** sclerotherapy.

Frequently Asked Questions (FAQs)

Q1: What is the underlying mechanism of hyperpigmentation after sodium morrhuate sclerotherapy?

Hyperpigmentation following sclerotherapy is primarily a result of hemosiderin deposition.^{[1][2][3]} The sclerosant, **sodium morrhuate**, induces endothelial damage, leading to the destruction of the vein.^{[1][3][4]} This process can cause erythrocytes (red blood cells) to extravasate into the surrounding dermal tissue.^{[4][5]} As these red blood cells break down, hemoglobin is released and subsequently degrades into hemosiderin, an iron-storage protein.^{[1][3]} This hemosiderin is then deposited in the dermis, causing a visible brown or discolored staining of the skin.^{[1][3]} Additionally, the inflammatory response triggered by the procedure can stimulate melanocytes, potentially contributing to increased melanin production and further darkening of the skin.^{[2][5][6]}

Q2: What procedural factors during sclerotherapy can influence the risk of hyperpigmentation?

Several in-procedure techniques can modulate the risk of developing hyperpigmentation:

- **Sclerosant Concentration and Volume:** Using high concentrations of the sclerosing agent or excessive plunger pressure can cause aggressive damage to the vein, increasing the likelihood of hyperpigmentation.[\[1\]](#)[\[2\]](#)
- **Injection Technique:** The experience level of the practitioner is crucial.[\[1\]](#)[\[2\]](#) Excessive injection pressure is associated with a higher risk of staining.[\[2\]](#)
- **Immediate Post-Injection Compression:** Applying manual compression to the vein immediately after injection can help close it and prevent it from refilling with blood, which avoids trapping blood that leads to hemosiderin staining.[\[1\]](#)
- **Thrombus Formation:** Sclerotherapy initiates local thrombus (clot) formation. If this clot is excessive, it can prolong inflammation and lead to hyperpigmentation as the clot extravasates and deposits iron into the tissues.[\[4\]](#)[\[5\]](#)

Q3: What are the key post-procedural strategies to minimize hyperpigmentation?

Post-procedural care is critical for minimizing the incidence and severity of hyperpigmentation.

- **Compression Therapy:** Consistent use of compression stockings is a primary strategy.[\[2\]](#)[\[7\]](#) [\[8\]](#) Compression minimizes the re-entry of blood into the treated vessel, improves venous flow, and reduces venous pressure, thereby decreasing red blood cell extravasation.[\[9\]](#)[\[10\]](#)
- **Sun Protection:** Strict avoidance of sun exposure and diligent use of high-SPF sunscreen (SPF 30+ indoors, SPF 50+ outdoors) is essential.[\[7\]](#)[\[8\]](#) UV radiation can exacerbate hyperpigmentation.[\[8\]](#)[\[11\]](#)
- **Topical Agents:** Several topical agents may aid in reducing pigmentation. These include Vitamin C, which has antioxidant properties, and other lightening agents like hydroquinone, kojic acid, and niacinamide that can inhibit melanin synthesis or transfer.[\[7\]](#)[\[8\]](#)[\[9\]](#)

- **Avoid Certain Medications and Supplements:** Patients should avoid non-steroidal anti-inflammatory drugs (NSAIDs) like ibuprofen, which can increase bruising.[9] It is also recommended to avoid supplemental iron, as hyperpigmentation is linked to iron in the blood.[10]

Q4: Are there any systemic treatments that can help prevent this complication?

Yes, research into systemic venoactive drugs has shown promise. A randomized clinical trial investigated the use of sulodexide, a venoactive drug, in reducing post-sclerotherapy hyperpigmentation. The study found that pre- and post-treatment with sulodexide significantly reduced the incidence and total area of hyperpigmentation compared to a standard protocol. [12][13]

Troubleshooting Guide

Issue: Hyperpigmentation has developed despite preventative measures.

Possible Causes and Solutions:

- **Inadequate Compression:**
 - **Troubleshooting:** Verify the compression class and duration of wear prescribed in the experimental protocol. A study demonstrated that extended compression can decrease hyperpigmentation rates.
 - **Recommendation:** Ensure consistent adherence to the compression schedule, typically for at least 7-14 days post-procedure.[9]
- **Excessive Thrombus Formation:**
 - **Troubleshooting:** Palpate the treated area for hard, tender spots which may indicate a trapped coagulum.[4] This is more frequent in larger treated vessels.[6]
 - **Recommendation:** Consider a follow-up appointment approximately two weeks post-procedure to perform a microthrombectomy. This involves using a needle to release the

trapped thrombus, which can reduce inflammation and subsequent staining.[4]

- Underlying Venous Reflux:
 - Troubleshooting: If hyperpigmentation is persistent or severe, it may indicate untreated underlying venous reflux, where pressure from deeper veins pushes blood into superficial vessels.[2] This can lead to persistent leakage of red blood cells.
 - Recommendation: A thorough assessment with duplex ultrasound is required to identify and treat any sources of venous reflux.[1]
- Patient-Specific Factors:
 - Troubleshooting: Certain factors increase risk, such as darker skin types (which may have more reactive melanocytes) and the use of specific medications like Minocycline.[2][3]
 - Recommendation: For persistent pigmentation, advanced dermatological treatments may be considered. These include topical lightening agents, chemical peels (e.g., salicylic or glycolic acid), and light-based therapies like Q-switched lasers (650nm, 694nm, or 755nm) which are effective at targeting hemosiderin pigment.[2][9][10][14]

Data & Protocols

Quantitative Data Summary

The following tables summarize data on the incidence of hyperpigmentation and the efficacy of preventative strategies from cited literature.

Table 1: Incidence of Post-Sclerotherapy Hyperpigmentation

Sclerosing Agent	Reported Incidence Rate	Persistence > 1 Year	Source
General Sclerotherapy	10% - 30%	~10%	[6]
Polidocanol	7.4% - 32.5%	Up to 17.5% (foam)	[15]
Sodium Tetradecyl Sulfate (STS)	11% - 80%	1% - 2%	[16]
All Agents (General)	9% - 30%	~1% (permanent)	[10]

Table 2: Efficacy of Sulodexide in Preventing Hyperpigmentation

Group	Treatment Protocol	Incidence of Hyperpigmentation (1 Month)	Average Area of Hyperpigmentation	Source
Group A	Sulodexide (oral, twice daily) 7 days pre-procedure, continued for 3 months + Standard Protocol	8.7%	10.7%	[12] [13]
Group B	Standard Protocol only	14.8%	18.2%	[12] [13]

*Standard Protocol: Sclerotherapy with polidocanol followed by 20-30 mmHg compression stockings for 7 days.[\[12\]](#)[\[13\]](#)

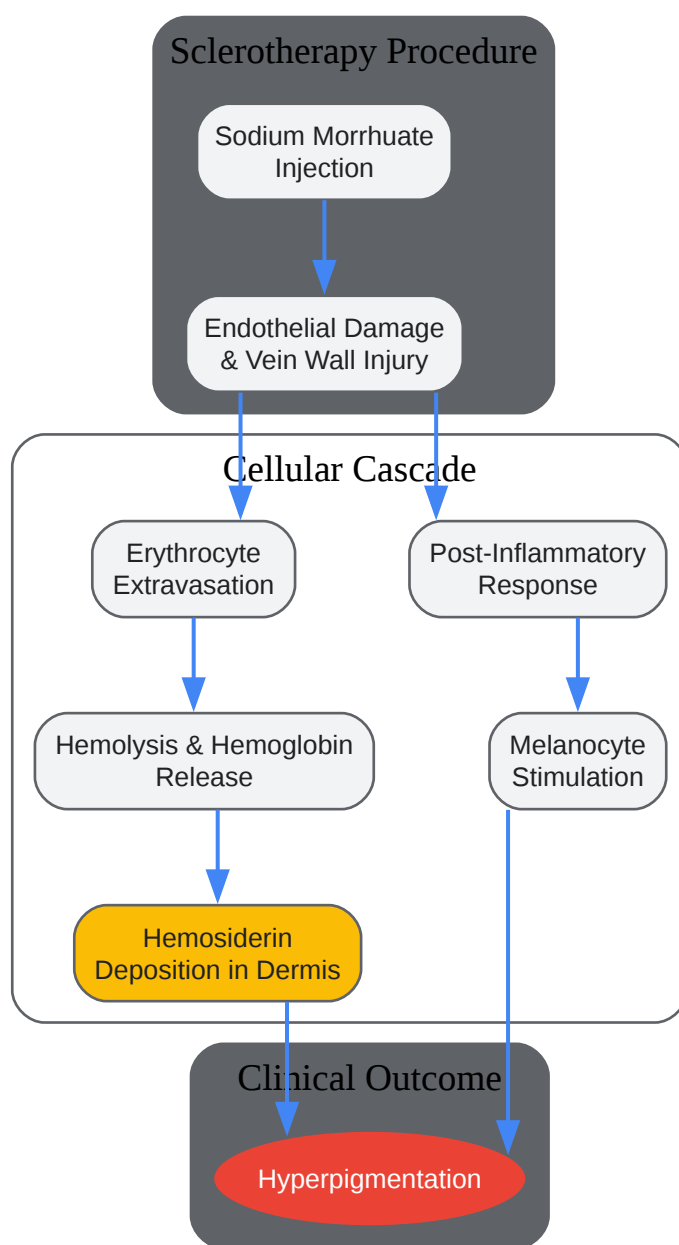
Experimental Protocols

Protocol 1: Clinical Trial of Sulodexide for Hyperpigmentation Prevention

- Objective: To evaluate if the addition of sulodexide to a standard sclerotherapy protocol reduces the occurrence of post-sclerotherapy hyperpigmentation.[12][13]
- Study Design: Prospective, multicenter, randomized controlled trial.[12][13]
- Participants: Patients with telangiectasia, reticular veins, or varicose veins. Exclusion criteria included reflux in the deep system or saphenous veins.[12][13]
- Methodology:
 - Randomization: Patients were randomized into two parallel groups.
 - Group A (Treatment): Received an oral dose of sulodexide twice daily, starting 7 days before the scheduled sclerotherapy and continuing for 3 months post-procedure.[12]
 - Group B (Control): Received only the standard sclerotherapy protocol.[12]
 - Sclerotherapy Procedure: Polidocanol was used as the sclerosing agent for all patients. [12][13]
 - Post-Procedure Care: All patients in both groups used 20-30 mmHg compression stockings for 7 days following the procedure.[12][13]
 - Follow-up & Analysis: Control photographs were taken before treatment. Follow-up examinations occurred at 1 and 3 months. A computerized analysis was used to measure the incidence of hyperpigmentation, the total area of hyperpigmentation, and changes in skin tone.[12][13]
- Reference: Gonzalez Ochoa AJ, et al. J Vasc Surg Venous Lymphat Disord. 2021.[12]

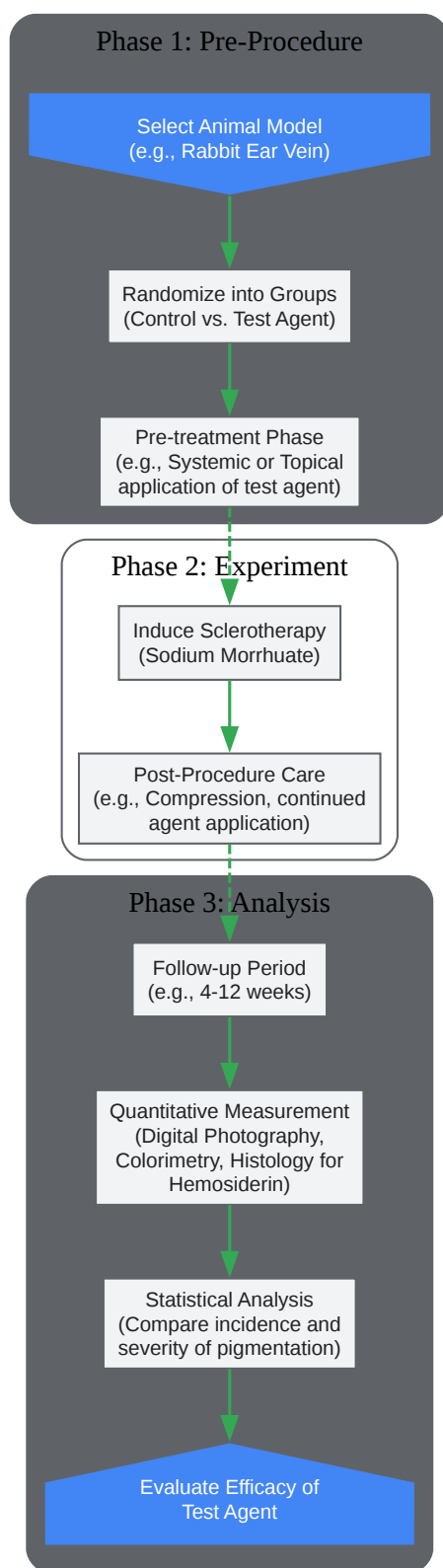
Visualizations

Signaling & Experimental Workflow Diagrams



[Click to download full resolution via product page](#)

Caption: Pathophysiological pathway of post-sclerotherapy hyperpigmentation.



[Click to download full resolution via product page](#)

Caption: Pre-clinical experimental workflow for testing a novel agent.

Need Custom Synthesis?

BenchChem offers custom synthesis for rare earth carbides and specific isotopic labeling.

Email: info@benchchem.com or [Request Quote Online](#).

References

- 1. veinhealth.com.au [veinhealth.com.au]
- 2. melbournelegveincentre.com.au [melbournelegveincentre.com.au]
- 3. How to Get Rid of Brown Marks After Sclerotherapy? - Aakash Healthcare [aakashhealthcare.com]
- 4. How to Avoid Brown Marks and Staining After Sclerotherapy | A Guide for Healthcare Professionals [veincare.academy]
- 5. Brown Marks [veincare.academy]
- 6. How to manage complications after sclerotherapy - Servier - Phlebolympology Servier – Phlebolympology [phlebolympology.org]
- 7. Battling Brown Spots: Your Guide to Hyperpigmentation After Foam Sclerotherapy — Dream Vein Clinic [dreamvein.com]
- 8. health.veininstitutenj.com [health.veininstitutenj.com]
- 9. Post-Sclerotherapy Skin Discoloration: Treatment Options | Authentic K-Beauty | Fast Worldwide Shipping [koreancosmetics.cy]
- 10. veininstitutejax.com [veininstitutejax.com]
- 11. venasmart.com [venasmart.com]
- 12. Reducing hyperpigmentation after sclerotherapy: A randomized clinical trial - PubMed [pubmed.ncbi.nlm.nih.gov]
- 13. researchgate.net [researchgate.net]
- 14. veincenter.doctor [veincenter.doctor]
- 15. Combined Laser Therapy for Post-sclerotherapy Hyperpigmentation Following Nicolau Syndrome: A Case Report - PMC [pmc.ncbi.nlm.nih.gov]
- 16. Complications and Adverse Sequelae of Sclerotherapy | Plastic Surgery Key [plasticsurgerykey.com]

- To cite this document: BenchChem. [Strategies to minimize hyperpigmentation after sodium morrhuate sclerotherapy.]. BenchChem, [2025]. [Online PDF]. Available at: [https://www.benchchem.com/product/b15560553#strategies-to-minimize-hyperpigmentation-after-sodium-morrhuate-sclerotherapy]

Disclaimer & Data Validity:

The information provided in this document is for Research Use Only (RUO) and is strictly not intended for diagnostic or therapeutic procedures. While BenchChem strives to provide accurate protocols, we make no warranties, express or implied, regarding the fitness of this product for every specific experimental setup.

Technical Support: The protocols provided are for reference purposes. Unsure if this reagent suits your experiment? [[Contact our Ph.D. Support Team for a compatibility check](#)]

Need Industrial/Bulk Grade? [Request Custom Synthesis Quote](#)

BenchChem

Our mission is to be the trusted global source of essential and advanced chemicals, empowering scientists and researchers to drive progress in science and industry.

Contact

Address: 3281 E Guasti Rd
Ontario, CA 91761, United States
Phone: (601) 213-4426
Email: info@benchchem.com