

Stannous Pyrophosphate in the Spotlight: A Comparative Guide to Detecting Acute Myocardial Infarction

Author: BenchChem Technical Support Team. **Date:** December 2025

Compound of Interest

Compound Name: Stannous pyrophosphate

Cat. No.: B129299

[Get Quote](#)

For researchers, scientists, and drug development professionals, this guide offers an objective comparison of **stannous pyrophosphate**'s efficacy in detecting acute myocardial infarction (AMI) against other established imaging modalities. Supported by experimental data, this document provides a comprehensive overview to inform research and development in cardiac imaging.

The timely and accurate diagnosis of acute myocardial infarction is critical for patient outcomes. While various imaging techniques exist, radiopharmaceuticals that directly target necrotic tissue, such as Technetium-99m (^{99m}Tc) **stannous pyrophosphate**, have historically played a significant role. This guide delves into the performance of ^{99m}Tc -pyrophosphate and compares it with other imaging agents and modalities, providing a clear perspective on its relative strengths and limitations.

Comparative Efficacy of Imaging Modalities for AMI Detection

The diagnostic performance of an imaging agent is primarily assessed by its sensitivity and specificity. The following table summarizes the quantitative data for ^{99m}Tc -pyrophosphate and its alternatives in the context of AMI detection.

Imaging Modality	Radiopharmaceutical/Method	Sensitivity	Specificity	Optimal Imaging Time Post-Symptom Onset
Scintigraphy	Technetium-99m Pyrophosphate (^{99m} Tc-PYP)	73% (early, 4-8 hrs) to 95% (24-72 hrs)	68% - 97%	24-72 hours
Thallium-201 (²⁰¹ Tl)	~95% (transmural & non-transmural)	-	Within 6 hours	
Technetium-99m Glucoheptonate	80% (moderate to large infarcts)	-	2-48 hours	
Gallium-67 Citrate	Primarily for myocarditis, low sensitivity for AMI	High for differentiating myocarditis from AMI	48-72 hours	
Cardiac MRI	Late Gadolinium Enhancement (LGE)	High (considered gold standard)	High	Acute phase (first 7 days)
Echocardiography	Regional Wall Motion Abnormalities	>90% correlation with histologic evidence	-	Immediate

Experimental Protocols: A Closer Look at the Methodologies

Detailed experimental protocols are crucial for the replication and validation of research findings. Below are the methodologies for key imaging techniques discussed.

Technetium-99m Pyrophosphate (^{99m}Tc-PYP) Scintigraphy

- Patient Preparation: No specific preparation, such as fasting, is required.

- **Radiopharmaceutical Administration:** An intravenous injection of 15 mCi of ^{99m}Tc -pyrophosphate is administered. It is crucial to ensure good binding of ^{99m}Tc to pyrophosphate to avoid free pertechnetate in the blood pool, which can obscure images.
- **Imaging Acquisition:**
 - Imaging commences 2-3 hours after injection.
 - A scintillation camera equipped with a parallel-hole, low-energy, medium-sensitivity collimator is used.
 - The pulse height spectrometer is set with a 20% window centered around the 140-keV photopeak.
 - Images (anterior, left anterior oblique, and lateral views) are acquired for at least 400,000 counts for a standard field of view camera.
- **Image Interpretation:** Images are typically graded on a scale of 0 to 4+ based on the intensity of radioactivity in the heart region. A positive scan shows focal uptake of the tracer in the infarcted myocardium.

Thallium-201 (^{201}Tl) Myocardial Perfusion Imaging

- **Patient Preparation:** The patient should be fasting.
- **Radiopharmaceutical Administration:** An intravenous injection of 3 to 4 mCi of ^{201}Tl is administered at rest.
- **Imaging Acquisition:**
 - Imaging begins 10 to 15 minutes after injection.
 - Delayed imaging at 2-4 hours can help differentiate between ischemia and infarction.
- **Image Interpretation:** An area of acute myocardial infarction appears as a "cold spot" or a perfusion defect due to the lack of tracer uptake in the non-viable tissue.

Cardiac Magnetic Resonance Imaging (CMR) with Late Gadolinium Enhancement (LGE)

- Patient Preparation: A serum creatinine level should be checked to ensure a glomerular filtration rate > 30 ml/min before gadolinium injection.
- Image Acquisition Protocol:
 - Initial Scans: T2-weighted imaging is performed to detect myocardial edema, which is indicative of an acute injury.
 - Contrast Administration: A gadolinium-based contrast agent is injected intravenously.
 - Late Gadolinium Enhancement (LGE) Imaging: LGE sequences are acquired 10-15 minutes after the contrast injection.
- Image Interpretation: In an acute MI, the infarcted tissue with damaged cell membranes allows gadolinium to accumulate in the extracellular space, appearing as a bright (hyperenhanced) area on LGE images. The pattern of enhancement (subendocardial or transmural) provides information about the extent of the infarction.

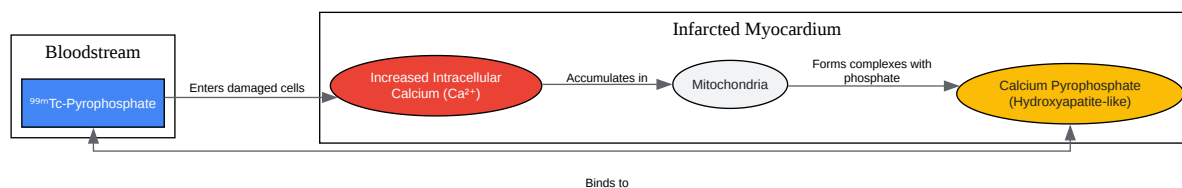
Echocardiography

- Patient Preparation: No specific preparation is needed.
- Image Acquisition: A transthoracic echocardiogram (TTE) is performed using standard cardiac windows (parasternal, apical, subcostal).
- Image Interpretation: The primary indicator of AMI is the presence of regional wall motion abnormalities (RWMA), such as hypokinesis (reduced movement), akinesis (no movement), or dyskinesis (paradoxical movement), in the affected myocardial segments. The preservation of normal wall thickness suggests an acute event.

Visualizing the Pathways and Workflows

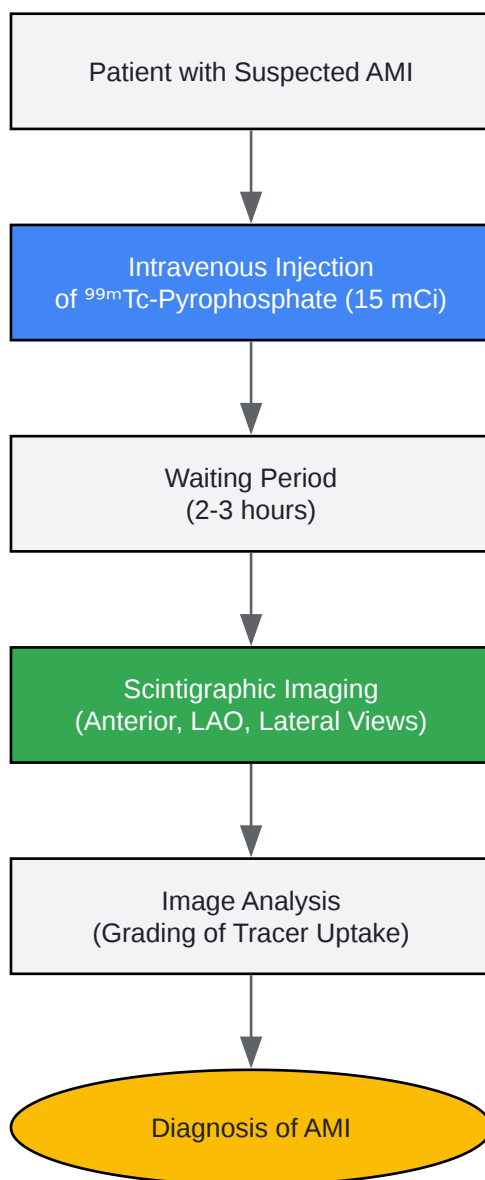
To better illustrate the processes involved, the following diagrams, created using the DOT language, depict the signaling pathway of ^{99m}Tc-pyrophosphate uptake and the general

experimental workflow for its use in AMI detection.



[Click to download full resolution via product page](#)

Caption: Mechanism of ^{99m}Tc -Pyrophosphate uptake in infarcted myocardium.



[Click to download full resolution via product page](#)

Caption: Experimental workflow for AMI detection using ^{99m}Tc -Pyrophosphate.

- To cite this document: BenchChem. [Stannous Pyrophosphate in the Spotlight: A Comparative Guide to Detecting Acute Myocardial Infarction]. BenchChem, [2025]. [Online PDF]. Available at: [<https://www.benchchem.com/product/b129299#efficacy-of-stannous-pyrophosphate-in-detecting-acute-myocardial-infarction>]

Disclaimer & Data Validity:

The information provided in this document is for Research Use Only (RUO) and is strictly not intended for diagnostic or therapeutic procedures. While BenchChem strives to provide accurate protocols, we make no warranties, express or implied, regarding the fitness of this product for every specific experimental setup.

Technical Support: The protocols provided are for reference purposes. Unsure if this reagent suits your experiment? [[Contact our Ph.D. Support Team for a compatibility check](#)]

Need Industrial/Bulk Grade? [Request Custom Synthesis Quote](#)

BenchChem

Our mission is to be the trusted global source of essential and advanced chemicals, empowering scientists and researchers to drive progress in science and industry.

Contact

Address: 3281 E Guasti Rd
Ontario, CA 91761, United States
Phone: (601) 213-4426
Email: info@benchchem.com