

Pyomyositis vs. Polymyositis: A Histopathological and Molecular Showdown

Author: BenchChem Technical Support Team. **Date:** December 2025

Compound of Interest

Compound Name: *Piomy*

Cat. No.: *B1172056*

[Get Quote](#)

For Immediate Release:

[City, State] – [Date] – Researchers and drug development professionals now have access to a comprehensive comparative guide detailing the critical histopathological and molecular distinctions between pyomyositis and polymyositis. This guide provides an in-depth analysis of their differing pathological features, experimental evaluation protocols, and underlying signaling pathways, offering a valuable resource for advancing diagnostic and therapeutic strategies.

Pyomyositis, a bacterial infection of skeletal muscle, and polymyositis, an autoimmune inflammatory myopathy, can present with overlapping clinical features, making accurate diagnosis challenging. This guide elucidates the key microscopic and molecular differences that are paramount for differential diagnosis and the development of targeted therapies.

Comparative Histopathological Analysis

A detailed examination of muscle biopsy specimens reveals distinct histopathological hallmarks for each condition. Pyomyositis is fundamentally a suppurative process, characterized by a robust neutrophilic infiltrate and abscess formation. In contrast, polymyositis is defined by a cell-mediated autoimmune attack on muscle fibers, with a predominantly lymphocytic infiltrate.

Feature	Pyomyositis	Polymyositis
Primary Inflammatory Infiltrate	Neutrophil-rich[1]	Mononuclear cells (CD8+ T lymphocytes and macrophages)[1][2]
Location of Infiltrate	Interstitial and perivascular, progressing to widespread suppuration	Primarily endomysial, surrounding and invading individual muscle fibers[1][2]
Muscle Fiber Necrosis	Coagulative necrosis, often extensive within abscess cavities	Segmental necrosis of muscle fibers invaded by inflammatory cells[1]
Muscle Fiber Regeneration	Present at the periphery of abscesses	Scattered regenerating fibers are common[1]
Abscess Formation	Hallmark feature, with collections of pus[3]	Absent
Fibrosis	Can occur as a late-stage healing response	Interstitial and endomysial fibrosis can develop in chronic stages
Causative Agent	Primarily bacterial (most commonly Staphylococcus aureus)[3][4][5]	Autoimmune

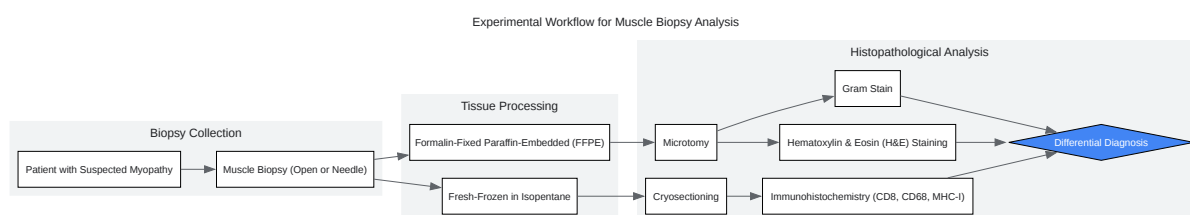
Experimental Protocols

The definitive diagnosis of pyomyositis and polymyositis heavily relies on the histopathological examination of a muscle biopsy. The following is a generalized protocol for the collection and analysis of muscle tissue.

Muscle Biopsy and Histopathological Staining

- **Biopsy Collection:** An open or needle biopsy of an affected muscle is performed under sterile conditions. For polymyositis, the biopsy site may be guided by magnetic resonance imaging (MRI) to target areas of inflammation.

- **Tissue Processing:** The muscle tissue is divided for different analyses. A portion is fresh-frozen in isopentane cooled by liquid nitrogen for cryosectioning and histochemical and immunohistochemical staining. Another portion is fixed in formalin and embedded in paraffin for routine hematoxylin and eosin (H&E) staining.
- **Histological Staining:**
 - **Hematoxylin and Eosin (H&E):** Provides an overview of the tissue architecture, inflammatory infiltrates, and muscle fiber morphology.
 - **Gram Stain:** Used to identify bacteria within the tissue, a key diagnostic feature of pyomyositis.
 - **Immunohistochemistry:** Utilizes specific antibodies to identify the types of inflammatory cells present. Key markers include CD8 for cytotoxic T cells and CD68 for macrophages in polymyositis, and markers for neutrophils in pyomyositis. Major Histocompatibility Complex (MHC) class I staining is also crucial, as its upregulation on the surface of muscle fibers is a characteristic feature of polymyositis.



[Click to download full resolution via product page](#)

Experimental workflow for muscle biopsy analysis.

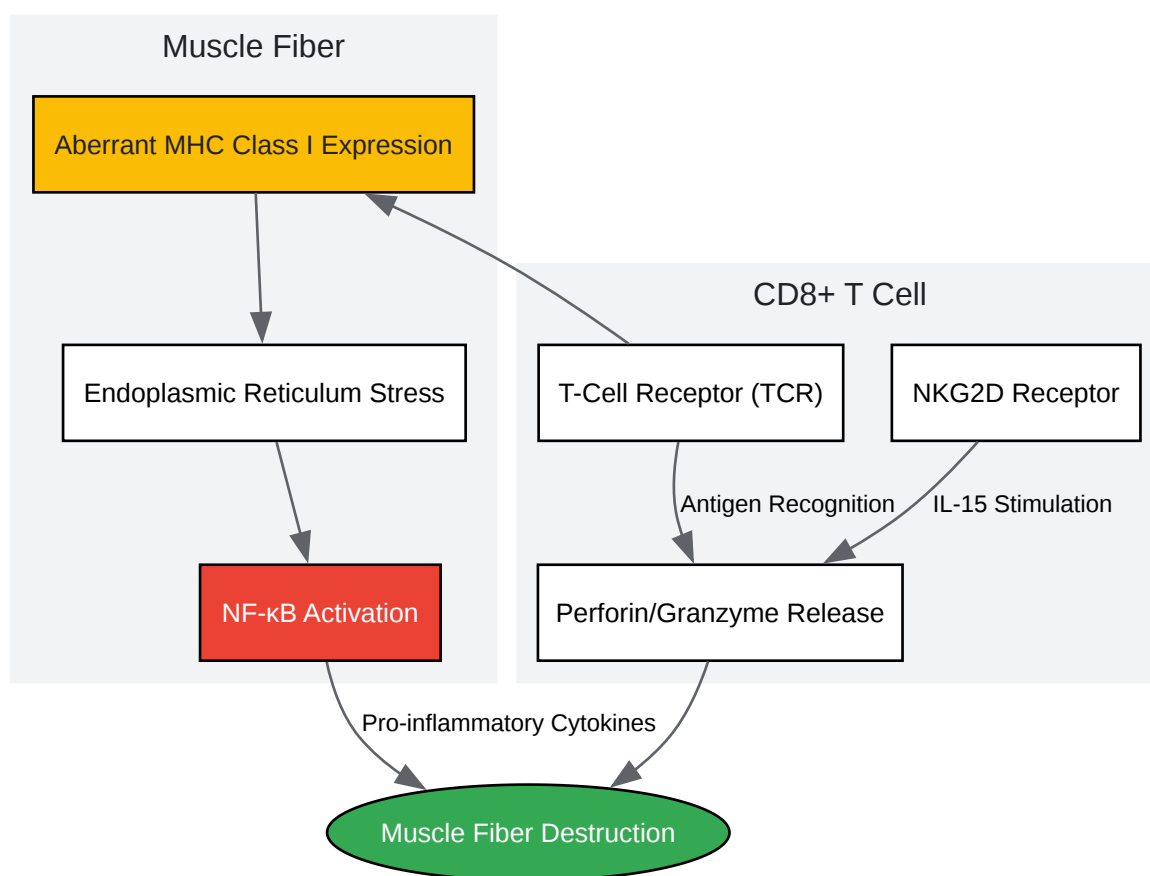
Signaling Pathways in Pathogenesis

The underlying molecular mechanisms driving pyomyositis and polymyositis are fundamentally different, reflecting their infectious versus autoimmune etiologies.

Polymyositis: A T-Cell Mediated Autoimmune Response

In polymyositis, the pathogenesis is driven by a cytotoxic T-cell response against muscle antigens. A key initiating event is the aberrant expression of MHC class I molecules on the surface of muscle fibers. This leads to the recognition of muscle fibers as "foreign" by CD8+ cytotoxic T lymphocytes. This process is associated with endoplasmic reticulum stress and the activation of the pro-inflammatory transcription factor NF- κ B. The NKG2D-IL-15 signaling pathway also plays a role in the T-cell mediated destruction of muscle tissue.

Signaling Pathway in Polymyositis



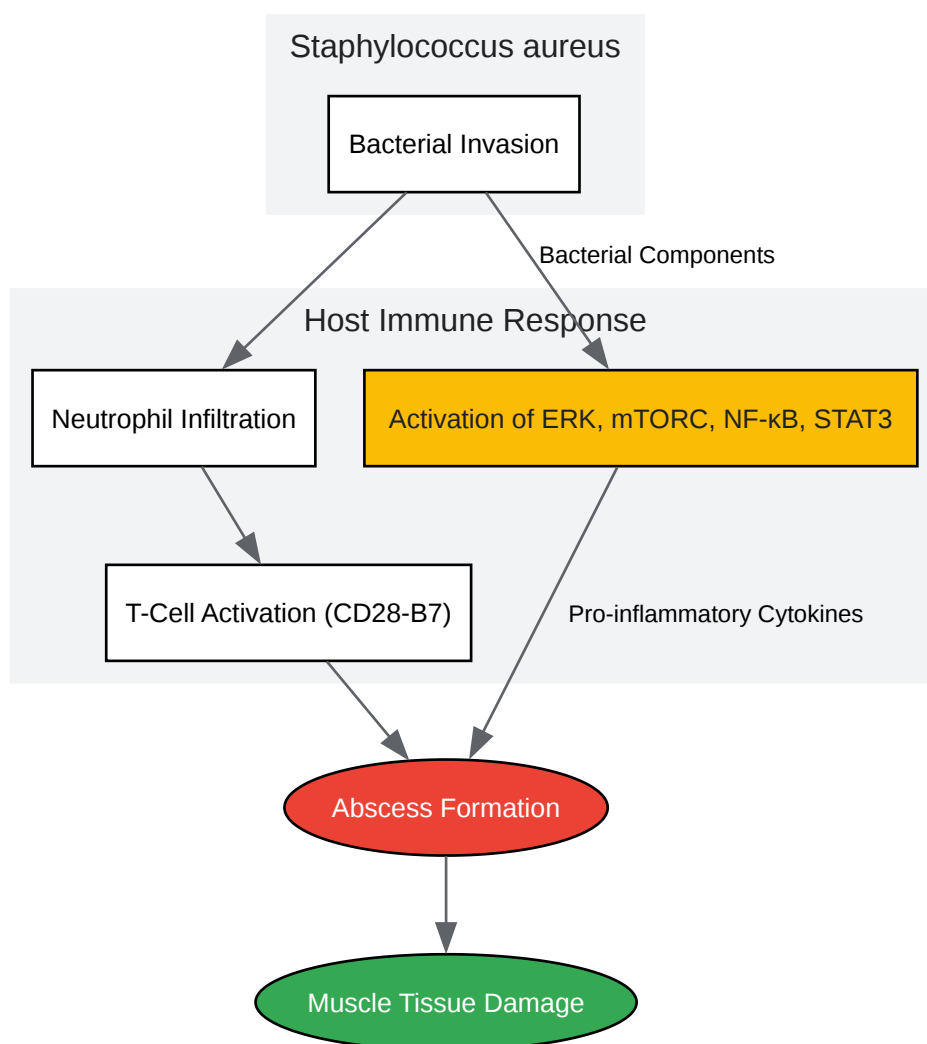
[Click to download full resolution via product page](#)

T-cell mediated cytotoxicity in polymyositis.

Pyomyositis: Bacterial Invasion and Abscess Formation

The pathogenesis of pyomyositis begins with the entry of bacteria, most commonly *Staphylococcus aureus*, into the muscle tissue, often following minor trauma. The bacteria trigger an acute inflammatory response, characterized by the influx of neutrophils. Bacterial components are recognized by host immune cells, leading to the activation of various signaling pathways, including ERK, mTORC, NF- κ B, and STAT3. Abscess formation is a key feature and is modulated by T-cell activation through the CD28-B7 costimulatory pathway.

Signaling Pathway in Pyomyositis



[Click to download full resolution via product page](#)

Bacterial-induced inflammation in pyomyositis.

This comparative guide underscores the necessity of a multi-faceted approach, combining clinical evaluation with detailed histopathological and molecular analysis, for the accurate diagnosis and management of pyomyositis and polymyositis. A deeper understanding of their distinct pathogenic pathways is crucial for the development of novel, targeted therapeutic interventions.

Need Custom Synthesis?

BenchChem offers custom synthesis for rare earth carbides and specific isotopic labeling.

Email: info@benchchem.com or [Request Quote Online](#).

References

- 1. Mechanisms of disease: signaling pathways and immunobiology of inflammatory myopathies - PubMed [pubmed.ncbi.nlm.nih.gov]
- 2. my.clevelandclinic.org [my.clevelandclinic.org]
- 3. Polymyositis and Dermatomyositis: Pathophysiology | Musculoskeletal Key [musculoskeletalkey.com]
- 4. The NKG2D – IL-15 signaling pathway contributes to T-cell mediated pathology in inflammatory myopathies - PMC [pmc.ncbi.nlm.nih.gov]
- 5. Activation of nuclear factor-kappaB in inflammatory myopathies and Duchenne muscular dystrophy - PubMed [pubmed.ncbi.nlm.nih.gov]
- To cite this document: BenchChem. [Pyomyositis vs. Polymyositis: A Histopathological and Molecular Showdown]. BenchChem, [2025]. [Online PDF]. Available at: [https://www.benchchem.com/product/b1172056#pyomyositis-vs-polymyositis-a-comparative-histopathological-analysis]

Disclaimer & Data Validity:

The information provided in this document is for Research Use Only (RUO) and is strictly not intended for diagnostic or therapeutic procedures. While BenchChem strives to provide accurate protocols, we make no warranties, express or implied, regarding the fitness of this product for every specific experimental setup.

Technical Support: The protocols provided are for reference purposes. Unsure if this reagent suits your experiment? [[Contact our Ph.D. Support Team for a compatibility check](#)]

Need Industrial/Bulk Grade? [Request Custom Synthesis Quote](#)

BenchChem

Our mission is to be the trusted global source of essential and advanced chemicals, empowering scientists and researchers to drive progress in science and industry.

Contact

Address: 3281 E Guasti Rd

Ontario, CA 91761, United States

Phone: (601) 213-4426

Email: info@benchchem.com