

Pyomyositis and its association with HIV infection

Author: BenchChem Technical Support Team. **Date:** December 2025

Compound of Interest

Compound Name: *Piomy*

Cat. No.: *B1172056*

[Get Quote](#)

An In-depth Technical Guide: Pyomyositis and its Association with HIV Infection

Prepared for: Researchers, Scientists, and Drug Development Professionals

Abstract

Pyomyositis, a primary bacterial infection of skeletal muscle, has emerged from a tropical curiosity to a significant opportunistic infection in immunocompromised individuals, particularly those with Human Immunodeficiency Virus (HIV) infection.[1][2] While *Staphylococcus aureus* remains the predominant causative agent, the clinical presentation, pathogenesis, and management of pyomyositis in the context of HIV are altered by the underlying immunodeficiency.[3][4] This guide provides a comprehensive technical overview of HIV-associated pyomyositis, focusing on the pathophysiological mechanisms, diagnostic and therapeutic protocols, and quantitative clinical data. It aims to serve as a resource for researchers and professionals engaged in understanding infectious disease pathogenesis and developing novel therapeutic strategies. Key findings indicate that HIV-positive patients with pyomyositis often present with advanced immunosuppression, characterized by low CD4+ cell counts, and may lack typical inflammatory responses like leukocytosis.[4][5][6] The pathogenesis is multifactorial, involving defects in neutrophil function, increased colonization by pathogens, and potential preceding muscle injury.[3][4] Management necessitates a dual approach of targeted antimicrobial therapy, often combined with surgical drainage, and the crucial implementation of highly active antiretroviral therapy (HAART).[5]

Introduction

Pyomyositis is characterized by the formation of purulent abscesses within large skeletal muscle groups.[7] Historically known as "tropical pyomyositis," its incidence in temperate climates has risen in parallel with the increasing prevalence of immunocompromised states, most notably HIV infection.[1][8] The association between HIV and pyomyositis is significant; HIV infection predisposes patients to this severe bacterial complication.[2] In this population, the disease can follow an insidious course, presenting diagnostic challenges and leading to significant morbidity if not promptly recognized and treated.[4][9] Understanding the unique interplay between HIV-induced immune dysregulation and bacterial muscle invasion is critical for the development of effective diagnostics and therapeutics.

Epidemiology and Risk Factors

While pyomyositis is rare in the general population in North America, HIV infection is a major predisposing factor.[2] The development of pyomyositis in HIV-infected individuals often signals advanced disease and severe immunosuppression.[5][9]

- **Immunosuppression:** The primary risk factor is a low CD4+ T-cell count. A study of 12 HIV-positive patients with pyomyositis reported a mean CD4+ count of 166.8 cells/ μ l, indicating severe immunodeficiency.[5]
- **Bacterial Colonization:** Patients with HIV are more commonly colonized with *Staphylococcus aureus*, the primary etiologic agent of pyomyositis.[4]
- **Trauma:** Minor muscle injury or trauma, which might be insignificant in an immunocompetent host, can serve as a nidus for infection in HIV-positive individuals.[3]
- **Geographic Location:** Although increasingly seen worldwide, the condition remains more common in tropical regions where both HIV and pyomyositis are endemic.[10][11]

Pathogenesis

The pathogenesis of pyomyositis in HIV-infected patients is a multifactorial process where host immunodeficiency, pathogen virulence, and local tissue factors converge. HIV infection creates a permissive environment for bacterial invasion and proliferation within muscle tissue.

3.1 Host Immunodeficiency in HIV

HIV infection leads to profound defects in both cellular and humoral immunity. Neutrophils from HIV-infected patients exhibit a range of functional impairments that critically undermine their ability to combat staphylococcal infections.[4][12] These defects include:

- Impaired chemotaxis and migration to the site of infection.
- Reduced phagocytic capacity.
- Diminished oxidative burst and bactericidal activity against *S. aureus*.[4]

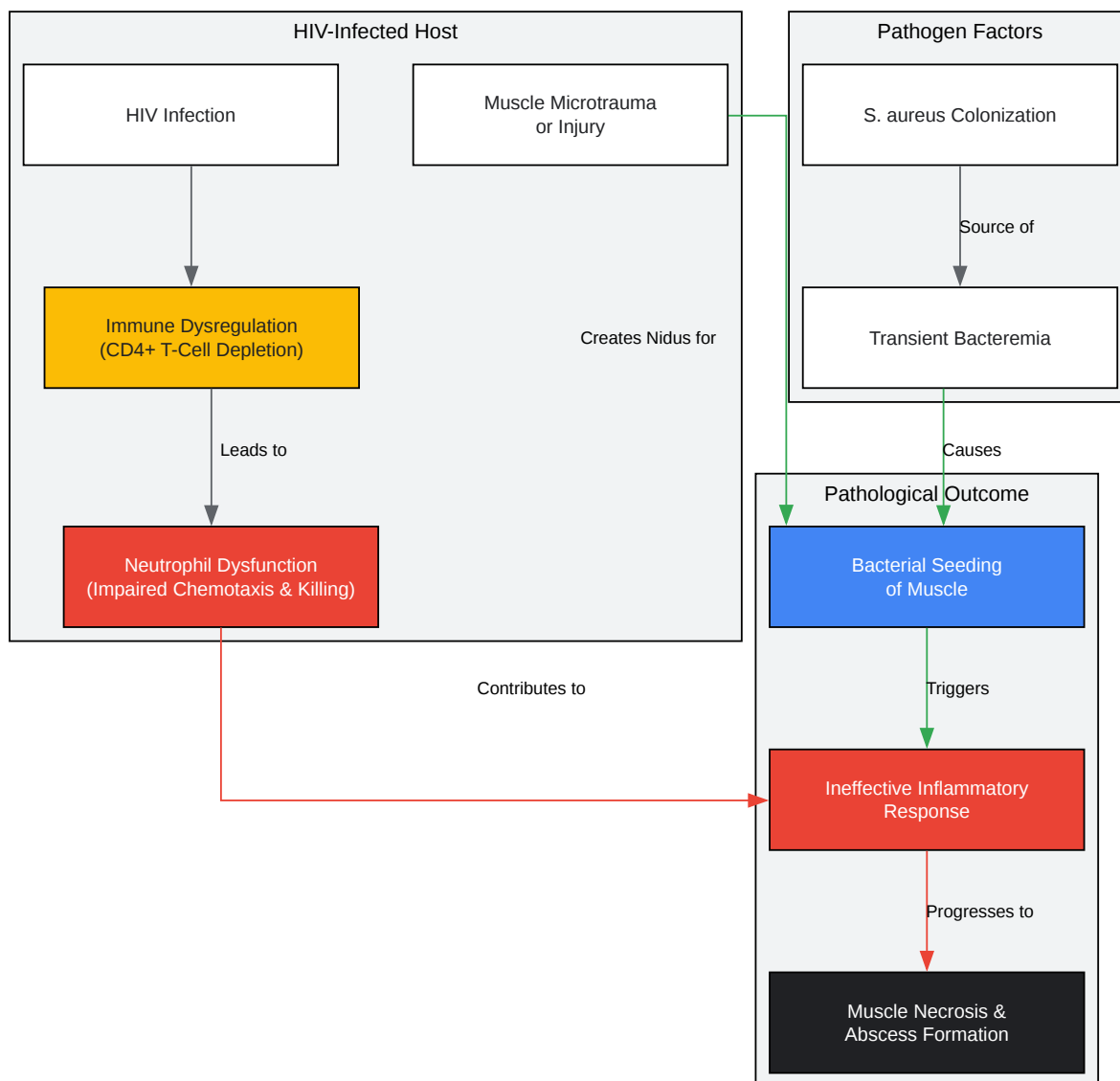
This neutrophil dysfunction is a key factor allowing a transient bacteremia to seed muscle tissue and establish an infection that the host cannot clear.

3.2 Role of *Staphylococcus aureus*

S. aureus is the causative organism in the majority of HIV-associated pyomyositis cases.[3][5][9] Its virulence is mediated by a host of factors, including surface proteins that facilitate adherence to muscle tissue and exotoxins that cause local tissue damage. In the setting of impaired neutrophil function, the bacteria can proliferate, leading to inflammation, suppuration, and abscess formation.[4]

3.3 Signaling Pathway in HIV-Associated Pyomyositis

The development of pyomyositis involves a cascade of events beginning with bacterial entry and culminating in abscess formation, a process significantly modulated by HIV-induced immunodeficiency.



[Click to download full resolution via product page](#)

Figure 1: Pathogenesis of HIV-Associated Pyomyositis.

Clinical Manifestations and Diagnosis

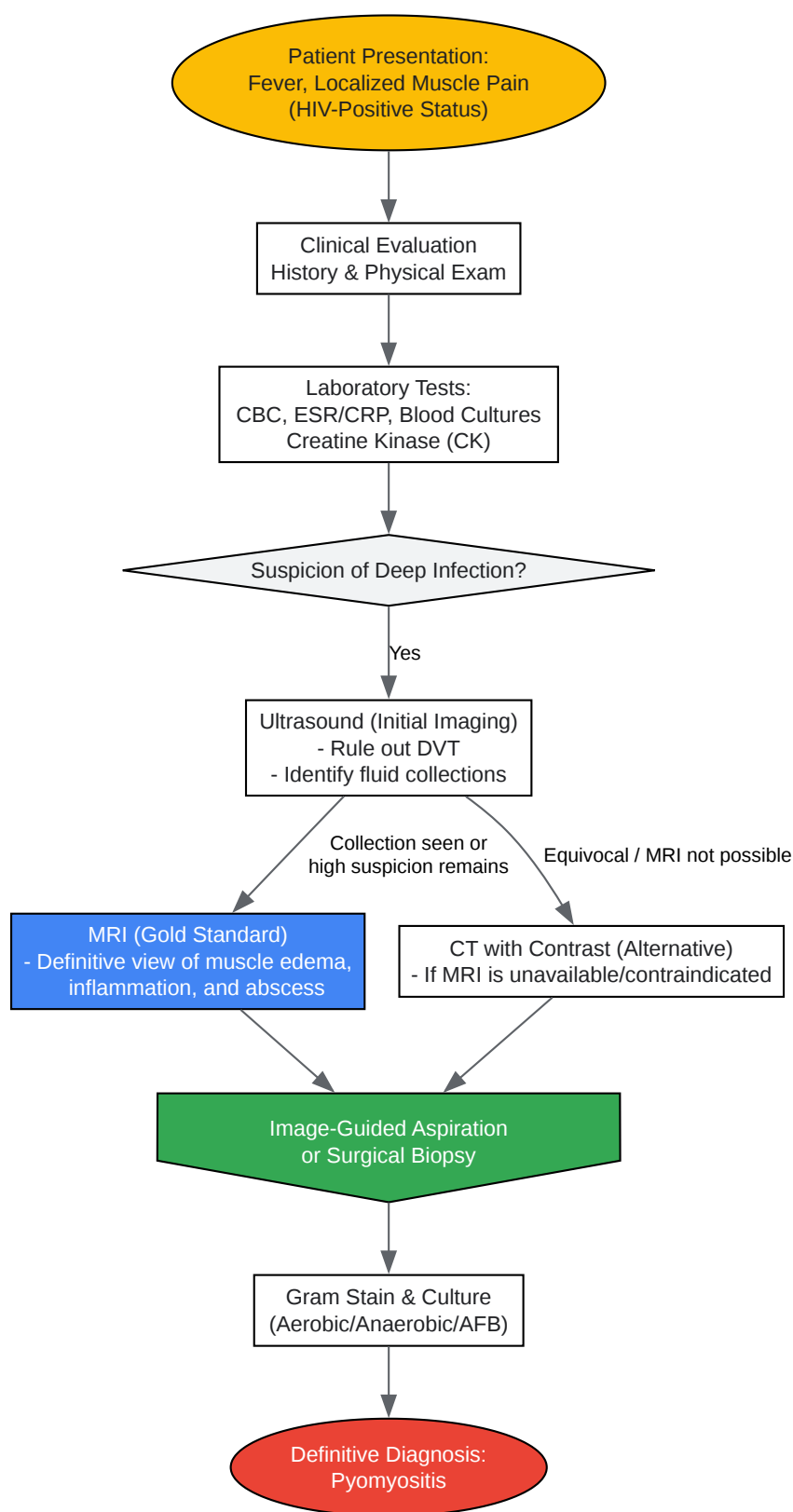
The diagnosis of pyomyositis in HIV-positive patients can be challenging due to a non-specific and often indolent presentation.^{[4][9]} The clinical course is typically divided into three stages:

- Stage 1 (Invasive): Characterized by localized muscle pain, tenderness, and low-grade fever. There is a "woody" texture to the muscle, but no frank pus can be aspirated.^{[7][12]}
- Stage 2 (Suppurative): Occurs 10-21 days later, with increasing fever, localized swelling, and intense pain. An abscess has formed, and pus can be aspirated.^[7]
- Stage 3 (Septic): Marked by systemic signs of sepsis, potential metastatic abscesses, and septic shock.^[7]

HIV-infected patients may not exhibit robust inflammatory signs; leukocytosis and bacteremia are less common than in immunocompetent hosts.^{[5][6]}

4.1 Diagnostic Workflow

A high index of suspicion is required. The diagnostic process is a stepwise evaluation combining clinical assessment, laboratory tests, and definitive imaging.



[Click to download full resolution via product page](#)

Figure 2: Diagnostic Workflow for Pyomyositis in HIV Patients.

4.2 Laboratory and Imaging Findings

- **Laboratory:** While white blood cell counts may be normal or low, inflammatory markers like Erythrocyte Sedimentation Rate (ESR) and C-reactive protein (CRP) are usually elevated.^[5] Creatine kinase (CK) levels are typically normal or only mildly elevated, distinguishing pyomyositis from HIV-associated polymyositis.^{[5][13]} Blood cultures may be positive but are not universally so.^[14]
- **Imaging:** Magnetic Resonance Imaging (MRI) is the gold standard, offering high sensitivity in detecting early muscle inflammation and differentiating between cellulitis, myositis, and abscess formation.^{[8][15]} Computed Tomography (CT) with contrast and ultrasound are also valuable for identifying fluid collections.^{[8][11]}

Management and Therapeutic Strategies

The treatment of HIV-associated pyomyositis is twofold: controlling the acute bacterial infection and managing the underlying immunodeficiency.

- **Antimicrobial Therapy:** Prompt initiation of empirical intravenous antibiotics is crucial. The choice should cover *S. aureus*, including Methicillin-resistant *S. aureus* (MRSA) if local prevalence is high. Treatment is typically continued for 3-6 weeks, guided by clinical response and culture results.^[8]
- **Surgical Intervention:** Most patients in the suppurative stage (Stage 2) require drainage of the abscess.^[7] This can be achieved through percutaneous needle aspiration under imaging guidance or by open surgical incision and drainage, which is often required for larger or multiloculated abscesses.^{[9][15]}
- **Antiretroviral Therapy (ART):** For patients not already on treatment, initiation or optimization of ART is a cornerstone of management. Reconstitution of the immune system is vital for clearing the infection and preventing recurrence.^[5]

Experimental Protocols

6.1 Protocol: Isolation and Culture of Causative Organism from Muscle Aspirate

- **Sample Collection:** Under sterile conditions and typically with ultrasound or CT guidance, aspirate purulent material from the identified muscle collection using a wide-bore needle and syringe.
- **Transport:** Immediately transport the aspirate to the microbiology laboratory in a sterile, capped syringe or a sterile container. For suspected anaerobes, use an anaerobic transport medium.
- **Direct Smear:** Prepare a smear of the pus on a glass slide. Perform a Gram stain and examine under a microscope for the presence of bacteria (e.g., Gram-positive cocci in clusters) and inflammatory cells.
- **Inoculation:** Inoculate the specimen onto the following culture media:
 - **Blood Agar Plate (BAP):** For growth of most aerobic bacteria.
 - **MacConkey Agar:** For selective growth and differentiation of Gram-negative bacteria.[\[16\]](#)
 - **Mannitol Salt Agar (MSA):** For selective growth of staphylococci.
 - **Anaerobic Media (e.g., Brucella agar):** For isolation of anaerobic organisms.
- **Incubation:** Incubate plates at 35-37°C. Aerobic plates are incubated in ambient air (or 5% CO₂ for fastidious organisms), while anaerobic plates are placed in an anaerobic jar or chamber. Incubate for at least 48-72 hours, examining daily for growth.
- **Identification and Susceptibility:** Identify suspicious colonies using standard microbiological techniques (e.g., catalase, coagulase tests for *S. aureus*) or automated systems (e.g., MALDI-TOF MS). Perform antimicrobial susceptibility testing (AST) to guide targeted antibiotic therapy.

6.2 Protocol: Neutrophil Phagocytosis Assay

- **Neutrophil Isolation:** Isolate neutrophils from heparinized whole blood obtained from both HIV-infected patients and healthy controls. Use a density gradient centrifugation method (e.g., using Ficoll-Paque followed by dextran sedimentation) to separate polymorphonuclear cells (PMNs).

- Bacterial Preparation:** Use a clinical isolate of *S. aureus* or a laboratory strain. Opsonize the bacteria by incubating them with pooled human serum or a specific antibody solution to coat them with complement and IgG. For quantification, label the bacteria with a fluorescent marker (e.g., fluorescein isothiocyanate - FITC).
- Phagocytosis Reaction:** Mix the isolated neutrophils with the opsonized, fluorescently-labeled *S. aureus* at a specific ratio (e.g., 10:1 bacteria-to-neutrophil). Incubate the mixture at 37°C for a defined period (e.g., 30-60 minutes) to allow for phagocytosis.
- Quenching:** Stop the reaction by adding an ice-cold quenching solution (e.g., trypan blue) that quenches the fluorescence of extracellular, non-phagocytosed bacteria.
- Data Acquisition:** Analyze the cells using a flow cytometer. The fluorescence intensity of the neutrophils will be proportional to the number of bacteria they have ingested.
- Analysis:** Compare the mean fluorescence intensity (MFI) and the percentage of fluorescent (phagocytosis-positive) neutrophils between the HIV-patient group and the healthy control group to quantify defects in phagocytic activity.^[4]

Data Summary

Quantitative data from studies on HIV-associated pyomyositis highlight the clinical context of this infection.

Table 1: Clinical and Laboratory Characteristics of Pyomyositis in 12 HIV-Positive Patients

Parameter	Mean Value / Finding	Range
Age (years)	39.3	24 - 52
CD4+ Cell Count (cells/μl)	166.8	1.0 - 433
White Blood Cell Count (x10 ³ /μl)	3.67	1.5 - 7.1
Neutrophil Percentage (%)	62.7	43 - 78
Creatine Kinase	Normal	-
Common Anatomical Site	Thigh (50% of cases)	-

(Data sourced from Otedo et al., 2014)[5]

Table 2: Common Causative Pathogens in HIV-Associated Pyomyositis

Pathogen	Frequency	Citation
Staphylococcus aureus	Predominant organism across all series	[3] [5] [9]
Streptococcus pyogenes	Common, reported in 33% of cases in one series	[5]
Gram-negative bacteria (e.g., E. coli)	Reported, particularly in immunocompromised hosts	[3] [16]

| Polymicrobial | Can occur, especially in advanced AIDS [[16](#)] |

Future Directions and Drug Development

The study of HIV-associated pyomyositis presents several avenues for future research and therapeutic development.

- **Immunomodulatory Therapies:** Given the central role of neutrophil dysfunction, developing adjunctive therapies that can enhance neutrophil function (e.g., granulocyte colony-stimulating factor, G-CSF) could improve outcomes.
- **Novel Antimicrobials:** The threat of MRSA necessitates the development of new antibiotics with efficacy against resistant Gram-positive organisms.
- **Pathogenesis Research:** Further investigation into the specific molecular interactions between *S. aureus* and muscle tissue in an immunocompromised environment could reveal novel targets for drugs that prevent bacterial adhesion and invasion.
- **Diagnostic Biomarkers:** Identifying biomarkers that can help in the early diagnosis of pyomyositis, before abscess formation, could allow for medical management to succeed without the need for surgical intervention.

Need Custom Synthesis?

BenchChem offers custom synthesis for rare earth carbides and specific isotopic labeling.

Email: info@benchchem.com or [Request Quote Online](#).

References

- 1. emedicine.medscape.com [emedicine.medscape.com]
- 2. Pyomyositis in North America: case reports and review - PubMed [pubmed.ncbi.nlm.nih.gov]
- 3. Pyomyositis in patients with the human immunodeficiency virus: an unusual form of disseminated bacterial infection - PubMed [pubmed.ncbi.nlm.nih.gov]
- 4. Staphylococcal pyomyositis in patients infected by the human immunodeficiency virus - PubMed [pubmed.ncbi.nlm.nih.gov]
- 5. Pyomyositis in HIV: A Series of 12 Cases [erepository.uonbi.ac.ke]
- 6. sma.org [sma.org]
- 7. Pyomyositis | Johns Hopkins ABX Guide [hopkinsguides.com]
- 8. RBCP - Diagnosis, evolution and treatment of a patient with pyomyositis [rbcp.org.br]
- 9. research.monash.edu [research.monash.edu]
- 10. Pyomyositis and human immunodeficiency virus infection - PubMed [pubmed.ncbi.nlm.nih.gov]
- 11. m.youtube.com [m.youtube.com]
- 12. jkscience.org [jkscience.org]
- 13. neurology.org [neurology.org]
- 14. Diagnosing pyomyositis requires documentation of a causative infectious agent - PMC [pmc.ncbi.nlm.nih.gov]
- 15. Acute pyomyositis: Diagnosis and treatment of 3 cases in a secondary hospital | Anales de Pediatría [analesdepediatria.org]
- 16. Pyomyositis in a Patient with AIDS - PMC [pmc.ncbi.nlm.nih.gov]
- To cite this document: BenchChem. [Pyomyositis and its association with HIV infection]. BenchChem, [2025]. [Online PDF]. Available at:

[<https://www.benchchem.com/product/b1172056#pyomyositis-and-its-association-with-hiv-infection>]

Disclaimer & Data Validity:

The information provided in this document is for Research Use Only (RUO) and is strictly not intended for diagnostic or therapeutic procedures. While BenchChem strives to provide accurate protocols, we make no warranties, express or implied, regarding the fitness of this product for every specific experimental setup.

Technical Support: The protocols provided are for reference purposes. Unsure if this reagent suits your experiment? [[Contact our Ph.D. Support Team for a compatibility check](#)]

Need Industrial/Bulk Grade? [Request Custom Synthesis Quote](#)

BenchChem

Our mission is to be the trusted global source of essential and advanced chemicals, empowering scientists and researchers to drive progress in science and industry.

Contact

Address: 3281 E Guasti Rd
Ontario, CA 91761, United States
Phone: (601) 213-4426
Email: info@benchchem.com