

# Protocol for [ $^{18}\text{F}$ ]-FDOPA Imaging of Neuroendocrine Tumors

**Author:** BenchChem Technical Support Team. **Date:** December 2025

## Compound of Interest

Compound Name: [ $^{18}\text{F}$ ]-Labeled L-dopa precursor

Cat. No.: B12430852

[Get Quote](#)

Application Note and Protocol for Researchers, Scientists, and Drug Development Professionals

This document provides a detailed protocol for the use of 6- $^{18}\text{F}$ -fluoro-L-3,4-dihydroxyphenylalanine ([ $^{18}\text{F}$ ]-FDOPA) Positron Emission Tomography/Computed Tomography (PET/CT) in the imaging of neuroendocrine tumors (NETs). [ $^{18}\text{F}$ ]-FDOPA PET/CT is a valuable molecular imaging technique for the diagnosis, staging, and monitoring of NETs due to the overexpression of amino acid transporters and the presence of L-DOPA decarboxylase in these tumors.

## Principle of the Method

[ $^{18}\text{F}$ ]-FDOPA, a fluorinated analog of L-DOPA, is taken up by neuroendocrine tumor cells through large neutral amino acid transporters. Inside the cell, it is converted by the enzyme L-DOPA decarboxylase into [ $^{18}\text{F}$ ]-fluorodopamine, which is then stored in neurosecretory vesicles. This intracellular trapping of the radiotracer allows for the visualization of NETs with high sensitivity and specificity using PET imaging.

## Patient Preparation

Proper patient preparation is crucial for optimal image quality and to minimize physiological background uptake of [ $^{18}\text{F}$ ]-FDOPA.

Table 1: Patient Preparation Protocol

Parameter	Recommendation	Rationale
Fasting	Minimum of 4-6 hours prior to [ $^{18}\text{F}$ ]-FDOPA injection.	To reduce insulin levels and minimize competitive inhibition of tracer uptake.
Hydration	Patients should be well-hydrated. Water intake is permitted and encouraged. <a href="#">[1]</a>	To ensure good renal clearance of the radiotracer and reduce radiation dose to the bladder.
Medications	No specific medication withdrawal is generally required. <a href="#">[1]</a>	[ $^{18}\text{F}$ ]-FDOPA has no known major interactions with common medications.
Premedication with Carbidopa	Oral administration of 200 mg Carbidopa 1-2 hours before [ $^{18}\text{F}$ ]-FDOPA injection is recommended. <a href="#">[2]</a> <a href="#">[3]</a>	Carbidopa is a peripheral L-DOPA decarboxylase inhibitor that reduces the peripheral metabolism of [ $^{18}\text{F}$ ]-FDOPA, thereby increasing its bioavailability for tumor uptake and reducing background signal from the pancreas and urinary tract. <a href="#">[2]</a>

## Radiopharmaceutical Administration

The administration of [ $^{18}\text{F}$ ]-FDOPA should be performed by trained personnel in accordance with local regulations for handling radioactive materials.

Table 2: [ $^{18}\text{F}$ ]-FDOPA Administration Protocol

Parameter	Recommendation	Notes
Dosage (Adults)	2-4 MBq/kg of body weight.	The administered activity may be adjusted based on institutional protocols and scanner characteristics.
Route of Administration	Slow intravenous (IV) injection. <a href="#">[1]</a>	Administer over approximately one minute.
Uptake Time	20-30 minutes post-injection for delayed whole-body acquisition. An early acquisition at 5 minutes post-injection over the upper abdomen may also be performed. <a href="#">[3]</a>	Tumor uptake of [ <sup>18</sup> F]-FDOPA generally plateaus within 20 minutes. <a href="#">[2]</a>

## PET/CT Image Acquisition

The following parameters are provided as a general guideline and may be adapted based on the specific PET/CT scanner and institutional protocols.

Table 3: PET/CT Image Acquisition Parameters

Parameter	Recommendation
Scanner	PET/CT scanner
CT Acquisition	
Scan Type	Low-dose CT for attenuation correction and anatomical localization. A diagnostic quality CT may be performed if clinically indicated.
Scan Range	Vertex to mid-thigh
Tube Voltage	120 kV
Tube Current	Modulated (e.g., CARE Dose4D)
Slice Thickness	2-5 mm
PET Acquisition	
Acquisition Mode	3D
Scan Range	Vertex to mid-thigh
Acquisition Time per Bed Position	2-4 minutes
Image Reconstruction	Iterative reconstruction algorithm (e.g., OSEM) with corrections for attenuation, scatter, and randoms.
Matrix Size	e.g., 128x128 or 256x256
Filter	As per institutional protocol

## Image Interpretation

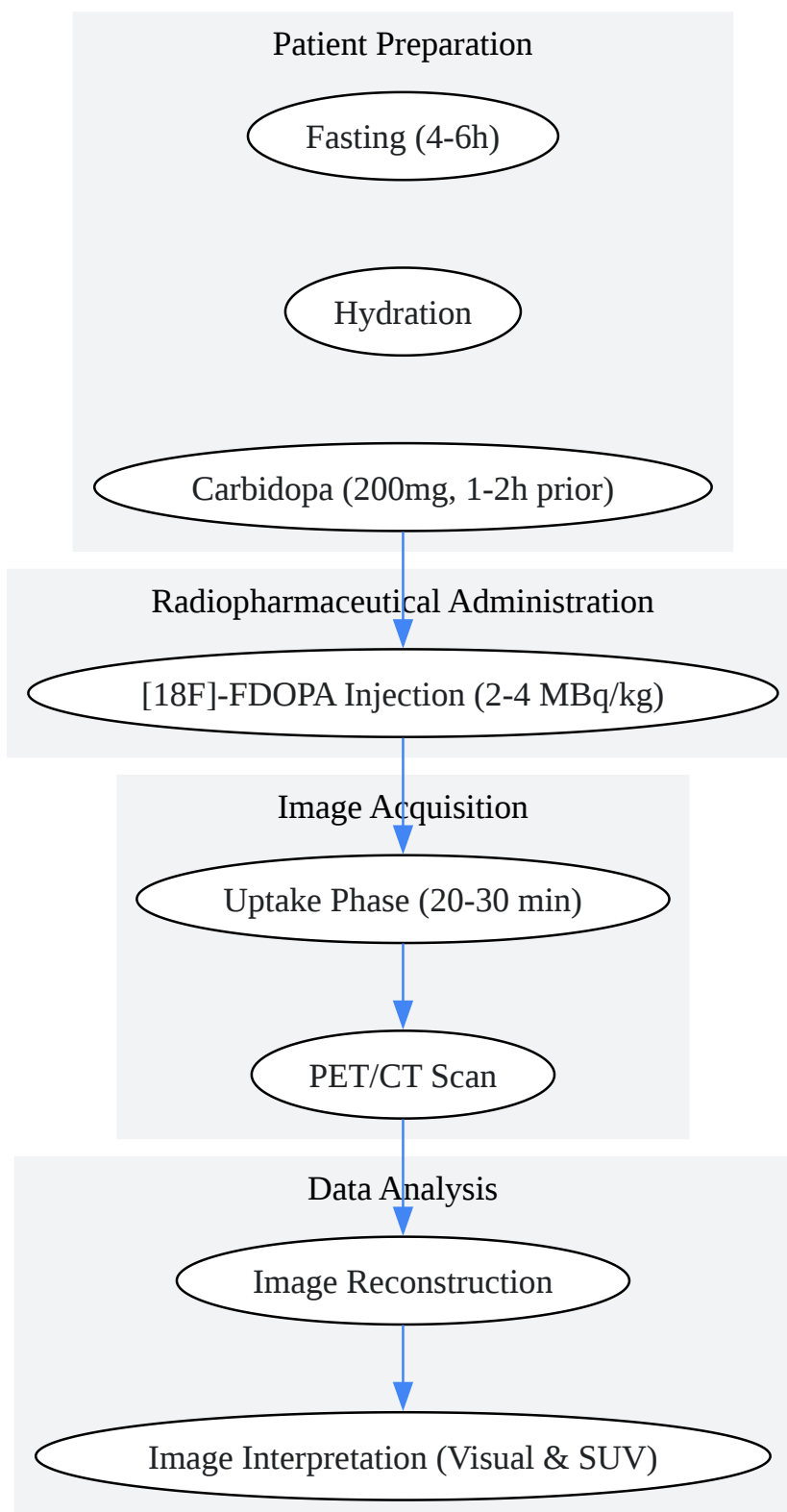
Image interpretation should be performed by a qualified nuclear medicine physician or radiologist with experience in [ $^{18}\text{F}$ ]-FDOPA PET/CT imaging.

- **Visual Analysis:** Any focal uptake that is more intense than the surrounding background and does not correspond to physiological distribution should be considered suspicious for malignancy. Physiological uptake is normally seen in the striatum, liver, pancreas (can be reduced with carbidopa premedication), kidneys, and urinary bladder.

- **Semi-Quantitative Analysis (SUV):** The Standardized Uptake Value (SUV) can be used to quantify the tracer uptake in suspicious lesions. While there is no universally accepted cutoff value, higher SUVmax values are generally more indicative of malignancy. The liver can serve as a reference organ for calculating lesion-to-liver ratios.<sup>[1]</sup> In some contexts, a tumor-to-liver SUVpeak ratio of greater than 4.2 has been associated with a poorer prognosis in patients with metastatic midgut NETs.<sup>[4]</sup>

## Experimental Workflow and Signaling Pathway Diagrams

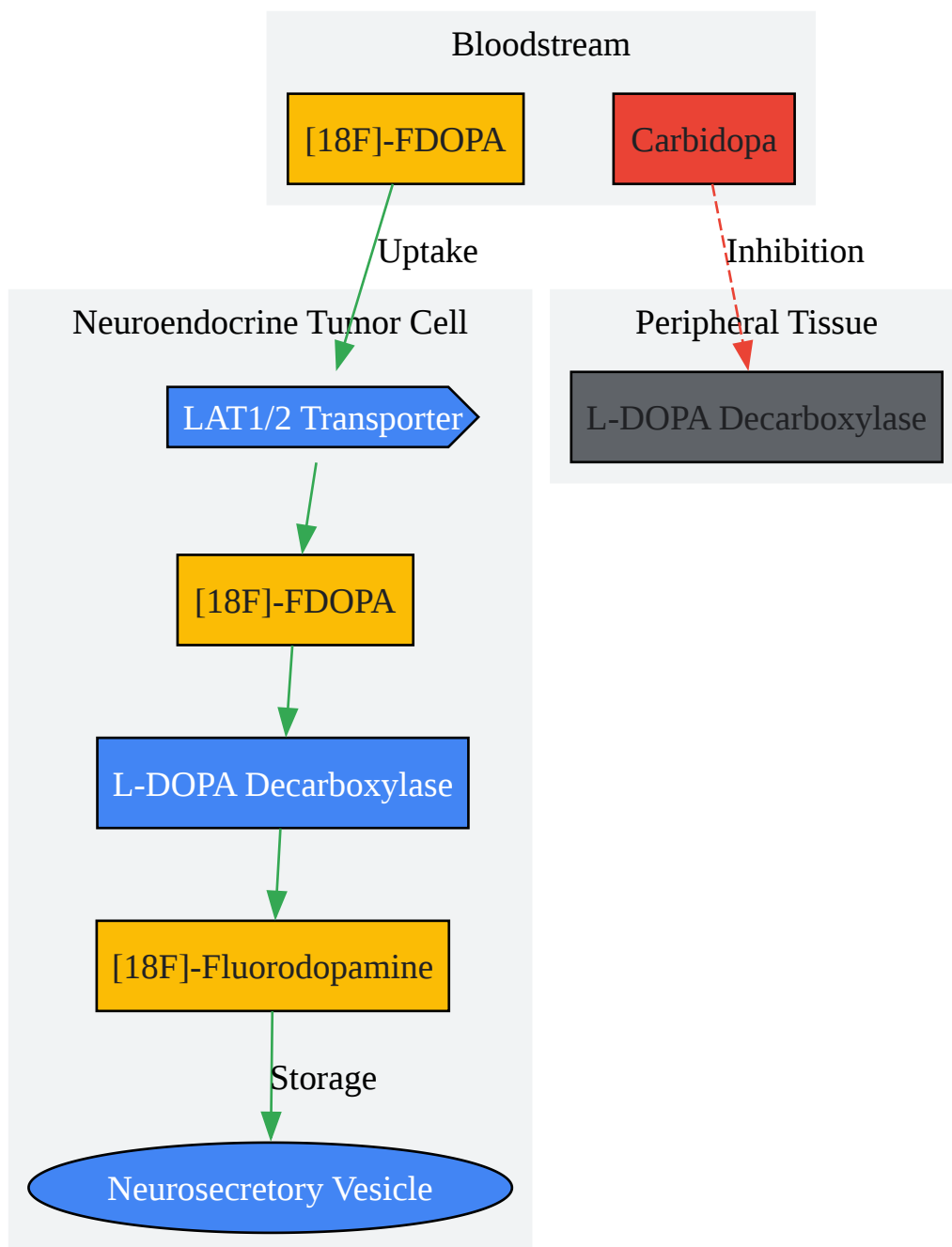
### Experimental Workflow



[Click to download full resolution via product page](#)

Caption: Workflow for  $[^{18}\text{F}]$ -FDOPA PET/CT imaging of neuroendocrine tumors.

## [<sup>18</sup>F]-FDOPA Uptake and Metabolism Pathway



[Click to download full resolution via product page](#)

Caption: Cellular uptake and metabolism of [<sup>18</sup>F]-FDOPA in neuroendocrine tumors.

**Need Custom Synthesis?**

BenchChem offers custom synthesis for rare earth carbides and specific isotopic labeling.

Email: [info@benchchem.com](mailto:info@benchchem.com) or [Request Quote Online](#).

## References

- 1. kfnm.dk [kfnm.dk]
- 2. snmmi.org [snmmi.org]
- 3. Early 18F-FDOPA PET/CT imaging after carbidopa premedication as a valuable diagnostic option in patients with insulinoma - PubMed [pubmed.ncbi.nlm.nih.gov]
- 4. High Tumor Uptake on 18F-FDOPA PET/CT Indicates Poor Prognosis in Patients with Metastatic Midgut Neuroendocrine Tumors: A Study from the Groupe d'étude des Tumeurs Endocrines and ENDOCAN-RENATEN Network - PubMed [pubmed.ncbi.nlm.nih.gov]
- To cite this document: BenchChem. [Protocol for [<sup>18</sup>F]-FDOPA Imaging of Neuroendocrine Tumors]. BenchChem, [2025]. [Online PDF]. Available at: [https://www.benchchem.com/product/b12430852#protocol-for-18f-fdopa-imaging-of-neuroendocrine-tumors]

---

**Disclaimer & Data Validity:**

The information provided in this document is for Research Use Only (RUO) and is strictly not intended for diagnostic or therapeutic procedures. While BenchChem strives to provide accurate protocols, we make no warranties, express or implied, regarding the fitness of this product for every specific experimental setup.

**Technical Support:** The protocols provided are for reference purposes. Unsure if this reagent suits your experiment? [[Contact our Ph.D. Support Team for a compatibility check](#)]

**Need Industrial/Bulk Grade?** [Request Custom Synthesis Quote](#)



# BenchChem

Our mission is to be the trusted global source of essential and advanced chemicals, empowering scientists and researchers to drive progress in science and industry.

## Contact

Address: 3281 E Guasti Rd

Ontario, CA 91761, United States

Phone: (601) 213-4426

Email: [info@benchchem.com](mailto:info@benchchem.com)