

PSMA PET Imaging Technical Support Center: Troubleshooting Guides & FAQs

Author: BenchChem Technical Support Team. **Date:** December 2025

Compound of Interest

Compound Name: *Psma I&S tfa*

Cat. No.: *B10857062*

[Get Quote](#)

This technical support center provides troubleshooting guidance for researchers, scientists, and drug development professionals encountering artifacts in Prostate-Specific Membrane Antigen (PSMA) Positron Emission Tomography (PET) imaging.

Frequently Asked Questions (FAQs) & Troubleshooting Guides Urinary Tract Artifacts

Question: Why do I see a "halo" or photopenic area around the bladder or kidneys in my PSMA PET images?

Answer: This "halo artifact" is a common issue in PSMA PET imaging caused by high concentrations of the radiotracer being excreted through the urinary system.^{[1][2][3][4]} The intense signal from the bladder or kidneys can lead to an overestimation of scatter correction, resulting in an artificial reduction of signal in the surrounding tissues.^[4] This can obscure the detection of lesions in the pelvic region, a critical area for prostate cancer assessment.

Troubleshooting Steps:

- **Patient Hydration and Voiding:** Ensure the patient is well-hydrated and voids immediately before the scan to reduce tracer concentration in the bladder.

- **Diuretics:** The administration of a diuretic, such as furosemide, can help to increase urine flow and reduce the radiotracer concentration in the bladder and ureters. Studies have shown that intravenous furosemide can effectively reduce urinary activity.
- **Imaging Protocol:**
 - **Early Dynamic Imaging:** Acquiring images shortly after tracer injection (within the first few minutes) can help visualize lesions before significant tracer accumulation in the bladder.
 - **Delayed Imaging:** Imaging the pelvic region at a later time point after the patient has voided may also be beneficial.
- **Reconstruction Algorithms:** Utilize advanced scatter correction algorithms. Improved time-of-flight (TOF) scatter correction has been shown to significantly reduce the severity of halo artifacts. Unrenormalized absolute scatter correction is another technique that has demonstrated a reduction in halo artifacts.

Question: How does the choice of PSMA radiotracer affect urinary artifacts?

Answer: Different PSMA radiotracers have varying excretion characteristics. For instance, ¹⁸F-DCFPyL has been observed to have higher urinary activity and a greater incidence of peri-bladder artifacts compared to ⁶⁸Ga-PSMA-11. Conversely, tracers like ¹⁸F-PSMA-1007 generally show less urinary excretion and more hepatobiliary clearance. However, even with tracers that have lower urinary excretion, high bladder uptake can still occur in some patients. The recently approved ¹⁸F-rhPSMA-7.3 (flotufolastat F 18) has been reported to have relatively low urinary activity, rarely impacting disease assessment in the pelvic region.

Motion Artifacts

Question: My PET/CT images show misalignment between the PET and CT data, especially near the diaphragm. What could be the cause and how can I fix it?

Answer: This misalignment is likely due to patient motion, including respiratory motion. Such motion can lead to inaccurate attenuation correction and mislocalization of tracer uptake, potentially obscuring or creating false lesions.

Troubleshooting Steps:

- **Patient Comfort and Instruction:** Ensure the patient is comfortable and understands the importance of remaining still during the acquisition.
- **Immobilization Devices:** Use appropriate patient immobilization devices to minimize bulk motion.
- **Motion Correction Techniques:**
 - **Gating:** Respiratory and cardiac gating techniques can be employed to acquire data at specific points in the physiological cycle, thus reducing motion artifacts. These can be either hardware-driven (using external sensors) or data-driven (extracting motion information from the PET data itself).
 - **Image Registration:** Post-acquisition image registration algorithms can be used to align the PET and CT images.
- **Image Review:** Carefully inspect the non-attenuation corrected (NAC) PET images and the maximum intensity projection (MIP) images, as these can often provide clues to misregistration.

Metal Artifacts

Question: I am imaging a patient with a hip prosthesis, and there are significant artifacts on the PET/CT images. How can I mitigate these?

Answer: Metal implants, such as hip prostheses or dental implants, can cause severe artifacts on CT images due to beam hardening and photon scattering. These artifacts are then propagated into the attenuation correction map, leading to errors in the final PET image, which can either obscure underlying lesions or create false-positive findings.

Troubleshooting Steps:

- **Metal Artifact Reduction (MAR) Algorithms:** Utilize iterative metal artifact reduction (iMAR) algorithms during CT reconstruction. These algorithms are designed to correct for the artifacts caused by metallic implants and have been shown to improve the quality of both the CT and the resulting PET images.

- **Advanced MRI Sequences (for PET/MRI):** In PET/MRI, specialized sequences like multi-acquisition variable-resonance image combination (MAVRIC) can significantly reduce metal artifacts, improving the anatomical localization of PSMA uptake near implants.
- **Image Review:** Reviewing non-attenuation corrected PET images can help in identifying whether an apparent lesion is a true finding or an artifact. It is also recommended to reconstruct PET images with and without attenuation correction to identify potential reconstruction artifacts.

Quantitative Data Summary

Table 1: Impact of Furosemide and Tracer Type on Urinary Activity and Artifacts

Parameter	68Ga-PSMA-11	18F-DCFPyL	18F-DCFPyL + Furosemide
Bladder SUVmax	Lower	Higher	Significantly Reduced
Ureter SUVmax	Lower	Higher	Significantly Reduced
Peri-bladder Artifacts	Lower Incidence	Higher Incidence	Reduced Incidence

Data summarized from a retrospective study comparing tracer types and the effect of 10mg intravenous furosemide.

Table 2: Effect of Improved Scatter Correction on Halo Artifact and SUV Measurements

Parameter	Standard Scatter Correction	Improved (Unrenormalized) Scatter Correction	Percentage Change
Halo Artifact Score (Visual)	Higher	Significantly Reduced	-
Gluteus Maximus SUVmax	Lower	Higher	+15.8% ± 7.9%
Bladder SUVmax	Lower	Higher	+5.9% ± 3.8%

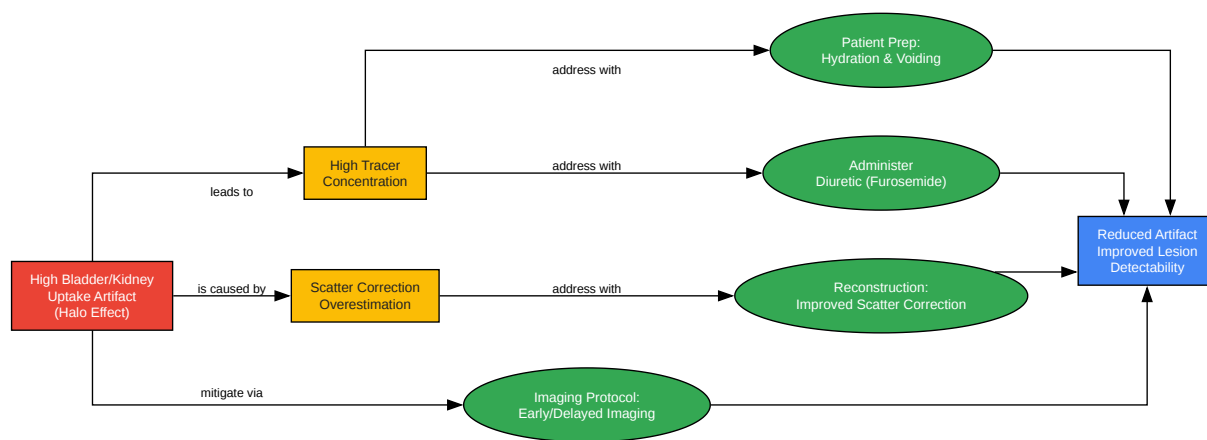
Data from a study on 100 patients undergoing 68Ga-PSMA PET/MRI, showing the impact of an improved scatter correction method.

Experimental Protocols

Protocol for Reducing Urinary Artifacts with Furosemide

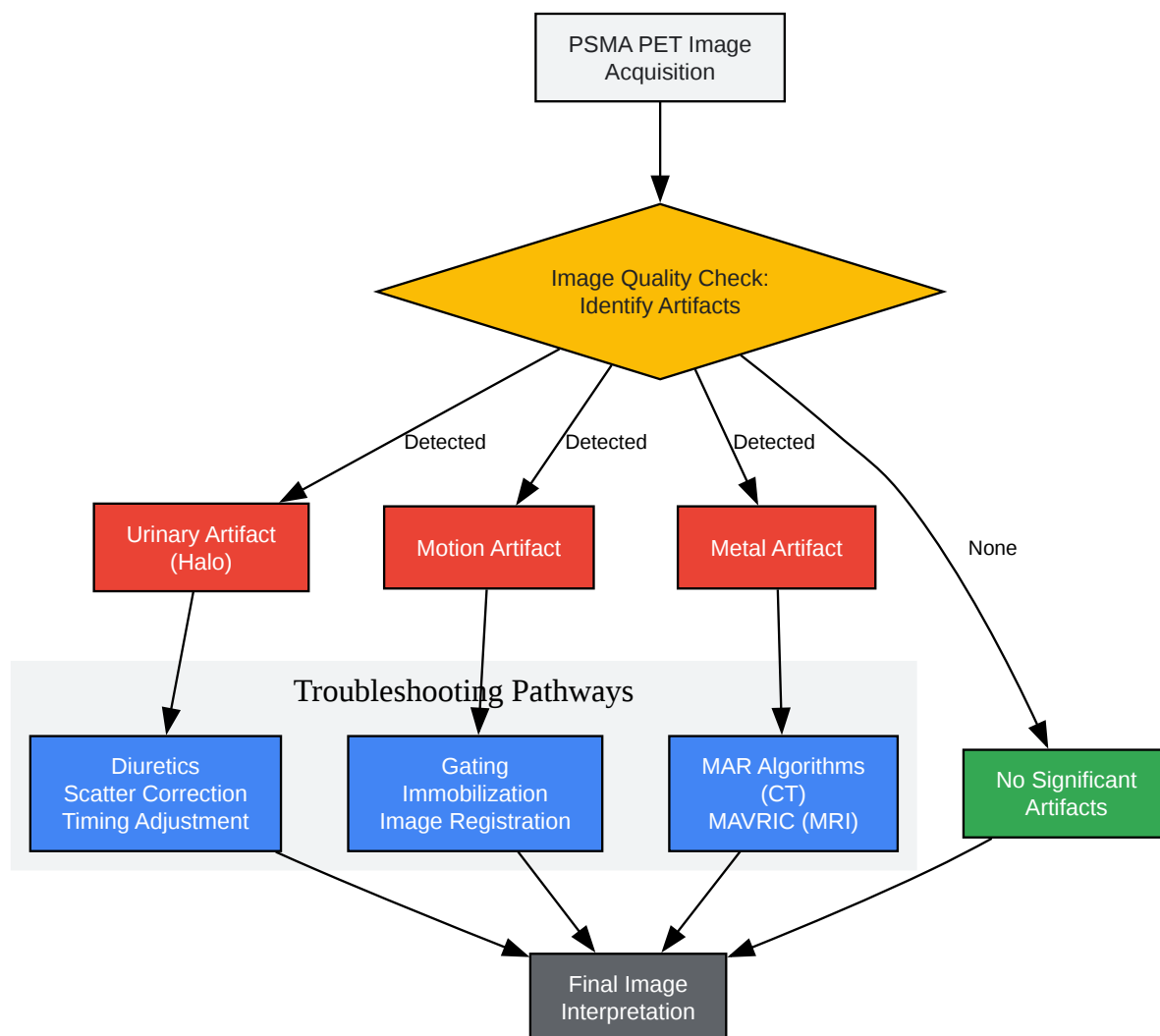
- Patient Preparation:
 - Instruct the patient to hydrate well (e.g., drink 1 liter of water) starting 1 hour before the scheduled radiotracer injection.
 - Ensure no contraindications to furosemide exist (e.g., allergy, urinary obstruction).
- Radiotracer and Furosemide Administration:
 - Administer the PSMA radiotracer (e.g., 18F-DCFPyL or 68Ga-PSMA-11) intravenously.
 - Administer 10-20 mg of furosemide intravenously. This can be done shortly before, during, or immediately after the radiotracer injection.
- Uptake Phase:
 - Allow for the standard uptake period (typically 60 minutes).
- Pre-Scan Procedure:
 - Immediately before positioning the patient on the scanner, instruct them to void their bladder completely.
- Image Acquisition:
 - Proceed with the standard PET/CT or PET/MRI acquisition protocol.
 - Consider acquiring images from the pelvis up to the head to minimize the impact of bladder refilling during the scan.

Visualizations



[Click to download full resolution via product page](#)

Caption: Troubleshooting workflow for urinary artifacts in PSMA PET.



[Click to download full resolution via product page](#)

Caption: General logical workflow for identifying and managing common PSMA PET artifacts.

Need Custom Synthesis?

BenchChem offers custom synthesis for rare earth carbides and specific isotopic labeling.

Email: info@benchchem.com or [Request Quote Online](#).

References

- 1. Effects of furosemide and tracer selection on urinary activity and peri-bladder artefacts in PSMA PET/CT: a single-centre retrospective study - PMC [pmc.ncbi.nlm.nih.gov]
- 2. Effects of furosemide and tracer selection on urinary activity and peri-bladder artefacts in PSMA PET/CT: a single-centre retrospective study | springermedizin.de [springermedizin.de]
- 3. Frontiers | Normal Variants, Pitfalls, and Artifacts in Ga-68 Prostate Specific Membrane Antigen (PSMA) PET/CT Imaging [frontiersin.org]
- 4. jnm.snmjournals.org [jnm.snmjournals.org]
- To cite this document: BenchChem. [PSMA PET Imaging Technical Support Center: Troubleshooting Guides & FAQs]. BenchChem, [2025]. [Online PDF]. Available at: [https://www.benchchem.com/product/b10857062#troubleshooting-artifacts-in-psma-pet-imaging]

Disclaimer & Data Validity:

The information provided in this document is for Research Use Only (RUO) and is strictly not intended for diagnostic or therapeutic procedures. While BenchChem strives to provide accurate protocols, we make no warranties, express or implied, regarding the fitness of this product for every specific experimental setup.

Technical Support: The protocols provided are for reference purposes. Unsure if this reagent suits your experiment? [[Contact our Ph.D. Support Team for a compatibility check](#)]

Need Industrial/Bulk Grade? [Request Custom Synthesis Quote](#)

BenchChem

Our mission is to be the trusted global source of essential and advanced chemicals, empowering scientists and researchers to drive progress in science and industry.

Contact

Address: 3281 E Guasti Rd
Ontario, CA 91761, United States
Phone: (601) 213-4426
Email: info@benchchem.com