

Navigating Renal Mass Diagnosis: A Comparative Guide to VM4-037 and Alternative Methods

Author: BenchChem Technical Support Team. **Date:** December 2025

Compound of Interest

Compound Name: VM4-037

Cat. No.: B611697

[Get Quote](#)

For Researchers, Scientists, and Drug Development Professionals

The accurate diagnosis of renal masses is a critical step in guiding appropriate patient management, distinguishing between benign lesions and malignant tumors, particularly the most common and aggressive subtype, clear cell renal cell carcinoma (ccRCC). This guide provides a comprehensive comparison of the diagnostic accuracy of **VM4-037**, a novel PET imaging agent, with established and emerging alternative diagnostic modalities. Experimental data is presented to support an objective assessment of each method's performance.

At a Glance: Comparing Diagnostic Tools for Renal Masses

The landscape of diagnostic tools for renal masses is evolving, with a shift towards non-invasive methods that can provide accurate characterization. Below is a summary of the performance of **VM4-037** and its key alternatives.

Diagnostic Method	Target/Principle	Sensitivity	Specificity	Key Findings & Limitations
¹⁸ F-VM4-037 PET/CT	Carbonic Anhydrase IX (CA-IX)	Not explicitly reported for primary tumors	Not explicitly reported for primary tumors	Well-tolerated and effective for visualizing CA-IX positive metastases. However, high background uptake in the normal kidney parenchyma makes it challenging to evaluate primary ccRCC lesions. [1] [2] [3]
⁸⁹ Zr-girentuximab PET/CT	Carbonic Anhydrase IX (CA-IX)	85.5%	87.0%	A phase III trial (ZIRCON) demonstrated high accuracy for detecting ccRCC. [4] [5] All PET-positive lesions in the trial were malignant.

Multiparametric MRI (mpMRI)	Tissue characteristics (e.g., vascularity, cellularity)	78% - 95%	58% - 80%	Can reasonably identify clear cell histology and may reduce the need for biopsies. Accuracy can vary based on the scoring criteria used.
CT-guided Biopsy	Histopathological analysis	93.5% - 95.2%	~61% - 82%	Considered a standard for diagnosis, offering high sensitivity for RCC. It is an invasive procedure with potential complications.
¹⁸ F-FDG PET/CT	Glucose metabolism	Low for primary RCC	Low for primary RCC	Limited utility for diagnosing primary RCC due to high renal excretion of FDG. More effective for detecting recurrent and metastatic disease.

In-Depth Experimental Protocols

Understanding the methodologies behind the data is crucial for a comprehensive assessment. The following sections detail the experimental protocols for the key diagnostic methods

discussed.

^{18}F -VM4-037 PET/CT Imaging

The phase II pilot study of ^{18}F -**VM4-037** for imaging renal masses involved a specific protocol to assess its safety and efficacy.

- **Patient Population:** The study enrolled patients with suspected renal masses scheduled for surgery.
- **Radiotracer Administration:** Patients received an intravenous injection of ^{18}F -**VM4-037**.
- **Imaging Protocol:** Dynamic PET imaging of the kidneys was performed for the first 45 minutes post-injection, followed by a whole-body PET/CT scan at 60 minutes post-injection.
- **Image Analysis:** The uptake of the radiotracer was measured using Standardized Uptake Values (SUVs). The mean SUV for primary kidney lesions and metastatic lesions was calculated.
- **Histopathological Correlation:** The imaging findings were correlated with the histopathological results from the surgically removed tumor tissue, which served as the gold standard for diagnosis.

^{89}Zr -girentuximab PET/CT Imaging (ZIRCON Trial)

The phase III ZIRCON trial for ^{89}Zr -girentuximab established a robust protocol for its evaluation.

- **Patient Population:** The trial included patients with an indeterminate renal mass suspicious for ccRCC who were scheduled for nephrectomy.
- **Radiotracer Administration:** A single dose of ^{89}Zr -girentuximab was administered intravenously.
- **Imaging Protocol:** Abdominal PET/CT imaging was performed 5 days (± 2 days) after the injection of the radiotracer.

- **Image Analysis:** The PET/CT images were evaluated for the presence and intensity of radiotracer uptake in the renal mass.
- **Histopathological Correlation:** The diagnostic performance (sensitivity and specificity) was determined by comparing the imaging findings with the histopathological diagnosis from three independent readers.

Multiparametric MRI (mpMRI)

Multiparametric MRI for renal mass characterization utilizes a combination of different MRI sequences to provide detailed anatomical and functional information.

- **Imaging Protocol:** A typical mpMRI protocol for renal masses includes:
 - T2-weighted imaging to assess tissue composition.
 - T1-weighted in-phase and out-of-phase imaging to detect intracellular fat.
 - Diffusion-Weighted Imaging (DWI) to evaluate water diffusion and cellularity.
 - Dynamic Contrast-Enhanced (DCE) imaging to assess tumor vascularity and enhancement patterns.
- **Image Analysis:** Radiologists use a standardized scoring system, such as the clear cell likelihood score (ccLS), to classify the probability of a renal mass being ccRCC based on its appearance across the different MRI sequences.
- **Histopathological Correlation:** The diagnostic accuracy of mpMRI is determined by comparing the radiological diagnosis with the final histopathological findings.

CT-guided Biopsy

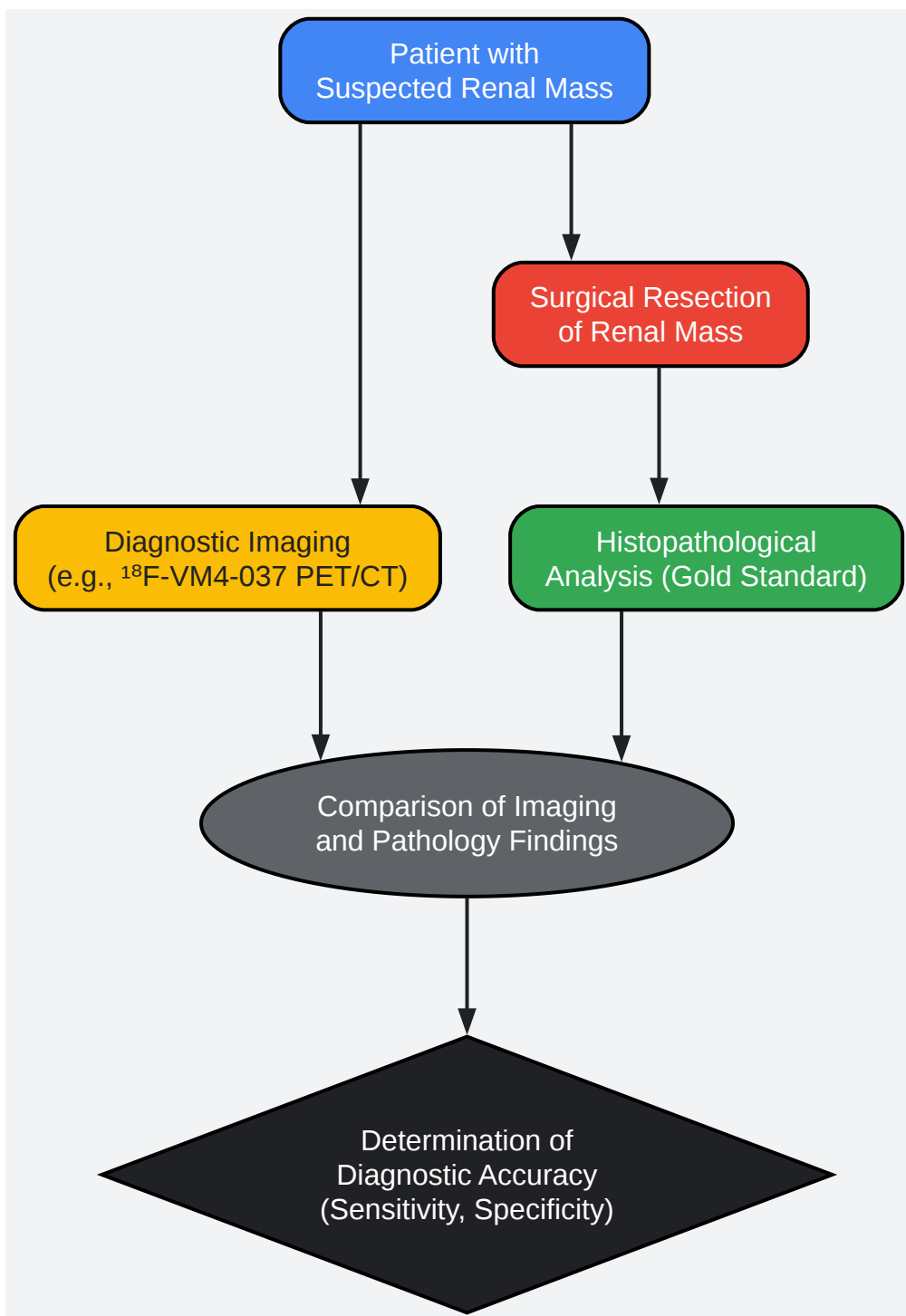
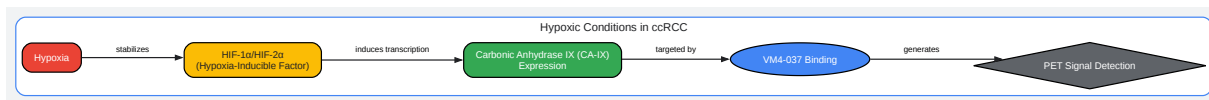
CT-guided percutaneous biopsy remains a cornerstone for the definitive diagnosis of renal masses.

- **Procedure:** Under CT-fluoroscopic guidance, a coaxial needle is advanced to the periphery of the renal mass. Core biopsy samples and/or fine-needle aspiration samples are then obtained.

- **Sample Analysis:** The collected tissue and cell samples are sent for histopathological and cytological analysis, respectively, to determine the tumor type and grade.
- **Accuracy Assessment:** The sensitivity and specificity of the biopsy are calculated by comparing the biopsy results with the final pathology from the surgically resected tumor.

Visualizing the Pathways and Processes

To further elucidate the concepts discussed, the following diagrams illustrate a key signaling pathway and a typical experimental workflow.



[Click to download full resolution via product page](#)

Need Custom Synthesis?

BenchChem offers custom synthesis for rare earth carbides and specific isotopic labeling.

Email: info@benchchem.com or [Request Quote Online](#).

References

- 1. PET/CT imaging of renal cell carcinoma with (18)F-VM4-037: a phase II pilot study - PubMed [pubmed.ncbi.nlm.nih.gov]
- 2. researchgate.net [researchgate.net]
- 3. PET/CT imaging of renal cell carcinoma with 18F-VM4-037: a phase II pilot study - PMC [pmc.ncbi.nlm.nih.gov]
- 4. urotoday.com [urotoday.com]
- 5. Detecting Clear Cell Renal Cell Carcinoma: Use of Zr-89 Girentuximab PET-CT Imaging - The ASCO Post [ascopost.com]
- To cite this document: BenchChem. [Navigating Renal Mass Diagnosis: A Comparative Guide to VM4-037 and Alternative Methods]. BenchChem, [2025]. [Online PDF]. Available at: [https://www.benchchem.com/product/b611697#assessing-the-diagnostic-accuracy-of-vm4-037-in-renal-masses]

Disclaimer & Data Validity:

The information provided in this document is for Research Use Only (RUO) and is strictly not intended for diagnostic or therapeutic procedures. While BenchChem strives to provide accurate protocols, we make no warranties, express or implied, regarding the fitness of this product for every specific experimental setup.

Technical Support: The protocols provided are for reference purposes. Unsure if this reagent suits your experiment? [[Contact our Ph.D. Support Team for a compatibility check](#)]

Need Industrial/Bulk Grade? [Request Custom Synthesis Quote](#)

BenchChem

Our mission is to be the trusted global source of essential and advanced chemicals, empowering scientists and researchers to drive progress in science and industry.

Contact

Address: 3281 E Guasti Rd

Ontario, CA 91761, United States

Phone: (601) 213-4426

Email: info@benchchem.com