

Navigating Liver Lesion Diagnosis: A Longitudinal Look at Gadoxetic Acid's Performance

Author: BenchChem Technical Support Team. **Date:** December 2025

Compound of Interest

Compound Name: *Gadoxetic acid*

Cat. No.: *B1262754*

[Get Quote](#)

For researchers, scientists, and drug development professionals, the accurate and early detection of liver lesions is paramount. **Gadoxetic acid** (Gd-EOB-DTPA), a hepatocyte-specific MRI contrast agent, has emerged as a powerful tool in this endeavor. This guide provides a comprehensive comparison of the longitudinal diagnostic performance of **Gadoxetic acid**-enhanced MRI (GA-MRI) against other imaging modalities, supported by experimental data and detailed protocols.

Gadoxetic acid's unique dual-phase enhancement, combining a dynamic vascular phase with a hepatobiliary phase (HBP), offers distinct advantages in the detection and characterization of liver lesions, particularly hepatocellular carcinoma (HCC).[1][2] This guide delves into the long-term efficacy of this contrast agent, providing valuable insights for clinical research and drug development.

Comparative Diagnostic Performance Over Time

Longitudinal studies are crucial for understanding how the diagnostic accuracy of an imaging modality holds up over time, especially in surveillance settings for high-risk patient populations.

Hepatocellular Carcinoma (HCC) Surveillance

In the critical area of HCC surveillance, GA-MRI has demonstrated sustained high performance. A key longitudinal study followed patients with indeterminate liver lesions (LI-

RADS 3) using GA-MRI. Over a median follow-up of 18.3 months, 41.6% of these lesions progressed to a higher-risk category (LR-4 or LR-5).[3] The cumulative risk of progression was 9.5% at 6 months, 17.3% at 12 months, and 37.3% at 24 months, highlighting the utility of GA-MRI in monitoring lesion evolution.[3]

Another study directly comparing GA-MRI with ultrasound for HCC surveillance at 6-month intervals found that GA-MRI had a significantly higher overall HCC detection rate (86.0%) compared to ultrasound (27.9%).[1] This suggests a superior and consistent performance of GA-MRI in a longitudinal surveillance program.

Longitudinal HCC Surveillance with GA-MRI	Follow-up Period	Key Findings	Reference
Indeterminate Lesion Progression (LR-3)	Median 18.3 months	41.6% of lesions progressed to LR-4 or LR-5.	[3]
6 months	Cumulative progression risk of 9.5%.	[3]	
12 months	Cumulative progression risk of 17.3%.	[3]	
24 months	Cumulative progression risk of 37.3%.	[3]	
GA-MRI vs. Ultrasound for HCC Detection	6-month intervals	GA-MRI detection rate: 86.0%; Ultrasound detection rate: 27.9%.	[1]

Cross-Sectional Comparisons with Other Modalities

While extensive head-to-head longitudinal studies are limited, cross-sectional data provides a strong basis for comparing the diagnostic performance of GA-MRI with MRI using extracellular

contrast agents (ECA-MRI) and multidetector computed tomography (MDCT).

A meta-analysis of eight prospective studies comparing GA-MRI and MDCT for HCC detection found that GA-MRI had a significantly higher sensitivity (85%) than MDCT (68%), with comparable specificity (94% vs. 93%).^[4] For lesions smaller than 2 cm, the sensitivity advantage of GA-MRI was even more pronounced (79% vs. 46%).^[4]

Comparisons between GA-MRI and ECA-MRI have yielded more nuanced results. One meta-analysis found that ECA-MRI had a higher per-lesion sensitivity for HCC diagnosis than GA-MRI (76% vs. 63%).^{[5][6]} However, another study focusing on recurrent HCC after multiple treatments found that ECA-MRI showed greater sensitivity and accuracy than GA-MRI.^[7] Conversely, for the detection of colorectal liver metastases, GA-MRI has been shown to perform significantly better than MDCT, particularly in patients who have undergone chemotherapy.^[8]

Modality Comparison for Liver Lesion Detection	Metric	Gadoxetic Acid-MRI (GA-MRI)	Extracellular Contrast Agent-MRI (ECA-MRI)	Multidetector CT (MDCT)	Reference
HCC Detection (Meta-analysis)	Sensitivity	85%	-	68%	[4]
	Specificity	-	93%	[4]	
HCC Detection < 2cm (Meta-analysis)	Sensitivity	79%	-	46%	[4]
HCC Diagnosis (Meta-analysis)	Per-lesion Sensitivity	63%	76%	-	[5] [6]
Recurrent HCC Detection	Sensitivity (Observer 1/2)	76.9% / 78.5%	90.9% / 91.7%	-	[7]
Accuracy (Observer 1/2)	78.7% / 80.2%	91.2% / 91.9%	-	[7]	
Colorectal Liver Metastases Detection (per-lesion)	Sensitivity (Reader 1/2/3)	95.5% / 90% / 96%	-	72% / 72% / 75%	[8]

Experimental Protocols

Understanding the methodologies behind these findings is crucial for their application in research and clinical trials.

Longitudinal Surveillance of Indeterminate Lesions

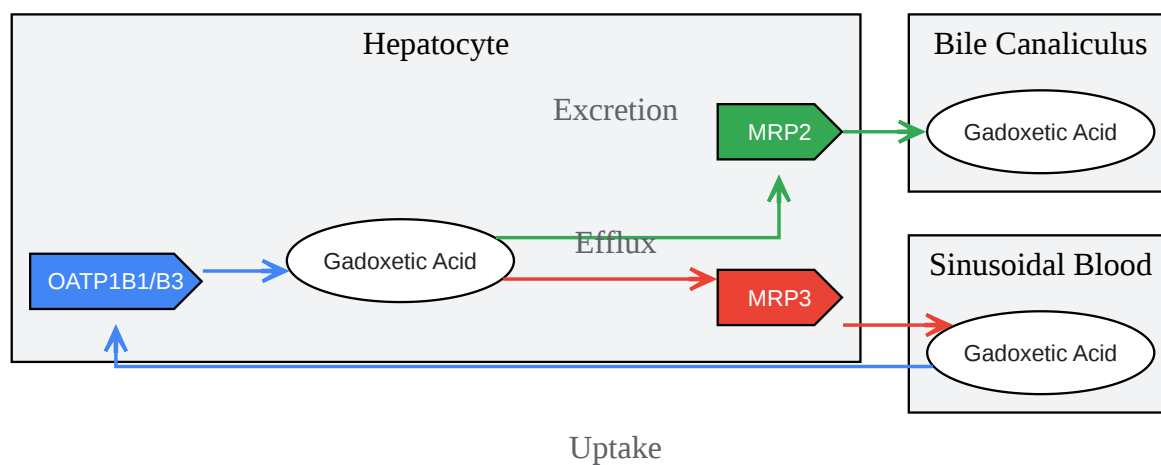
- Patient Population: Patients with indeterminate hepatic observations (LI-RADS category 3) less than 20 mm.
- Imaging Protocol: **Gadoxetic acid**-enhanced MRI (GA-MRI) performed at baseline and at follow-up intervals.
- Follow-up Schedule: Imaging performed at 3, 6, 12, and 24 months to assess for lesion progression, stability, or regression based on LI-RADS criteria.[\[3\]](#)
- Primary Endpoint: Progression of LR-3 observations to LR-4 or LR-5.

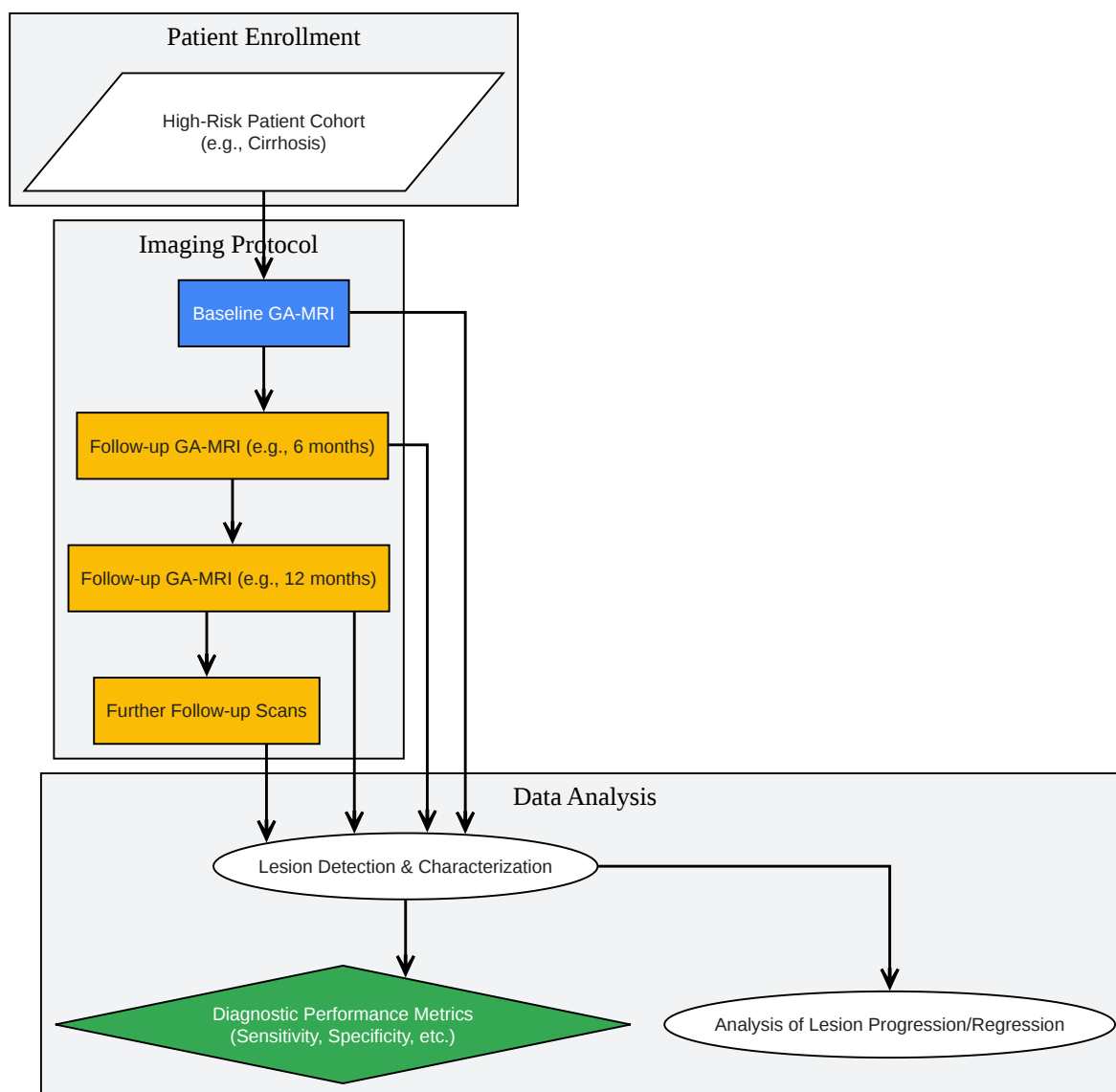
Comparative Study of GA-MRI and Ultrasound for HCC Surveillance

- Patient Population: Patients at high risk for HCC.
- Study Design: Paired screening rounds using both ultrasound and GA-MRI at 6-month intervals.
- Imaging Protocol: Standardized ultrasound examination and a full-protocol GA-MRI including dynamic and hepatobiliary phases.[\[1\]](#)
- Primary Endpoint: HCC detection rates for each modality.

Mechanism of Action: A Look at the Signaling Pathway

The diagnostic superiority of **Gadoxetic acid**, particularly in the hepatobiliary phase, is rooted in its specific cellular transport mechanism.





[Click to download full resolution via product page](#)

Need Custom Synthesis?

BenchChem offers custom synthesis for rare earth carbides and specific isotopic labeling.

Email: info@benchchem.com or [Request Quote Online](#).

References

- 1. The MR imaging diagnosis of liver diseases using gadoxetic acid: Emphasis on hepatobiliary phase - PMC [pmc.ncbi.nlm.nih.gov]
- 2. Recent Advances in the Imaging Diagnosis of Hepatocellular Carcinoma: Value of Gadoxetic Acid-Enhanced MRI - PMC [pmc.ncbi.nlm.nih.gov]
- 3. The role of gadoxetic acid as a paramagnetic contrast medium in the characterization and detection of focal liver lesions: a review - PMC [pmc.ncbi.nlm.nih.gov]
- 4. Gadoxetic acid-enhanced magnetic resonance imaging: Hepatocellular carcinoma and mimickers - PMC [pmc.ncbi.nlm.nih.gov]
- 5. researchgate.net [researchgate.net]
- 6. Quantitative Assessment of Liver Function Using Gadoxetate-Enhanced Magnetic Resonance Imaging: Monitoring Transporter-Mediated Processes in Healthy Volunteers - PMC [pmc.ncbi.nlm.nih.gov]
- 7. medscape.com [medscape.com]
- 8. Quantification of liver function using gadoxetic acid-enhanced MRI - PMC [pmc.ncbi.nlm.nih.gov]
- To cite this document: BenchChem. [Navigating Liver Lesion Diagnosis: A Longitudinal Look at Gadoxetic Acid's Performance]. BenchChem, [2025]. [Online PDF]. Available at: [https://www.benchchem.com/product/b1262754#longitudinal-studies-on-the-diagnostic-performance-of-gadoxetic-acid]

Disclaimer & Data Validity:

The information provided in this document is for Research Use Only (RUO) and is strictly not intended for diagnostic or therapeutic procedures. While BenchChem strives to provide accurate protocols, we make no warranties, express or implied, regarding the fitness of this product for every specific experimental setup.

Technical Support: The protocols provided are for reference purposes. Unsure if this reagent suits your experiment? [[Contact our Ph.D. Support Team for a compatibility check](#)]

Need Industrial/Bulk Grade? [Request Custom Synthesis Quote](#)

BenchChem

Our mission is to be the trusted global source of essential and advanced chemicals, empowering scientists and researchers to drive progress in science and industry.

Contact

Address: 3281 E Guasti Rd

Ontario, CA 91761, United States

Phone: (601) 213-4426

Email: info@benchchem.com