

# Navigating Adrenal Pathology: A Comparative Guide to 19-Iodocholesterol Imaging

**Author:** BenchChem Technical Support Team. **Date:** December 2025

## Compound of Interest

Compound Name: 19-Iodocholesterol 3-acetate

Cat. No.: B1208695

[Get Quote](#)

For researchers, scientists, and drug development professionals, the precise localization and functional characterization of adrenal lesions are critical. This guide provides an objective comparison of 19-Iodocholesterol imaging, specifically focusing on its most utilized derivative, 131I-6 $\beta$ -iodomethyl-19-norcholesterol (NP-59), against other diagnostic modalities. Supported by experimental data, this document aims to clarify its sensitivity, specificity, and procedural intricacies.

The landscape of adrenal imaging has evolved significantly, yet functional scintigraphy with radiolabeled cholesterol analogs remains a cornerstone for differentiating the underlying causes of adrenal hypersecretory states. While anatomical imaging techniques like Computed Tomography (CT) and Magnetic Resonance Imaging (MRI) excel at visualizing adrenal morphology, they often fall short in determining the functional status of identified nodules. This is where 19-Iodocholesterol imaging, particularly with NP-59, offers a unique advantage by providing physiological information based on cholesterol uptake and steroidogenesis.

## Quantitative Performance Analysis

The diagnostic accuracy of NP-59 scintigraphy varies depending on the specific adrenal pathology being investigated. The following table summarizes the sensitivity and specificity of NP-59 in various clinical contexts, alongside comparative data for other common diagnostic methods.

Imaging Modality	Condition	Sensitivity	Specificity	Positive Predictive Value (PPV)	Negative Predictive Value (NPV)	Accuracy	Citation(s)
NP-59 Scintigraphy	Primary Aldosteronism (APA)	83.3%	44.4%	92.3%	-	-	[1]
NP-59 SPECT/CT	Primary Aldosteronism (APA)	85.0%	60.0%	89.5%	-	-	[1]
NP-59 Scintigraphy	Adrenal Adenomas (in Primary Hyperaldosteronism)	85%	95%	-	-	-	[2]
NP-59 Scintigraphy	Cushing's Syndrome	-	-	-	-	100%	
NP-59 Scintigraphy	Primary Aldosteronism	-	-	-	-	71%	
NP-59 Scintigraphy	Hyperandrogenism	-	-	-	-	100%	
Unenhanced CT (<10 HU)	Adrenal Adenoma	71%	98%	-	-	-	[3][4]

Adrenal	Unilateral						
Venous	Primary	95%	100%	-	-	-	[5]
Sampling (AVS)	Aldostero nism						

APA: Aldosterone-Producing Adenoma; HU: Hounsfield Units; SPECT/CT: Single-Photon Emission Computed Tomography/Computed Tomography.

## Experimental Protocols

A standardized protocol is crucial for the successful implementation and interpretation of NP-59 adrenal scintigraphy. The following outlines a typical experimental workflow.

### Patient Preparation

- **Thyroid Blockade:** To prevent the uptake of free  $^{131}\text{I}$  by the thyroid gland, patients are administered a Lugol's solution or potassium iodide, starting two days before the tracer injection and continuing for several days after.
- **Dexamethasone Suppression (for Primary Aldosteronism and Hyperandrogenism):** To enhance the functional distinction between the adrenal cortex zones, patients may undergo dexamethasone suppression. A common regimen involves the oral administration of 4 mg of dexamethasone daily (1 mg every 6 hours) for seven days prior to the NP-59 injection and continuing until the final imaging session. This suppresses ACTH-dependent cortisol production in the zona fasciculata, thereby highlighting aldosterone or androgen-producing tissues.
- **Medication Review:** Certain medications that can interfere with the hypothalamic-pituitary-adrenal axis or cholesterol metabolism may need to be discontinued prior to the study.

### Tracer Administration and Imaging

- **Radiopharmaceutical:** A dose of 37 MBq (1 mCi) of  $^{131}\text{I}$ -6 $\beta$ -iodomethyl-19-norcholesterol (NP-59) is administered via a slow intravenous injection.
- **Imaging Acquisition:** Planar or SPECT/CT images are typically acquired at 72, 96, and 120 hours post-injection. Early imaging (before day 5) is often indicative of an aldosterone-

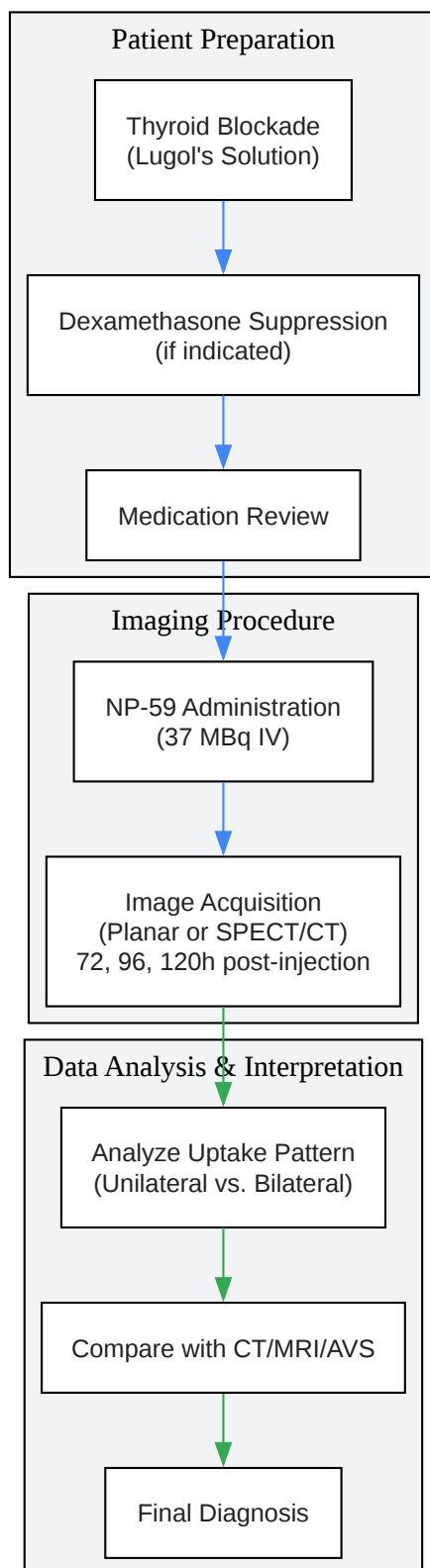
producing adenoma or bilateral adrenal hyperplasia.[1]

## Image Interpretation

- Unilateral Uptake: Early and unilateral visualization of the tracer is suggestive of an aldosterone-producing adenoma.
- Bilateral Uptake: Early and bilateral uptake is indicative of bilateral adrenal hyperplasia.
- Asymmetrical Uptake: Asymmetrical uptake on standard scintiscans may not reliably differentiate a tumor from asymmetrical hyperplasia unless the tumor is large.[3]
- Suppressed Contralateral Gland: In cases of a functioning adenoma causing Cushing's syndrome, the contralateral adrenal gland will typically show suppressed uptake.

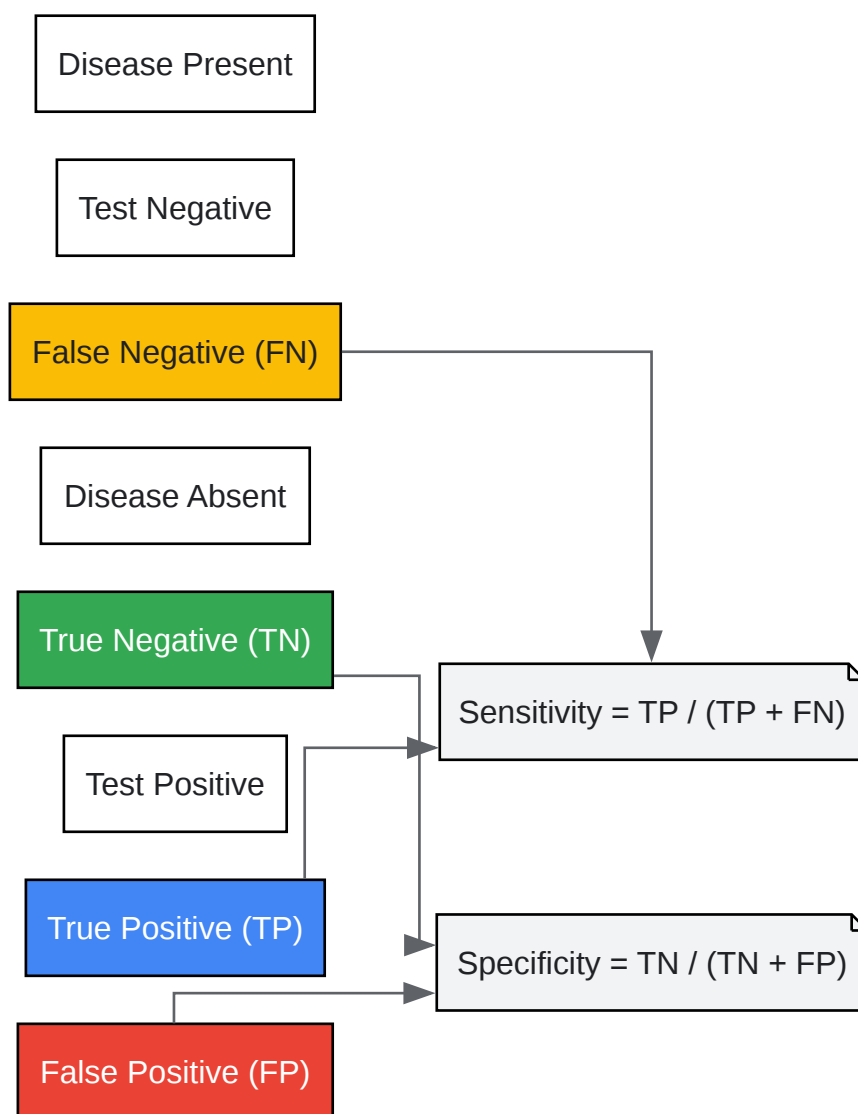
## Visualizing the Process

To further elucidate the experimental workflow and the principles of diagnostic evaluation, the following diagrams are provided.



[Click to download full resolution via product page](#)

Caption: Experimental workflow for NP-59 adrenal scintigraphy.



[Click to download full resolution via product page](#)

Caption: Calculation of sensitivity and specificity in diagnostic testing.

## Concluding Remarks

19-Iodocholesterol scintigraphy, particularly with NP-59, remains a valuable tool in the diagnostic armamentarium for functional adrenal disorders. Its ability to provide physiological data on adrenal cortical function is a distinct advantage over purely anatomical imaging modalities. While adrenal venous sampling is considered the gold standard for lateralizing aldosterone secretion, its invasive nature and technical demands make NP-59 scintigraphy a viable and often complementary non-invasive alternative. The addition of SPECT/CT has further enhanced the diagnostic accuracy of this technique by improving lesion localization. For

researchers and clinicians, a thorough understanding of the performance characteristics and experimental protocols of NP-59 imaging is essential for its appropriate application and the accurate interpretation of its findings in the complex evaluation of adrenal pathology.

#### Need Custom Synthesis?

BenchChem offers custom synthesis for rare earth carbides and specific isotopic labeling.

Email: [info@benchchem.com](mailto:info@benchchem.com) or [Request Quote Online](#).

## References

- 1. Is adrenal venous sampling always necessary to differentiate between unilateral and bilateral primary aldosteronism? Lesson from the SPAIN-ALDO register - PubMed [pubmed.ncbi.nlm.nih.gov]
- 2. auntminnie.com [auntminnie.com]
- 3. Adrenal imaging for adenoma characterization: imaging features, diagnostic accuracies and differential diagnoses - PMC [pmc.ncbi.nlm.nih.gov]
- 4. cdn.mdedge.com [cdn.mdedge.com]
- 5. researchgate.net [researchgate.net]
- To cite this document: BenchChem. [Navigating Adrenal Pathology: A Comparative Guide to 19-Iodocholesterol Imaging]. BenchChem, [2025]. [Online PDF]. Available at: [https://www.benchchem.com/product/b1208695#sensitivity-and-specificity-of-19-iodocholesterol-3-acetate-imaging]

---

### Disclaimer & Data Validity:

The information provided in this document is for Research Use Only (RUO) and is strictly not intended for diagnostic or therapeutic procedures. While BenchChem strives to provide accurate protocols, we make no warranties, express or implied, regarding the fitness of this product for every specific experimental setup.

**Technical Support:** The protocols provided are for reference purposes. Unsure if this reagent suits your experiment? [[Contact our Ph.D. Support Team for a compatibility check](#)]

**Need Industrial/Bulk Grade?** [Request Custom Synthesis Quote](#)

## BenchChem

Our mission is to be the trusted global source of essential and advanced chemicals, empowering scientists and researchers to drive progress in science and industry.

### Contact

Address: 3281 E Guasti Rd  
Ontario, CA 91761, United States  
Phone: (601) 213-4426  
Email: [info@benchchem.com](mailto:info@benchchem.com)