

MRI Excels in Pyomyositis Diagnosis: A Comparative Analysis Against CT Scans

Author: BenchChem Technical Support Team. **Date:** December 2025

Compound of Interest

Compound Name: *Piomy*

Cat. No.: *B1172056*

[Get Quote](#)

A definitive and early diagnosis of pyomyositis, a bacterial infection of skeletal muscle, is crucial to prevent significant morbidity. While both Magnetic Resonance Imaging (MRI) and Computed Tomography (CT) are utilized, MRI has emerged as the superior imaging modality due to its exceptional soft-tissue contrast and high sensitivity in detecting early inflammatory changes. This guide provides a detailed comparison of their diagnostic performance, supported by data from clinical studies, to assist researchers and clinicians in making informed decisions.

Magnetic resonance imaging is widely regarded as the first-line and gold standard imaging tool for pyomyositis.[1][2] Its high sensitivity allows for the detection of muscle inflammation and edema in the early stages of the disease.[3][4] Furthermore, MRI can accurately delineate the extent of the infection and identify associated complications like abscess formation or the involvement of adjacent bone and joints.[5][6]

Computed tomography serves as a valuable second-line alternative, particularly when MRI is contraindicated or unavailable.[1][7] CT is effective in identifying muscle enlargement, fluid collections, and rim enhancement characteristic of an abscess, especially with the use of intravenous contrast.[8][9][10] However, it is generally less sensitive than MRI for detecting early muscle inflammation and may not be as accurate in distinguishing between phlegmon and a drainable abscess.[2][7]

Comparative Diagnostic Performance

While direct head-to-head studies providing specific sensitivity and specificity percentages are limited, the existing literature consistently supports the superior diagnostic capability of MRI. A

review of findings from various studies highlights the key differences in their ability to characterize the features of pyomyositis.

Feature	Magnetic Resonance Imaging (MRI)	Computed Tomography (CT)
Overall Sensitivity	Very High; considered the modality of choice for its ability to detect early inflammation.[3][4][6]	Moderate to High; less sensitive than MRI for early-stage disease.[2][7]
Early Muscle Edema	Excellent detection via hyperintense signal on T2-weighted and STIR sequences.[3][5]	Poorly visualized; may only show subtle muscle enlargement.[9][10]
Abscess Detection	High. Clearly delineates fluid collections, which appear as localized, highly hyperintense areas on T2-weighted images.[5][8] Rim enhancement is distinct with contrast.[3][11]	High with contrast. Shows focal fluid collection with clear rim enhancement.[8][9][12]
Adjacent Tissue Involvement	Excellent for assessing the extent of infection into fascial planes, subcutaneous tissue, and bone marrow.[5][6]	Good for showing cellulitis and effacement of fat planes, but less sensitive for bone marrow involvement.[8][13]
Distinguishing Stages	Superior ability to differentiate the early invasive (phlegmonous) stage from the later suppurative (abscess) stage.[11]	Can be difficult to distinguish a phlegmon from a developing abscess without clear, well-defined rim enhancement.[7]
False Negatives	Rare.	More common, especially in early stages or for detecting concurrent osteomyelitis.[13]

Experimental Protocols

The diagnostic accuracy of both MRI and CT is highly dependent on the imaging protocol employed. Standardized protocols are essential for optimal visualization of pyomyositis characteristics.

MRI Protocol: A typical MRI protocol for suspected pyomyositis involves multiplanar imaging of the affected region.^[11]

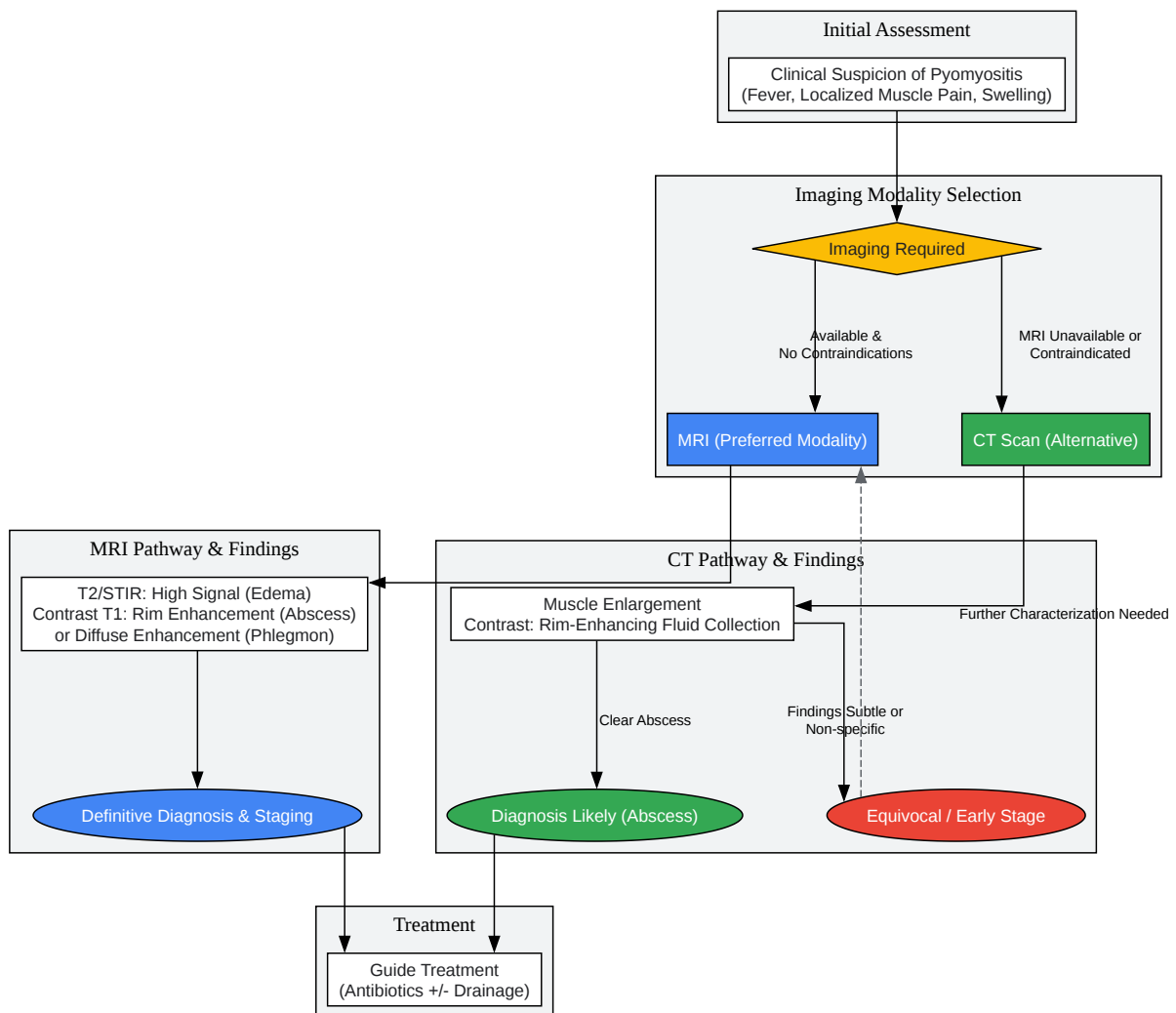
- **T1-Weighted Sequences:** These sequences are useful for anatomical detail. In pyomyositis, affected muscles may show a subtle increase in signal intensity.^[8]
- **T2-Weighted and/or Short Tau Inversion Recovery (STIR) Sequences:** These fluid-sensitive sequences are crucial and highly sensitive for detecting pathology. They demonstrate marked hyperintensity (brightness) in areas of muscle edema and inflammation.^{[3][5][6]}
- **Contrast-Enhanced T1-Weighted Sequences (with fat suppression):** Following the intravenous administration of a gadolinium-based contrast agent, these images are vital for identifying abscess formation. A mature abscess will typically show a characteristic peripheral rim of enhancement around a central non-enhancing fluid collection.^{[5][11]} Phlegmonous tissue will show more diffuse, heterogeneous enhancement.

CT Protocol: CT examinations for pyomyositis should ideally be performed with and without intravenous contrast to maximize diagnostic yield.

- **Non-Contrast CT:** This initial scan can reveal muscle enlargement and subtle changes in muscle density.
- **Contrast-Enhanced CT:** After administration of an iodinated contrast agent, scans reveal more specific findings. Affected muscles demonstrate heterogeneous attenuation.^[8] An abscess appears as a well-defined, low-density fluid collection with a distinct, enhancing rim.^{[9][12]} This enhancement is key to distinguishing an abscess from necrotic tissue.

Diagnostic Workflow and Logical Relationships

The selection between MRI and CT often depends on clinical suspicion, disease stage, and institutional resources. The following diagram illustrates the typical diagnostic workflow for a patient presenting with suspected pyomyositis.



[Click to download full resolution via product page](#)

Caption: Diagnostic workflow for pyomyositis comparing MRI and CT pathways.

In summary, while both imaging modalities play a role in the diagnosis of pyomyositis, MRI offers superior sensitivity and detailed tissue characterization, making it the definitive standard for diagnosis, staging, and guiding appropriate therapy. CT remains a viable and important alternative when MRI cannot be performed.

Need Custom Synthesis?

BenchChem offers custom synthesis for rare earth carbides and specific isotopic labeling.

Email: info@benchchem.com or [Request Quote Online](#).

References

- 1. droracle.ai [droracle.ai]
- 2. Imaging of Musculoskeletal Soft-Tissue Infections in Clinical Practice: A Comprehensive Updated Review - PMC [pmc.ncbi.nlm.nih.gov]
- 3. droracle.ai [droracle.ai]
- 4. droracle.ai [droracle.ai]
- 5. Magnetic resonance imaging of pyomyositis in 43 cases - PubMed [pubmed.ncbi.nlm.nih.gov]
- 6. Discrimination between tuberculous and bacterial pyomyositis in magnetic resonance features - PMC [pmc.ncbi.nlm.nih.gov]
- 7. droracle.ai [droracle.ai]
- 8. Pyomyositis: characteristics at CT and MR imaging - PubMed [pubmed.ncbi.nlm.nih.gov]
- 9. radiopaedia.org [radiopaedia.org]
- 10. AB0204 Early diagnosis and follow-up of pyomyositis by computed tomography | Annals of the Rheumatic Diseases [ard.bmj.com]
- 11. MRI of myositis and other urgent muscle-related disorders - PMC [pmc.ncbi.nlm.nih.gov]
- 12. pubs.rsna.org [pubs.rsna.org]
- 13. Imaging on pelvic pyomyositis in children related to pathogenesis - PMC [pmc.ncbi.nlm.nih.gov]
- To cite this document: BenchChem. [MRI Excels in Pyomyositis Diagnosis: A Comparative Analysis Against CT Scans]. BenchChem, [2025]. [Online PDF]. Available at:

[<https://www.benchchem.com/product/b1172056#mri-versus-ct-scan-for-the-diagnosis-of-pyomyositis-a-comparative-study>]

Disclaimer & Data Validity:

The information provided in this document is for Research Use Only (RUO) and is strictly not intended for diagnostic or therapeutic procedures. While BenchChem strives to provide accurate protocols, we make no warranties, express or implied, regarding the fitness of this product for every specific experimental setup.

Technical Support: The protocols provided are for reference purposes. Unsure if this reagent suits your experiment? [[Contact our Ph.D. Support Team for a compatibility check](#)]

Need Industrial/Bulk Grade? [Request Custom Synthesis Quote](#)

BenchChem

Our mission is to be the trusted global source of essential and advanced chemicals, empowering scientists and researchers to drive progress in science and industry.

Contact

Address: 3281 E Guasti Rd
Ontario, CA 91761, United States
Phone: (601) 213-4426
Email: info@benchchem.com