

Long-term effects and potential for retinal detachment with chronic Demecarium use

Author: BenchChem Technical Support Team. **Date:** December 2025

Compound of Interest

Compound Name: Demecarium

Cat. No.: B1199210

[Get Quote](#)

Technical Support Center: Demecarium and Retinal Health

For Researchers, Scientists, and Drug Development Professionals

This technical support center provides in-depth information, troubleshooting guides, and frequently asked questions regarding the long-term use of **Demecarium** and its potential association with retinal detachment.

Frequently Asked Questions (FAQs)

Q1: What is the established long-term risk of retinal detachment with chronic **Demecarium** use?

A: Retinal detachment is a recognized but rare adverse effect associated with the use of **Demecarium** bromide and other miotic agents.[1][2] While precise long-term incidence rates specifically for **Demecarium** are not readily available in the literature, studies on miotic therapy in general provide some insight. A case series of 34 eyes that developed retinal detachment during miotic therapy found that most of these eyes had pre-existing risk factors such as myopia (62%), aphakia (24%), or lattice degeneration (38%).[3] Another review of 1,000 retinal detachment cases investigated the proportion of patients who had been using miotics.[4] It has been reported that over 100 cases of potential miotic-related retinal detachments have been documented in scientific literature.[5]

Q2: What is the proposed mechanism for **Demecarium**-induced retinal detachment?

A: The leading hypothesis is that **Demecarium**, a potent, long-acting cholinesterase inhibitor, induces strong and sustained contraction of the ciliary muscle.[6] This contraction can increase tension on the zonular fibers and the vitreous base, leading to vitreoretinal traction.[5][7] In eyes with pre-existing retinal lesions or vitreoretinal adhesions, this traction can lead to the formation of retinal tears and subsequent rhegmatogenous retinal detachment.[8]

Q3: Are there specific patient populations at higher risk for this adverse event?

A: Yes, research indicates that individuals with certain pre-existing ocular conditions are at a higher risk of developing retinal detachment during miotic therapy.[3][8] These risk factors include:

- Myopia (nearsightedness): Particularly high myopia, which is often associated with a thinner peripheral retina and lattice degeneration.[3]
- Aphakia or Pseudophakia: The absence of the natural lens or the presence of an artificial intraocular lens can alter the anatomical relationship between the vitreous and the retina.[3][8]
- History of Retinal Detachment: A personal or family history of retinal detachment increases susceptibility.
- Lattice Degeneration: This condition involves thinning of the peripheral retina, making it more prone to tears.[3]

Q4: What are the early warning signs of retinal detachment that researchers should monitor for in preclinical or clinical studies involving **Demecarium**?

A: Key symptoms to monitor include:

- Photopsia: Sudden onset of flashes of light in the peripheral vision.
- Floaters: A sudden increase in the number or size of floaters, which may appear as spots, lines, or cobwebs in the field of vision.

- Visual Field Defect: A curtain-like shadow or dark area progressing across the visual field.
- Blurred Vision: A sudden decrease in visual acuity.

Prompt recognition of these symptoms is critical for timely intervention.

Troubleshooting Guides for Experimental Studies

Issue: Unexpected changes in retinal morphology observed in animal models during chronic **Demecarium** administration.

Troubleshooting Steps:

- Baseline Retinal Examination: Ensure comprehensive baseline retinal examinations, including indirect ophthalmoscopy and optical coherence tomography (OCT), were performed on all animals prior to drug administration to rule out pre-existing retinal abnormalities.
- Dose-Response Evaluation: Assess if the observed changes are dose-dependent. Consider reducing the concentration or frequency of **Demecarium** administration.
- Intraocular Pressure (IOP) Monitoring: Chronically elevated or fluctuating IOP can contribute to retinal pathology. Ensure IOP is monitored regularly in both control and treated groups.
- Vitreous Assessment: Utilize techniques like B-scan ultrasonography or OCT to evaluate for changes in the vitreous, such as posterior vitreous detachment (PVD) or vitreous opacities, which may precede retinal detachment.[2]
- Histopathology: At the end of the study, perform detailed histopathological analysis of the retina, ciliary body, and vitreous to identify cellular and structural changes.

Issue: Difficulty in differentiating between **Demecarium**-induced retinal changes and artifacts in in vitro retinal pigment epithelium (RPE) cell culture models.

Troubleshooting Steps:

- Cell Line Validation: Ensure the RPE cell line used expresses the appropriate cholinergic receptors (muscarinic and nicotinic) to be a valid model for studying **Demecarium**'s effects.

[6][9][10][11]

- **Toxicity Assays:** Employ a battery of cytotoxicity assays (e.g., MTT, LDH) to determine the direct toxic potential of **Demecarium** on RPE cells.
- **Barrier Function Assessment:** Measure the transepithelial electrical resistance (TEER) of the RPE monolayer to assess the integrity of the outer blood-retinal barrier, as its disruption can be an early sign of toxicity.
- **Phagocytosis Assay:** Evaluate the phagocytic activity of the RPE cells, a key physiological function that can be impaired by toxic insults.
- **Control Compounds:** Include appropriate positive and negative control compounds in your experiments to validate the experimental system. For example, a known retinal toxicant and an inactive compound.

Quantitative Data Summary

Study Type	Population/Model	Key Findings	Reference
Case Series	31 patients (34 eyes) with retinal detachment on miotic therapy	62% of eyes were myopic; 24% were aphakic; 38% had ipsilateral lattice degeneration.	[3]
Literature Review	Published case reports	Over 100 cases of potential miotic-related retinal detachments have been reported.	[5]
Animal Study	Beagles with normotensive and glaucomatous eyes	Demecarium bromide (0.125% and 0.25%) induced long-term miosis and decreased IOP.	[12]
Animal Study	Cynomolgus monkeys	Chronic echothiophate (a similar cholinesterase inhibitor) use led to a decrease in muscarinic receptors in the ciliary muscle.	[13]

Experimental Protocols

Protocol 1: In Vitro Assessment of **Demecarium**'s Effect on Retinal Pigment Epithelium (RPE) Barrier Function

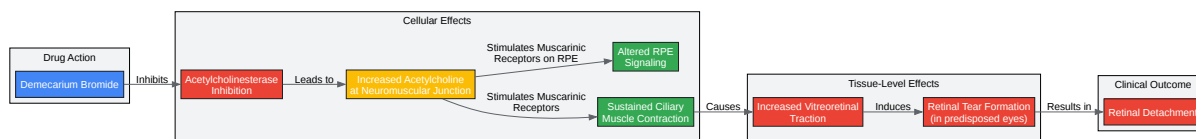
- Cell Culture: Culture a human RPE cell line (e.g., ARPE-19) on permeable supports (e.g., Transwell inserts) until a confluent monolayer with stable transepithelial electrical resistance (TEER) is formed.

- **Treatment:** Treat the RPE monolayers with varying concentrations of **Demecarium** bromide (and appropriate vehicle controls) applied to the apical chamber.
- **TEER Measurement:** Measure TEER at regular intervals (e.g., 0, 24, 48, 72 hours) to assess the integrity of the RPE barrier. A significant decrease in TEER indicates a disruption of tight junctions.
- **Permeability Assay:** At the end of the treatment period, add a fluorescently labeled tracer molecule (e.g., sodium fluorescein) to the apical chamber and measure its flux into the basal chamber over time to quantify paracellular permeability.
- **Immunocytochemistry:** Fix the RPE monolayers and perform immunofluorescent staining for tight junction proteins (e.g., ZO-1, occludin) to visualize any disruption in their localization and organization.

Protocol 2: Ex Vivo Model to Assess Ciliary Muscle Contraction and Vitreoretinal Interface

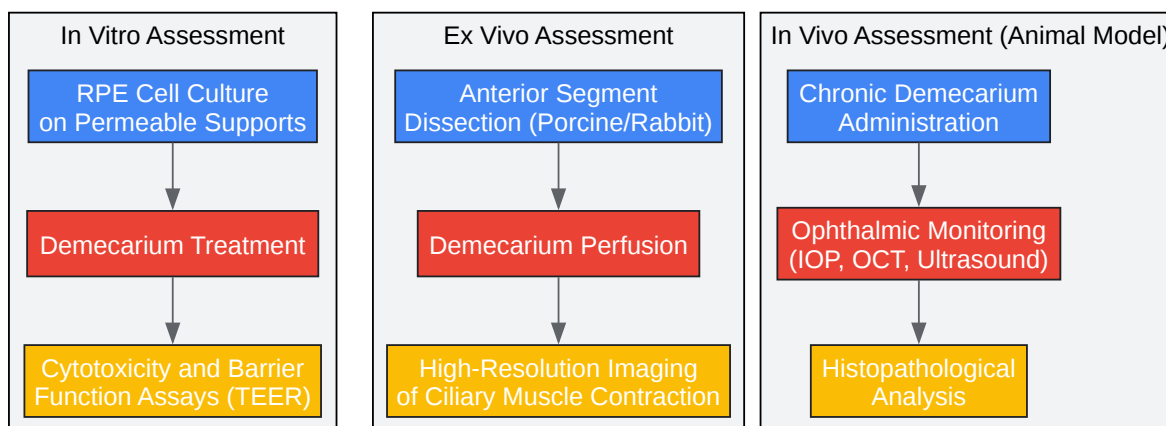
- **Tissue Preparation:** Obtain fresh porcine or rabbit eyes. Carefully dissect the anterior segment, preserving the ciliary body, zonules, and the anterior vitreous.
- **Mounting:** Mount the tissue in a specialized chamber that allows for the visualization and measurement of ciliary body movement and its effect on the vitreous.
- **Treatment:** Perfuse the chamber with a solution containing **Demecarium** bromide to induce ciliary muscle contraction.
- **Imaging:** Use high-resolution imaging techniques, such as a dissecting microscope with a camera or a custom imaging setup, to record the contraction of the ciliary muscle and any subsequent displacement or traction on the anterior vitreous.
- **Analysis:** Quantify the degree of ciliary muscle contraction and the resulting forces exerted on the vitreous using image analysis software.

Visualizations



[Click to download full resolution via product page](#)

Caption: Proposed signaling pathway for **Demecarium**-induced retinal detachment.



[Click to download full resolution via product page](#)

Caption: Experimental workflow for assessing **Demecarium**-induced retinal toxicity.

Need Custom Synthesis?

BenchChem offers custom synthesis for rare earth carbides and specific isotopic labeling.

Email: info@benchchem.com or [Request Quote Online](#).

References

- 1. Retinal detachments and topical ocular miotics - PubMed [pubmed.ncbi.nlm.nih.gov]
- 2. Quantitative analysis of vitreous changes in intraocular inflammation following faricimab treatment in a real world setting - PMC [pmc.ncbi.nlm.nih.gov]
- 3. Retinal detachment and miotic therapy - PubMed [pubmed.ncbi.nlm.nih.gov]
- 4. scholars.mssm.edu [scholars.mssm.edu]
- 5. An Evidence Based Guide to Retinal Complications and Miotics | Presbyopia Physician [presbyopiaphysician.com]
- 6. Muscarinic Acetylcholine Receptors in the Retina—Therapeutic Implications - PMC [pmc.ncbi.nlm.nih.gov]
- 7. researchgate.net [researchgate.net]
- 8. Miotics and retinal detachment: upgrading the community standard - PubMed [pubmed.ncbi.nlm.nih.gov]
- 9. iovs.arvojournals.org [iovs.arvojournals.org]
- 10. digital.library.txst.edu [digital.library.txst.edu]
- 11. Activation of muscarinic acetylcholine receptors elicits pigment granule dispersion in retinal pigment epithelium isolated from bluegill - PMC [pmc.ncbi.nlm.nih.gov]
- 12. Effect of topically applied demecarium bromide and echothiophate iodide on intraocular pressure and pupil size in beagles with normotensive eyes and beagles with inherited glaucoma - PubMed [pubmed.ncbi.nlm.nih.gov]
- 13. Cholinergic drugs alter ciliary muscle response and receptor content - PubMed [pubmed.ncbi.nlm.nih.gov]
- To cite this document: BenchChem. [Long-term effects and potential for retinal detachment with chronic Demecarium use]. BenchChem, [2025]. [Online PDF]. Available at: [https://www.benchchem.com/product/b1199210#long-term-effects-and-potential-for-retinal-detachment-with-chronic-demecarium-use]

Disclaimer & Data Validity:

The information provided in this document is for Research Use Only (RUO) and is strictly not intended for diagnostic or therapeutic procedures. While BenchChem strives to provide accurate protocols, we make no warranties, express or implied, regarding the fitness of this product for every specific experimental setup.

Technical Support: The protocols provided are for reference purposes. Unsure if this reagent suits your experiment? [[Contact our Ph.D. Support Team for a compatibility check](#)]

Need Industrial/Bulk Grade? [Request Custom Synthesis Quote](#)

BenchChem

Our mission is to be the trusted global source of essential and advanced chemicals, empowering scientists and researchers to drive progress in science and industry.

Contact

Address: 3281 E Guasti Rd
Ontario, CA 91761, United States
Phone: (601) 213-4426
Email: info@benchchem.com