

Long-term complications associated with posterior sclerotomy and their management.

Author: BenchChem Technical Support Team. **Date:** December 2025

Compound of Interest

Compound Name: CP-67015

Cat. No.: B1669555

[Get Quote](#)

Technical Support Center: Posterior Sclerotomy Complications

This technical support center provides troubleshooting guides and frequently asked questions (FAQs) regarding long-term complications associated with posterior sclerotomy. The information is tailored for researchers, scientists, and drug development professionals.

FAQs and Troubleshooting Guides

1. Hypotony (Low Intraocular Pressure)

Q1: What is post-sclerotomy hypotony and what are the long-term risks?

A: Post-sclerotomy hypotony is characterized by a persistent low intraocular pressure (IOP), generally defined as an IOP of 5 mmHg or less.^[1] In the long term, chronic hypotony can lead to complications such as choroidal detachment, hypotonous maculopathy with vision loss, and even phthisis bulbi (shrinkage of the eyeball).^[2]

Q2: What are the common causes of long-term hypotony after posterior sclerotomy?

A: Long-term hypotony can arise from several factors, including:

- **Persistent Wound Leak:** Inadequate healing or closure of the sclerotomy site can lead to continuous leakage of aqueous humor.^[3]

- **Overfiltration:** In cases of glaucoma filtering surgery, the sclerotomy may allow for excessive drainage of aqueous humor.[\[4\]](#)
- **Ciliary Body Shutdown:** Inflammation or trauma to the ciliary body during the procedure can reduce aqueous humor production.
- **Retinal Detachment:** The presence of a retinal detachment can also be associated with hypotony.[\[5\]](#)

Q3: Our experimental model is showing a high incidence of early post-operative hypotony. What factors should we investigate?

A: Early postoperative hypotony is a known complication. A retrospective study on 23-gauge transconjunctival sutureless vitrectomy identified myopia and the use of gas tamponade as risk factors for early postoperative hypotony.[\[1\]](#)[\[6\]](#) The incidence in this study was 11.3% at 2 hours, 6.5% at 5 hours, and 3.8% at 1 day post-operation.[\[1\]](#)[\[6\]](#) Another study on 25-gauge vitrectomy found an incidence of 53% on the first day post-operatively in the control group.[\[7\]](#)

Troubleshooting Guide: Managing Hypotony

Issue	Potential Cause	Recommended Action
Sustained low IOP (<5 mmHg) with a shallow anterior chamber	Wound leak at the sclerotomy site	<p>- Initial Assessment: Carefully inspect the sclerotomy site for leakage using a fluorescein strip (Seidel test).-</p> <p>Conservative Management: Application of a bandage contact lens or pressure patching.[4]- Surgical Intervention: If conservative measures fail, surgical revision of the sclerotomy site with sutures may be necessary.</p>
Low IOP with choroidal detachment	Transudation of fluid into the suprachoroidal space	<p>- Medical Management: Topical cycloplegics (e.g., atropine) and steroids to reduce inflammation and deepen the anterior chamber.[4][8]- Surgical Drainage: If the choroidal detachment is extensive ("kissing choroidals") or persistent, surgical drainage of the suprachoroidal fluid is indicated.[8]</p>
Chronically low IOP with visual decline	Hypotonous maculopathy	<p>- Management: The primary goal is to resolve the underlying cause of the hypotony. Vitrectomy with silicone oil tamponade may be considered in refractory cases to stabilize the eye and IOP.[5]</p>

Quantitative Data on Post-Sclerotomy Hypotony

Study Focus	Incidence of Hypotony	Key Findings/Risk Factors	Citation
23-gauge transconjunctival sutureless vitrectomy	11.3% at 2 hours, 6.5% at 5 hours, 3.8% at 1 day	Myopia, gas tamponade	[1][6]
25-gauge vitrectomy	53% on day 1 (control group), 16% on day 1 (vitreous nettoyage group)	Vitreous plugging of the sclerotomy	[7]
Deep sclerectomy with T-flux implant in pseudoexfoliative glaucoma	10% (IOP < 5 mmHg)	-	[9]

2. Choroidal Detachment

Q1: What is the mechanism of choroidal detachment following posterior sclerotomy?

A: Choroidal detachment, also known as choroidal effusion, occurs when fluid accumulates in the suprachoroidal space, the potential space between the choroid and the sclera. This is often a consequence of postoperative hypotony.[8] Reduced IOP can lead to the breakdown of the blood-aqueous barrier and transudation of fluid from the choriocapillaris. In some cases, such as in Sturge-Weber syndrome, high choroidal vascular pressure can exacerbate this issue after IOP-lowering surgery.[10]

Q2: When is intervention required for a post-sclerotomy choroidal detachment?

A: Many choroidal detachments are self-limiting and resolve spontaneously as the IOP normalizes.[8] However, surgical intervention is indicated in cases of:

- "Kissing" Choroidals: When the detachments are large enough to touch in the center of the vitreous cavity.[11]
- Flat Anterior Chamber: If the detachment is causing the anterior chamber to become shallow, leading to lens-cornea touch.[12]

- Persistent Detachment: If the detachment does not resolve within a reasonable timeframe (e.g., 2-4 weeks), as it can lead to failure of filtering surgery.[8]

Troubleshooting Guide: Managing Choroidal Detachment

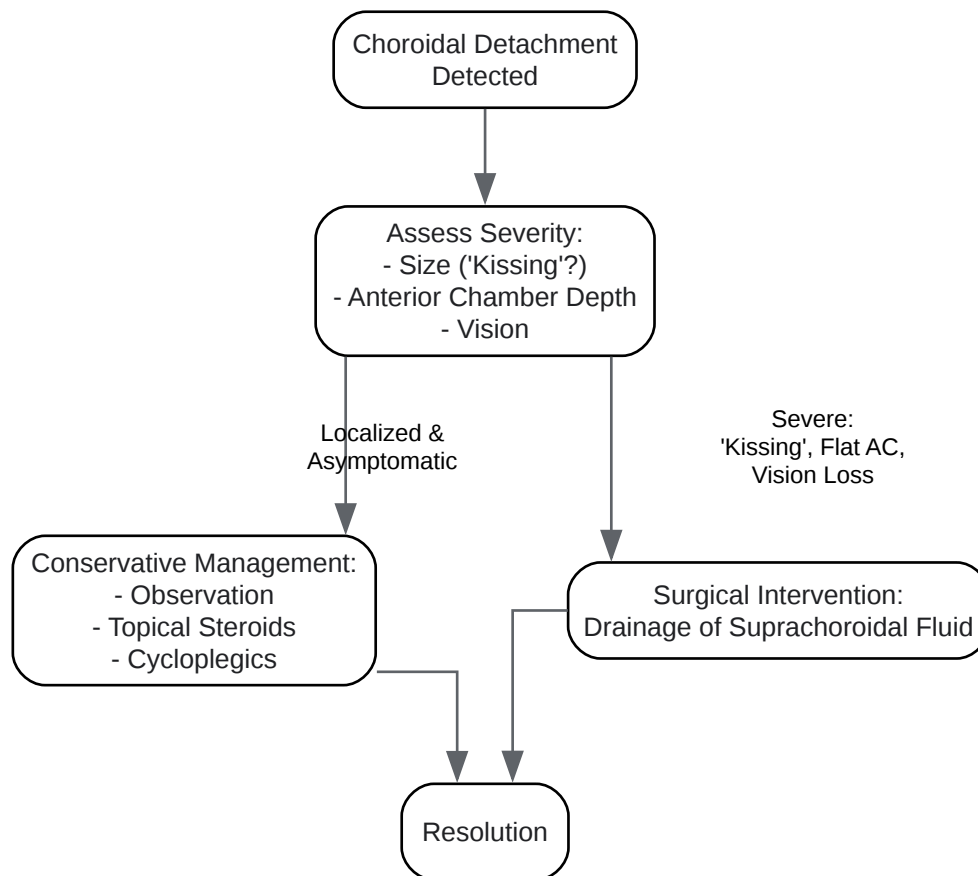
Issue	Clinical Presentation	Recommended Action
Asymptomatic, localized choroidal detachment	Serous elevation of the choroid, often in the periphery. Normal or slightly shallow anterior chamber.	- Conservative Management: Observation, topical steroids, and cycloplegics.[8]
Symptomatic, large choroidal detachment	"Kissing" choroidals, shallow or flat anterior chamber, decreased vision.	- Surgical Drainage: Perform a posterior sclerotomy to drain the suprachoroidal fluid.[8][12] This can be combined with reformation of the anterior chamber with a viscoelastic substance or balanced salt solution.[12][13]

Experimental Protocol: Drainage of Suprachoroidal Fluid

- Preparation: Administer appropriate local or general anesthesia.
- Paracentesis: Create a paracentesis in the peripheral cornea to allow for reformation of the anterior chamber.[12]
- Sclerotomy Incision: Make a 2-3 mm circumferential incision through the sclera, 6-10 mm posterior to the limbus, in the quadrant with the largest detachment.[13]
- Fluid Drainage: Allow for spontaneous drainage of the straw-colored suprachoroidal fluid. Gentle pressure on the surrounding sclera can aid drainage.[12]
- Anterior Chamber Reformation: Inject a balanced salt solution or viscoelastic through the previously created paracentesis to maintain a normal anterior chamber depth.[12][13]

- Closure: The sclerotomy may be closed with an "X" suture using 9-0 polyglactin, although some surgeons may not close it.[8] Close the conjunctiva with a running suture.[8]

Logical Relationship of Choroidal Detachment Management



[Click to download full resolution via product page](#)

Caption: Management workflow for choroidal detachment.

3. Endophthalmitis

Q1: What is the risk of endophthalmitis after posterior sclerotomy, and what are the common causative organisms?

A: Endophthalmitis is a severe intraocular inflammation, usually caused by infection. The incidence following vitrectomy is estimated to be between 0.02% and 0.06%.[3] Risk factors include inadequate wound closure (leaky sclerotomies), vitreous incarceration at the wound site, and contamination of surgical instruments.[3][14] The most commonly implicated

organisms in postoperative endophthalmitis are Streptococcus species, followed by Haemophilus influenzae and coagulase-negative staphylococci.[3]

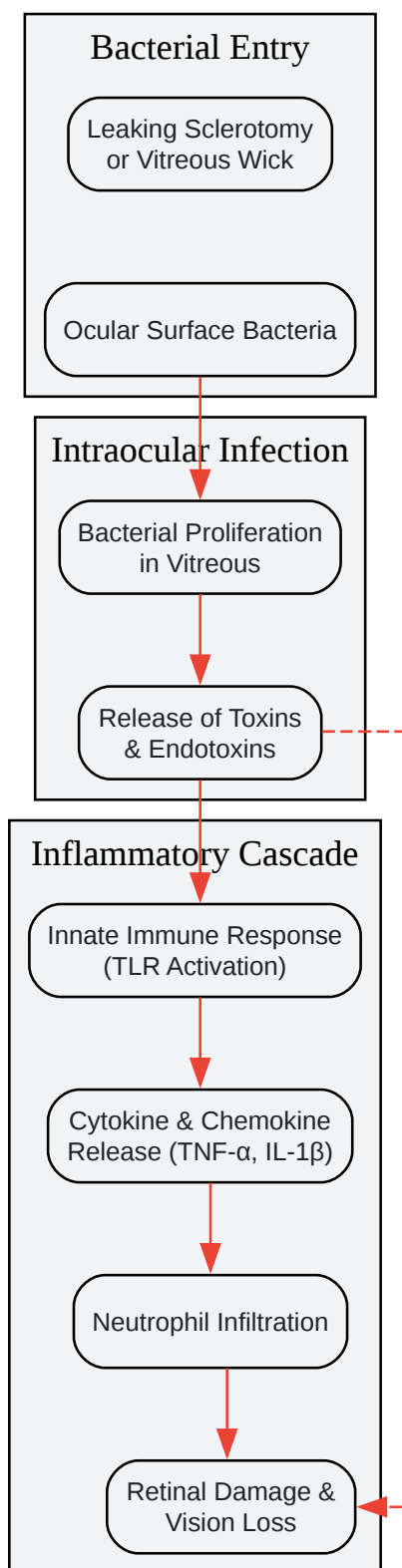
Q2: How does a "vitreous wick" contribute to the risk of endophthalmitis?

A: A vitreous wick occurs when a strand of vitreous prolapses through the sclerotomy site to the ocular surface.[15] This creates a direct conduit for bacteria from the ocular surface to enter the sterile intraocular environment, significantly increasing the risk of endophthalmitis.[14] This can occur after various procedures including cataract surgery, intravitreal injections, and sutureless vitrectomy.[15]

Troubleshooting Guide: Suspected Endophthalmitis

Issue	Signs & Symptoms	Recommended Action
Acute post-operative inflammation	Increasing eye pain, significant redness, decreased vision, hypopyon (pus in the anterior chamber), vitritis.[16]	<p>- Immediate Action: This is a medical emergency.[17]-</p> <p>Vitreous Tap: Obtain a vitreous sample for culture and sensitivity testing.- Intravitreal Antibiotics: Administer broad-spectrum intravitreal antibiotics (e.g., vancomycin and ceftazidime).[18]- Vitrectomy: In severe cases, a pars plana vitrectomy may be necessary to remove the infectious material and inflammatory debris.[17]</p>

Signaling Pathway of Endophthalmitis Pathogenesis



[Click to download full resolution via product page](#)

Caption: Pathogenesis of post-sclerotomy endophthalmitis.

4. Scleral Thinning and Uveal Prolapse

Q1: Can posterior sclerotomy lead to long-term scleral thinning?

A: Yes, scleral thinning or melting is a rare but serious long-term complication that can occur at the sclerotomy site.^[19] It can be associated with underlying conditions that compromise scleral integrity, such as high myopia or glaucoma, or the use of adjunctive therapies like Mitomycin-C (MMC), which can impair wound healing.^{[19][20]}

Q2: What is the clinical significance of scleral thinning?

A: Progressive scleral thinning can lead to structural weakening of the globe.^[21] If it progresses to a full-thickness defect, it can result in uveal prolapse, where the underlying uveal tissue (iris, ciliary body, or choroid) bulges through the thinned sclera.^[19] This is an ocular emergency that requires prompt surgical management to prevent complications like endophthalmitis.^[19]

Troubleshooting Guide: Managing Scleral Thinning

Issue	Clinical Presentation	Recommended Action
Asymptomatic scleral thinning	Localized area of scleral translucency with visible underlying choroid.	<ul style="list-style-type: none">- Observation: Regular monitoring for progression.^[20]- Medical Management: If associated with inflammation, topical steroids or immunosuppressants may be used.^[21]
Progressive scleral thinning or uveal prolapse	Visible bulge of dark uveal tissue through the sclera, often with conjunctival injection.	<ul style="list-style-type: none">- Surgical Repair: Reinforcement of the thinned sclera with a patch graft (e.g., donor sclera, pericardium, or amniotic membrane).^{[19][21]}

5. Retinal Detachment

Q1: How can a posterior sclerotomy lead to a retinal detachment?

A: A retinal detachment can occur as a long-term complication of posterior sclerotomy through several mechanisms:

- **Sclerotomy-Related Retinal Breaks:** The instruments used to create the sclerotomy can cause iatrogenic retinal tears, either at the time of surgery or later due to vitreous traction. [22][23] A study on 23-gauge vitrectomy found a 1.6% rate of sclerotomy-associated retinal breaks.[22]
- **Vitreous Incarceration:** Vitreous incarcerated in the sclerotomy wound can exert traction on the peripheral retina, leading to the formation of a retinal tear and subsequent detachment. [24][25][26]
- **Hypotony:** Chronic hypotony can lead to chorioretinal folds and, in some cases, contribute to retinal detachment.[27]

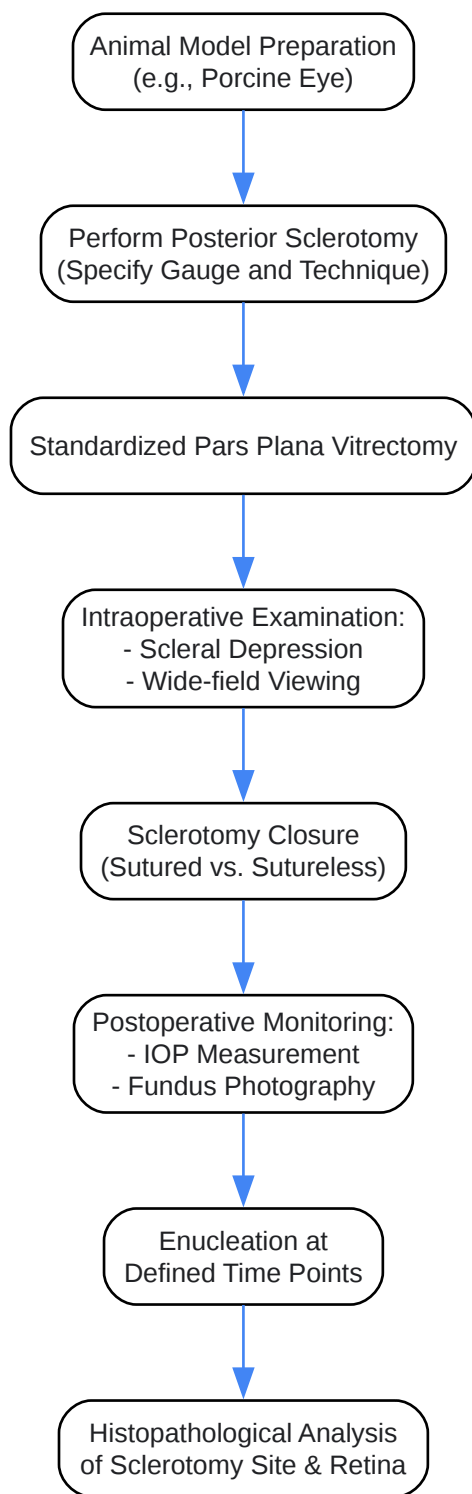
Q2: What are the symptoms of a post-sclerotomy retinal detachment?

A: The symptoms are the same as for other types of retinal detachment and include a sudden increase in floaters, flashes of light (photopsia), or a curtain-like shadow in the field of vision. [28][29] Any of these symptoms warrant immediate ophthalmological evaluation.

Troubleshooting Guide: Post-Sclerotomy Retinal Detachment

Issue	Clinical Presentation	Recommended Action
New onset of floaters, flashes, or visual field defect	Ophthalmoscopy reveals a retinal tear or detachment.	- Surgical Repair: The management depends on the type and location of the detachment. Options include pars plana vitrectomy, scleral buckling, or pneumatic retinopexy.[28][29]

Experimental Workflow for Investigating Sclerotomy-Related Retinal Breaks in an Animal Model



[Click to download full resolution via product page](#)

Caption: Workflow for studying sclerotomy-related retinal breaks.

Need Custom Synthesis?

BenchChem offers custom synthesis for rare earth carbides and specific isotopic labeling.

Email: info@benchchem.com or [Request Quote Online](#).

References

- 1. researchgate.net [researchgate.net]
- 2. Late hypotony as a complication of viscocanalostomy: a case report - PubMed [pubmed.ncbi.nlm.nih.gov]
- 3. emedicine.medscape.com [emedicine.medscape.com]
- 4. Management of complications in glaucoma surgery - PMC [pmc.ncbi.nlm.nih.gov]
- 5. Ocular Hypotony Treatment & Management: Medical Care, Surgical Care, Consultations [emedicine.medscape.com]
- 6. Risk factors associated with sclerotomy leakage and postoperative hypotony after 23-gauge transconjunctival sutureless vitrectomy - PubMed [pubmed.ncbi.nlm.nih.gov]
- 7. iovs.arvojournals.org [iovs.arvojournals.org]
- 8. ophthalmologytimes.com [ophthalmologytimes.com]
- 9. researchgate.net [researchgate.net]
- 10. Posterior sclerectomy for persistent serous retinal detachment with secondary glaucoma in Sturge–Weber syndrome: A case report - PMC [pmc.ncbi.nlm.nih.gov]
- 11. reviewofophthalmology.com [reviewofophthalmology.com]
- 12. emedicine.medscape.com [emedicine.medscape.com]
- 13. Ab Externo Choroidal Fluid Drainage, Pars Plana Vitrectomy, and Endotamponade for the Management of Persistent Hypotony following Glaucoma Surgery - PMC [pmc.ncbi.nlm.nih.gov]
- 14. Endophthalmitis following pars plana vitrectomy: a literature review of incidence, causative organisms, and treatment outcomes - PMC [pmc.ncbi.nlm.nih.gov]
- 15. educate.choroida.com [educate.choroida.com]
- 16. reviewofophthalmology.com [reviewofophthalmology.com]
- 17. my.clevelandclinic.org [my.clevelandclinic.org]

- 18. Four cases of endophthalmitis after 25-gauge pars plana vitrectomy - PMC [pmc.ncbi.nlm.nih.gov]
- 19. Scleral melt and uveal prolapse following 23-gauge pars plana vitrectomy - PMC [pmc.ncbi.nlm.nih.gov]
- 20. Scleral Thinning | Vagelos College of Physicians and Surgeons [vagelos.columbia.edu]
- 21. Scleral thinning causes, diagnosis, and management: A narrative review - PubMed [pubmed.ncbi.nlm.nih.gov]
- 22. iovs.arvojournals.org [iovs.arvojournals.org]
- 23. Vitreous surgery. XIV. Complications from sclerotomy in 89 consecutive cases - PubMed [pubmed.ncbi.nlm.nih.gov]
- 24. Influence of sclerotomy use on vitreous incarceration in an experimental model of vitrectomized eye - PMC [pmc.ncbi.nlm.nih.gov]
- 25. VITREOUS INCARCERATION IN SCLEROTOMIES AFTER VALVED 23-, 25-, OR 27-GAUGE AND NONVALVED 23- OR 25-GAUGE MACULAR SURGERY - PMC [pmc.ncbi.nlm.nih.gov]
- 26. youtube.com [youtube.com]
- 27. Uncommon Complication Post-deep Sclerectomy: Giant Retinal Tear - PMC [pmc.ncbi.nlm.nih.gov]
- 28. dmei.org [dmei.org]
- 29. Detached retina (retinal detachment) - NHS [nhs.uk]
- To cite this document: BenchChem. [Long-term complications associated with posterior sclerotomy and their management.]. BenchChem, [2025]. [Online PDF]. Available at: [https://www.benchchem.com/product/b1669555#long-term-complications-associated-with-posterior-sclerotomy-and-their-management]

Disclaimer & Data Validity:

The information provided in this document is for Research Use Only (RUO) and is strictly not intended for diagnostic or therapeutic procedures. While BenchChem strives to provide accurate protocols, we make no warranties, express or implied, regarding the fitness of this product for every specific experimental setup.

Technical Support: The protocols provided are for reference purposes. Unsure if this reagent suits your experiment? [[Contact our Ph.D. Support Team for a compatibility check](#)]

Need Industrial/Bulk Grade? [Request Custom Synthesis Quote](#)

BenchChem

Our mission is to be the trusted global source of essential and advanced chemicals, empowering scientists and researchers to drive progress in science and industry.

Contact

Address: 3281 E Guasti Rd
Ontario, CA 91761, United States
Phone: (601) 213-4426
Email: info@benchchem.com