

Long-Term Outcomes of Deep Anterior Lamellar Keratoplasty (DALK): A Technical Guide

Author: BenchChem Technical Support Team. **Date:** December 2025

Compound of Interest

Compound Name: dALK-3

Cat. No.: B15575147

[Get Quote](#)

For Researchers, Scientists, and Drug Development Professionals

Introduction

Deep Anterior Lamellar Keratoplasty (DALK) is a corneal transplantation technique that involves the selective removal and replacement of the corneal stroma, while preserving the patient's native Descemet's membrane and endothelium.[1] This procedure is a significant advancement in the treatment of corneal stromal pathologies, such as keratoconus, corneal scars, and stromal dystrophies, in patients with healthy endothelial function.[2][3] The primary advantage of DALK over traditional full-thickness penetrating keratoplasty (PK) is the elimination of endothelial graft rejection, a major cause of graft failure.[2] This guide provides a comprehensive overview of the long-term outcomes of DALK, detailing quantitative data, experimental protocols, and key procedural workflows to inform research and development in this field.

Quantitative Outcomes of DALK

The long-term success of DALK is evaluated through several key metrics, including graft survival, endothelial cell preservation, visual acuity, and the incidence of postoperative complications. The following tables summarize quantitative data from various long-term studies.

Table 1: Graft Survival Rates

Follow-up Period	Graft Survival Rate (%)	Study/Citation
1 Year	99.9-100%	[4]
3 Years	92.9%	[4]
5 Years	90.4%	[4]
10 Years	96.7% - 99.3%	[5] [6]
20 Years	95.6%	[5]

Table 2: Endothelial Cell Density (ECD) and Loss

Follow-up Period	Mean ECD (cells/mm ²)	Cumulative ECD Loss (%)	Study/Citation
Preoperative	2494 ± 382	N/A	[5]
6 Months	-	11% (range, 10-13%)	[6]
1 Year	-	8.1% - 14.9%	[7] [8]
2 Years	-	10.5% - 18.12%	[7] [8]
4 Years	-	21.62%	[8]
6 Years	-	15.1%	[7]
8 Years	-	22.5%	[7]
10 Years	1521 ± 659	-	[5]

Note: Endothelial cell loss in DALK is primarily attributed to surgical trauma and postoperative inflammation, as the host endothelium is preserved.[\[9\]](#) The rate of loss is significantly lower than that observed after PK.[\[8\]](#)

Table 3: Visual and Refractive Outcomes

Outcome Measure	Preoperative	Postoperative (Long-Term)	Study/Citation
Best Corrected Visual Acuity (BCVA)	20/378	20/32 (at 30 months)	[5]
Mean Refractive Spherical Equivalent (D)	-11.1 ± 5.6	-2.6 ± 3.5	[10]
Mean Keratometry (D)	60.7 ± 6.1	44.4 ± 2.2	[10]
Topographic Astigmatism (D)	4.7 ± 2.6	2.9 ± 1.3	[10]

Visual acuity after DALK is comparable to PK in the long term, although visual recovery may be slower with manual dissection techniques compared to the big-bubble technique or PK.[\[5\]](#)

Table 4: Long-Term Complication Rates

Complication	Incidence Rate (%)	Notes	Study/Citation
Graft Rejection (Epithelial/Stromal)	3% - 14.3%	Endothelial rejection is eliminated. Rejection episodes are typically reversible with topical corticosteroids.	[2][11]
Secondary Glaucoma	3.37% - 26.7%	Incidence is significantly lower than after PK.	[11][12]
Cataract	1.47% - 3.7%	-	[11][12]
Suture-Related Complications	1.05%	Includes loosening, vascularization, and sterile infiltrates.	[12]
Interface Haze	Variable	Can affect visual acuity but often improves over time.	[13]
Double Anterior Chamber	9.6% (early postoperative)	Often resolves spontaneously or with intervention.	[13]
Descemet's Membrane Perforation (Intraoperative)	2% - 12%	May necessitate conversion to PK.	[14]

Experimental Protocols

Patient Selection Criteria

Successful long-term outcomes in DALK are highly dependent on appropriate patient selection.

- Indications:
 - Corneal stromal pathologies with a healthy, functioning endothelium.[3]
 - Keratoconus (most common indication).[2]

- Corneal scars (not full-thickness).[1]
- Hereditary stromal dystrophies (e.g., granular, lattice).[2]
- Pellucid marginal degeneration and post-LASIK ectasia.[2]
- Contraindications:
 - Pathologies affecting the endothelium (e.g., Fuchs' endothelial dystrophy, pseudophakic bullous keratopathy).[2]
 - Full-thickness corneal perforation or lesions involving Descemet's membrane.[15]
 - Deep posterior corneal scarring or prior hydrops with discontinuity in Descemet's membrane may favor PK.[15]
- Preoperative Assessment:
 - Comprehensive eye examination, including corneal measurements and imaging (e.g., Scheimpflug tomography).[5]
 - Assessment of co-morbidities such as active inflammation or infection, which should be treated prior to surgery.[5]
 - Evaluation of the crystalline lens status to determine the need for combined or sequential cataract surgery.[5]

Surgical Protocol: Big-Bubble Technique

The big-bubble technique, introduced by Anwar, is the most common method for achieving a Descemetic DALK.[16]

- Anesthesia: Monitored anesthesia care is typically sufficient.[5]
- Host Cornea Preparation:
 - The center of the host cornea is marked.
 - A partial-thickness trephination (approximately 90% depth) is performed.[1]

- Big-Bubble Formation:
 - A 27-gauge needle or a specialized cannula is inserted into the deep stroma.[\[1\]](#)
 - Air is injected forcefully to create a large bubble, separating Descemet's membrane from the posterior stroma.[\[1\]](#)[\[10\]](#) A 10-mL airtight syringe is recommended to ensure sufficient air volume in a single attempt.[\[10\]](#)
- Stromal Removal:
 - The anterior stroma (approximately 70%) is removed using a crescent blade.[\[1\]](#)
 - A paracentesis is created to release aqueous humor.[\[1\]](#)
 - The remaining posterior stroma is incised, and viscoelastic may be injected into the space to facilitate separation.[\[1\]](#)
 - The residual stroma is then excised with curved corneal scissors.[\[1\]](#)
- Donor Tissue Preparation:
 - The donor cornea's endothelium and Descemet's membrane are removed, typically by manual stripping.[\[1\]](#)
 - The donor button is then trephinated to the appropriate size.[\[1\]](#)
- Graft Suturing:
 - The donor graft is secured to the host corneal bed using interrupted and/or running 10-0 nylon sutures.[\[1\]](#)
 - Suture depth is typically around 50% in the donor tissue and 90% in the recipient tissue.[\[5\]](#)
 - Suture knots are rotated and buried.[\[1\]](#)

Surgical Protocol: Manual Dissection Technique

Manual dissection is an alternative when the big-bubble technique is not feasible, such as in cases with deep stromal scarring.[\[5\]](#)

- Anesthesia and Trephination: Similar to the big-bubble technique.
- Stromal Dissection:
 - The anterior corneal stroma is removed layer-by-layer using a crescent blade or other specialized dissectors.[\[2\]](#)
 - To aid visualization of the dissection depth, air may be injected into the anterior chamber to create an "air-endothelium interface" (Melles technique).[\[5\]](#)[\[17\]](#)
- Stromal Removal: The dissection is continued until the desired depth, ideally close to Descemet's membrane, is reached.
- Donor Preparation and Suturing: Similar to the big-bubble technique.

Postoperative Care Protocol

A structured postoperative regimen is crucial for long-term graft survival and optimal outcomes.

- Medications:
 - Topical Corticosteroids (e.g., Prednisolone Acetate 1%): Started at a high frequency (e.g., 6 times daily) and tapered over several months to a year to prevent rejection.[\[4\]](#)[\[18\]](#)[\[19\]](#)
 - Topical Antibiotics (e.g., Ofloxacin 0.3%): Typically prescribed 4 times daily until the bottle is empty to prevent infection.[\[18\]](#)[\[19\]](#)
 - Lubricating Ointment: Applied at bedtime to support epithelial healing.[\[19\]](#)
- Activity Restrictions:
 - Wear an eye shield at night for at least one week.[\[18\]](#)
 - Avoid rubbing the eye.[\[18\]](#)
 - Refrain from strenuous activities, heavy lifting (>30 lbs), and bending below the waist for at least two weeks.[\[18\]](#)
 - Avoid swimming and using hot tubs for at least four weeks.[\[19\]](#)

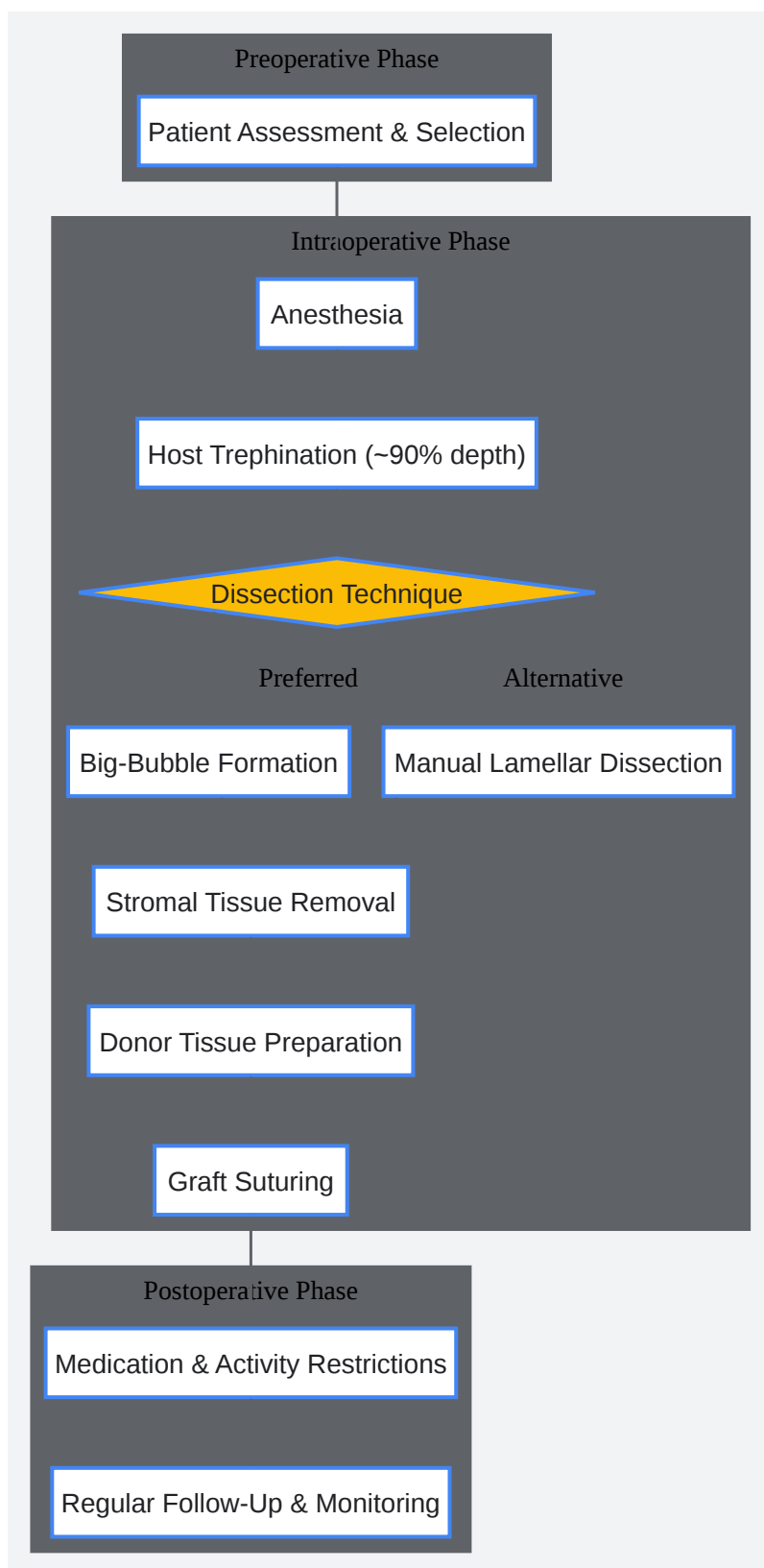
- Follow-up Schedule:
 - Regular follow-up visits are essential to monitor for complications such as graft rejection, infection, and increased intraocular pressure.[20]
 - Suture removal is typically performed 12-15 months postoperatively.[5]

Outcome Assessment Protocols

- Visual Acuity: Best-corrected visual acuity (BCVA) is typically measured using Snellen or ETDRS charts.[21]
- Endothelial Cell Density: Assessed using non-contact specular microscopy.[6] Computer-assisted morphometry analyzes cell size, shape, and density.[22]
- Graft Rejection Assessment: Slit-lamp examination is used to identify clinical signs of rejection, which can include sectoral stromal edema, haze, keratic precipitates (in cases of inflammation extending to the anterior chamber), and vascularization.[11][23]

Visualizations

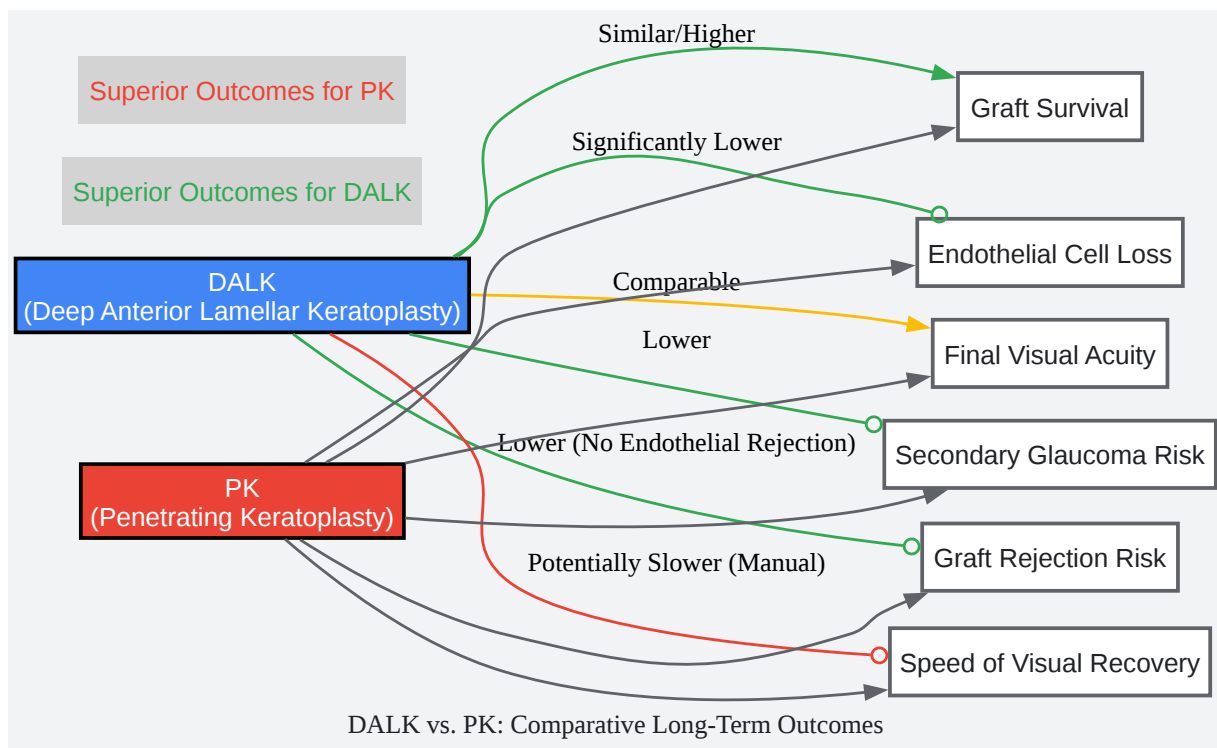
DALK Surgical Workflow



[Click to download full resolution via product page](#)

Caption: A flowchart illustrating the key phases and steps of the Deep Anterior Lamellar Keratoplasty (DALK) procedure.

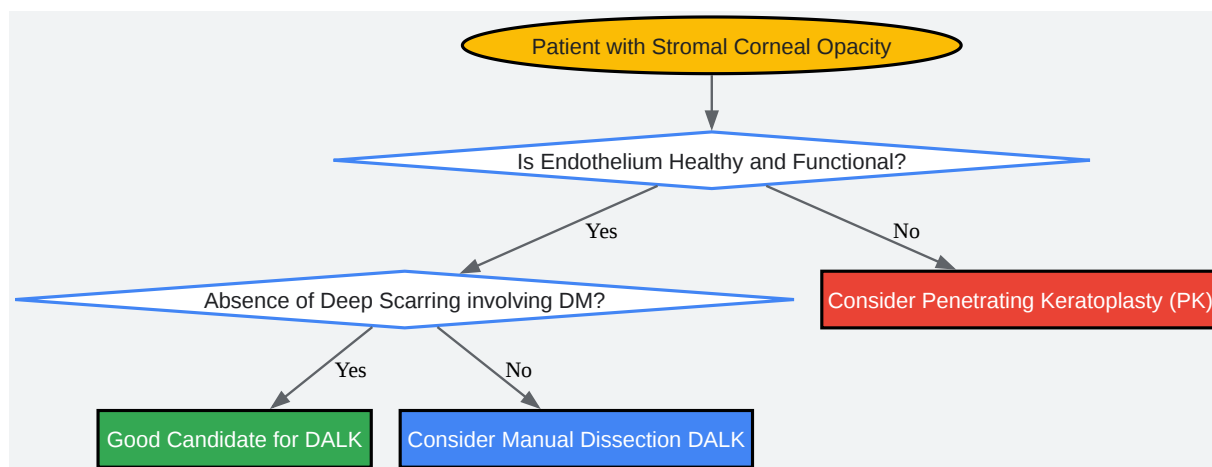
Logical Relationship: DALK vs. PK Long-Term Outcomes



[Click to download full resolution via product page](#)

Caption: A diagram comparing the long-term outcomes of DALK and Penetrating Keratoplasty (PK) across key metrics.

Decision-Making Workflow: Patient Candidacy for DALK



[Click to download full resolution via product page](#)

Caption: A flowchart outlining the key decision points for determining a patient's candidacy for DALK versus PK.

Conclusion

Deep Anterior Lamellar Keratoplasty has demonstrated excellent long-term graft survival and superior preservation of the corneal endothelium compared to Penetrating Keratoplasty.[5][24] While final visual outcomes are often comparable, the significantly reduced risk of endothelial rejection and secondary glaucoma makes DALK a preferable option for patients with stromal disease and healthy endothelium.[5] The choice of surgical technique, particularly the successful application of the big-bubble method, can influence the speed of visual recovery.[5] Continued research into refining surgical techniques, managing intraoperative complications, and optimizing postoperative care will further enhance the long-term success of this procedure. This technical guide provides a foundational understanding of the current state of DALK outcomes and methodologies for professionals engaged in ophthalmic research and development.

Need Custom Synthesis?

BenchChem offers custom synthesis for rare earth carbides and specific isotopic labeling.

Email: info@benchchem.com or [Request Quote Online](#).

References

- 1. Deep Anterior Lamellar Keratoplasty (DALK) [webeye.ophth.uiowa.edu]
- 2. Deep Anterior Lamellar Keratoplasty: Indications, Surgical Techniques and Complications - PMC [pmc.ncbi.nlm.nih.gov]
- 3. Deep Anterior Lamellar Keratoplasty - American Academy of Ophthalmology [aao.org]
- 4. Literature review and suggested protocol for prevention and treatment of corneal graft rejection - PMC [pmc.ncbi.nlm.nih.gov]
- 5. Deep anterior lamellar keratoplasty: A surgeon's guide - PMC [pmc.ncbi.nlm.nih.gov]
- 6. Review of Corneal Endothelial Specular Microscopy for FDA Clinical Trials of Refractive Procedures, Surgical Devices and New Intraocular Drugs and Solutions - PMC [pmc.ncbi.nlm.nih.gov]
- 7. Deep anterior lamellar keratoplasty versus penetrating keratoplasty: comparison of clinical outcomes in contralateral eyes - PMC [pmc.ncbi.nlm.nih.gov]
- 8. mdpi.com [mdpi.com]
- 9. advancedeyesurgery.com [advancedeyesurgery.com]
- 10. crstodayeurope.com [crstodayeurope.com]
- 11. Graft rejection in component keratoplasty - PMC [pmc.ncbi.nlm.nih.gov]
- 12. Efficacy and Safety of Deep Anterior Lamellar Keratoplasty vs. Penetrating Keratoplasty for Keratoconus: A Meta-Analysis | PLOS One [journals.plos.org]
- 13. tjceo.com [tjceo.com]
- 14. Complications After DALK | Ento Key [entokey.com]
- 15. Indications for penetrating keratoplasty and anterior lamellar keratoplasty during 2010-2017 - PMC [pmc.ncbi.nlm.nih.gov]
- 16. Big-bubble DALK: A technique in evolution - PubMed [pubmed.ncbi.nlm.nih.gov]
- 17. crstodayeurope.com [crstodayeurope.com]

- 18. Post-op instructions for PKP & DALK Surgery with Dr. Jimmy Hu [jimmyhumd.com]
- 19. nwcorneainstitute.com [nwcorneainstitute.com]
- 20. Cornea Transplantation (Keratoplasty): Surgery Procedure, Types & Risk [dragarwal.com]
- 21. Visual Acuity Examination Methodology in Keratoconus - PMC [pmc.ncbi.nlm.nih.gov]
- 22. reviewofoptometry.com [reviewofoptometry.com]
- 23. Graft rejection-like reactions in the early postoperative period after deep anterior lamellar keratoplasty for keratoconus: a retrospective study - PMC [pmc.ncbi.nlm.nih.gov]
- 24. emedicine.medscape.com [emedicine.medscape.com]
- To cite this document: BenchChem. [Long-Term Outcomes of Deep Anterior Lamellar Keratoplasty (DALK): A Technical Guide]. BenchChem, [2025]. [Online PDF]. Available at: [https://www.benchchem.com/product/b15575147#long-term-outcomes-of-dalk]

Disclaimer & Data Validity:

The information provided in this document is for Research Use Only (RUO) and is strictly not intended for diagnostic or therapeutic procedures. While BenchChem strives to provide accurate protocols, we make no warranties, express or implied, regarding the fitness of this product for every specific experimental setup.

Technical Support: The protocols provided are for reference purposes. Unsure if this reagent suits your experiment? [[Contact our Ph.D. Support Team for a compatibility check](#)]

Need Industrial/Bulk Grade? [Request Custom Synthesis Quote](#)

BenchChem

Our mission is to be the trusted global source of essential and advanced chemicals, empowering scientists and researchers to drive progress in science and industry.

Contact

Address: 3281 E Guasti Rd

Ontario, CA 91761, United States

Phone: (601) 213-4426

Email: info@benchchem.com