

Long-Term Effects of Timoptic (Timolol) on Ocular Tissues: A Technical Guide

Author: BenchChem Technical Support Team. **Date:** December 2025

Compound of Interest

Compound Name: *Timoptic*

Cat. No.: *B12439992*

[Get Quote](#)

For Researchers, Scientists, and Drug Development Professionals

This technical guide provides a comprehensive overview of the long-term effects of **Timoptic** (timolol), a non-selective beta-adrenergic antagonist, on various ocular tissues. Timolol has been a cornerstone in the management of glaucoma for decades, primarily by reducing aqueous humor production to lower intraocular pressure (IOP).^{[1][2][3]} However, its chronic use can induce a range of effects on the delicate structures of the eye. This document synthesizes findings from numerous studies to present quantitative data, detailed experimental protocols, and visual representations of the underlying mechanisms and experimental approaches.

Ocular Surface: Conjunctiva and Cornea

Long-term administration of timolol preparations, particularly those containing preservatives like benzalkonium chloride (BAK), has been shown to adversely affect the ocular surface.^{[4][5]}

Conjunctival Tissues

Chronic use of timolol can lead to significant alterations in the conjunctiva, including subclinical inflammation and changes to the extracellular matrix.^{[5][6][7]} These changes are critical considerations, especially in patients who may require future glaucoma filtration surgery, as they can contribute to surgical failure.^{[6][7]}

Quantitative Data on Conjunctival Changes:

Parameter	Control Group	Long-Term Timolol Group	Significance	Study Population
Goblet Cell Density	Normal	Significantly Decreased	$P < 0.001$	21 patients chronically treated with 0.5% timolol maleate vs. 40 controls[4]
Mucus Granules	Normal	Significantly Decreased	$P < 0.001$	21 patients chronically treated with 0.5% timolol maleate vs. 40 controls[4]
Reticular Sheets	Normal	Significantly Decreased	$P < 0.001$	21 patients chronically treated with 0.5% timolol maleate vs. 40 controls[4]
Pathologic Crystallization	Absent	Increased	$P < 0.001$	21 patients chronically treated with 0.5% timolol maleate vs. 40 controls[4]
Amorphous Material	30.9 (12.8)	43.3 (13.2)	$P < 0.001$	20 patients with primary open-angle glaucoma on timolol monotherapy vs. 10 non-glaucomatous patients[6][8]
Optically Clear Spaces	28.8 (20.2)	Significantly Reduced	$P < 0.001$	20 patients with primary open-angle glaucoma on timolol

monotherapy vs.
10 non-
glaucomatous
patients[6][8]

Inflammatory
Cells
(Epithelium)

Lower

Significantly
Higher

P = 0.042

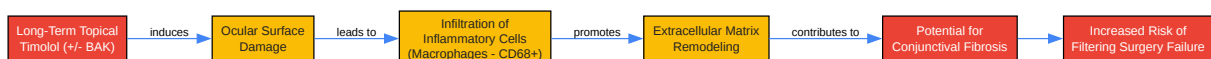New Zealand
white rabbits
treated for 30
days[5]

Experimental Protocol: Conjunctival Biopsy and Analysis

A study investigating the histopathological effects of timolol on the human conjunctiva employed the following methodology:

- Patient Cohort: Conjunctival biopsies were obtained from patients with primary open-angle glaucoma who had been on timolol monotherapy and a control group of non-glaucomatous patients undergoing routine cataract surgery.[8]
- Biopsy Procedure: Specimens were taken from the inferior fornix.[8]
- Analysis:
 - Light Microscopy: To assess general tissue morphology.
 - Immunohistochemistry: Utilized antibodies against MMP-1, MMP-3, TIMP-2, TIMP-3, and CD68 to evaluate extracellular matrix remodeling and inflammatory infiltration.[6][8]
 - Quantitative Transmission Electron Microscopy: To analyze the ultrastructure, including the number of collagen fibers, amorphous material, and optically clear spaces.[6][8]

Signaling and Inflammatory Pathway in the Conjunctiva with Chronic Timolol Use



[Click to download full resolution via product page](#)

Caption: Inflammatory cascade in the conjunctiva due to chronic timolol.

Corneal Tissues

The cornea, particularly the endothelium, is susceptible to the long-term effects of timolol. While some studies suggest minimal impact on endothelial integrity, others indicate potential for cellular changes.[\[9\]](#)[\[10\]](#)

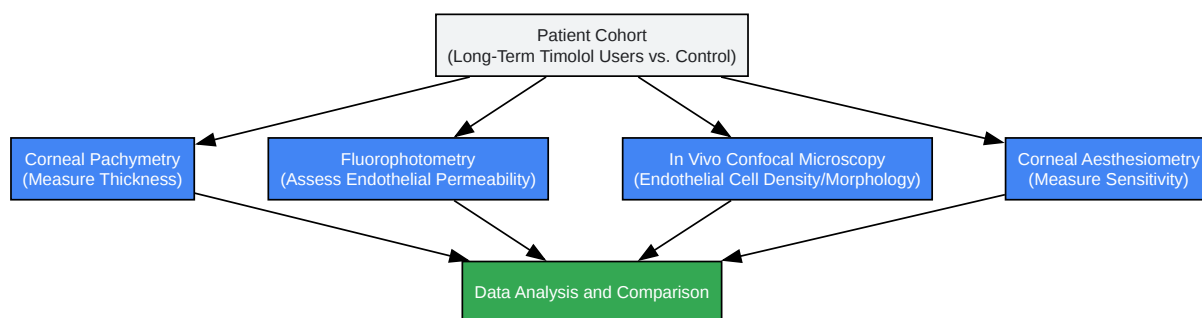
Quantitative Data on Corneal Changes:

Parameter	Control/Untreated	Long-Term Timolol Treated	Significance	Study Details
Coefficient of Endothelial Permeability	No significant difference	No significant difference	Not Statistically Significant	40 eyes treated with timolol (6 months to 14 years) vs. 40 untreated hypertensive eyes [9]
Corneal Thickness	537 μ m	557 μ m	p = 0.0659 (increase)	10 healthy volunteers treated with timolol 0.5% for four days [11]
Endothelial Cell Density	No change	No change	Not Statistically Significant	10 healthy volunteers treated with timolol 0.5% for four days [11]
Corneal Sensitivity	Normal	Decreased	Not specified	Elderly patients on long-term timolol [12]

Experimental Protocol: Corneal Endothelial Permeability Assessment

- Method: Fluorophotometry was used to assess the integrity of the corneal endothelium.[9]
- Procedure: This non-invasive technique measures the rate at which fluorescein dye, applied topically or administered intravenously, enters the anterior chamber from the corneal stroma. An increased rate suggests compromised endothelial barrier function.
- Patient Groups: The study compared a cohort of patients on long-term, uninterrupted timolol maleate therapy with a control group of untreated hypertensive eyes.[9]
- Data Analysis: The coefficient of endothelial permeability was calculated and compared between the groups. No statistically significant differences were found, suggesting that long-term timolol has little effect on this parameter.[9]

Experimental Workflow for Assessing Corneal Effects



[Click to download full resolution via product page](#)

Caption: Workflow for evaluating long-term timolol effects on the cornea.

Aqueous Humor Dynamics and Associated Tissues

Timolol's primary therapeutic action is the reduction of aqueous humor production by the ciliary body.[3] However, this long-term suppression of aqueous flow may have secondary consequences for the trabecular meshwork.

Ciliary Body

Chronic administration of timolol can lead to sustained vasoconstriction of the arterioles supplying the ciliary processes.^[13] This is believed to be a key mechanism in reducing aqueous humor formation. In vitro studies have also shown that timolol binds to melanin in the iris-ciliary body, leading to a slow release of the drug.^[14]

Trabecular Meshwork

The long-term impact of reduced aqueous humor flow on the trabecular meshwork (TM) is a subject of ongoing research. One hypothesis suggests that chronic underperfusion of the TM could lead to a decrease in outflow facility.^{[1][15][16]}

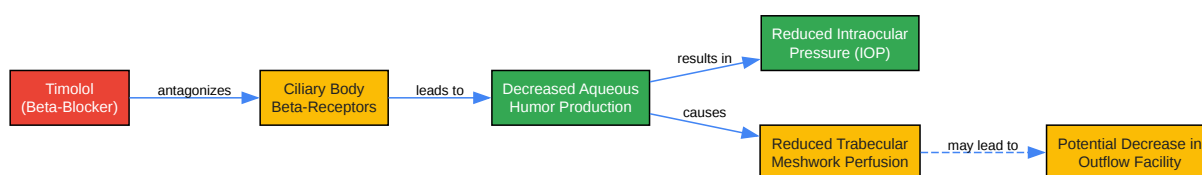
Quantitative Data on Aqueous Humor Dynamics:

Parameter	Baseline	After Long-Term Timolol	Significance	Study Details
Aqueous Humor Flow (Daytime)	Normal	Reduced by 25%	p=0.001	30 ocular hypertensive volunteers after two weeks of timolol 0.5% ^[17]
Aqueous Humor Flow (Nighttime)	Normally low	No significant reduction from baseline	Not Statistically Significant	30 ocular hypertensive volunteers after two weeks of timolol 0.5% ^[17]
Outflow Facility (with Timolol + Dorzolamide + Prostaglandin)	Baseline	Significantly reduced	Not specified	Study on combined therapy effects ^[1]
Trabecular Meshwork (TM) Width, Thickness, and Schlemm's Canal (SC) Area	Baseline	No significant changes	Not Statistically Significant	23 patients on dorzolamide/timolol fixed combination for 3 months ^[16]

Experimental Protocol: Measurement of Aqueous Humor Flow

- Method: Fluorophotometry is the gold standard for measuring aqueous humor flow in humans.[17]
- Procedure: A fluorescent tracer (fluorescein) is administered, and its clearance from the anterior chamber is measured over time using a specialized fluorophotometer. The rate of clearance is directly related to the rate of aqueous humor flow.
- Study Design: A study on ocular hypertensive volunteers measured aqueous flow during both day and night at baseline and after two weeks of timolol treatment to assess the diurnal effects of the drug.[17]

Logical Relationship of Timolol's Effect on Aqueous Dynamics



[Click to download full resolution via product page](#)

Caption: Timolol's mechanism and its potential long-term impact on aqueous outflow.

Retinal and Optic Nerve Head Circulation

The effect of long-term timolol use on blood flow to the retina and optic nerve head is complex and not fully elucidated, with some studies reporting conflicting results.

Quantitative Data on Ocular Circulation:

Parameter	Treatment	Effect	Significance	Study Details
Pulsatile Choroidal Blood Flow (PCBF)	Topical timolol maleate 0.5%	Decreased by 32 +/- 12%	p = 0.0007	5 healthy volunteers (double-masked, randomized, placebo-controlled)[18]
Retinal Arterial Blood Flow Rate (RBF)	Topical timolol maleate 0.5%	No statistically significant change	Not Statistically Significant	5 healthy volunteers[18]
Optic Nerve Head Capillary Blood Speed (CBS)	Topical timolol maleate 0.5%	No statistically significant change	Not Statistically Significant	5 healthy volunteers[18]
Retinal Vein Red Blood Cell Velocity	Timolol-treated eyes	Increased by 12.0%	P < 0.005	Not specified[19]
Retinal Vein Volumetric Blood Flow Rate	Timolol-treated eyes	Increased by 8.4%	P < 0.05	Not specified[19]
Optic Nerve Oxygen Tension (ONPO2)	Systemic administration of timolol	No effect	Not Statistically Significant	Pig model[20]

Experimental Protocol: Laser Doppler Velocimetry for Retinal Blood Flow

- **Method:** Laser Doppler velocimetry is a non-invasive technique used to measure the velocity of red blood cells in retinal vessels.
- **Procedure:** A low-power laser beam is directed into the eye, and the light scattered by the moving red blood cells undergoes a Doppler shift. This shift is analyzed to determine the blood flow velocity. Combined with monochromatic photography to measure vessel diameter, volumetric blood flow can be calculated.

- Application: This method has been used in studies to assess the acute and chronic effects of timolol on retinal and optic nerve head circulation.[18]

In conclusion, while **Timoptic** is an effective and widely used medication for lowering intraocular pressure, its long-term use is associated with a variety of effects on ocular tissues. These range from inflammatory and structural changes on the ocular surface to potential alterations in aqueous humor outflow pathways and ocular circulation. A thorough understanding of these long-term effects is crucial for drug development professionals and researchers working on next-generation glaucoma therapies and for clinicians managing patients on chronic timolol treatment.

Need Custom Synthesis?

BenchChem offers custom synthesis for rare earth carbides and specific isotopic labeling.

Email: info@benchchem.com or [Request Quote Online](#).

References

- 1. Effect of Timolol on Aqueous Humor Outflow Facility in Healthy Human Eyes - PMC [pmc.ncbi.nlm.nih.gov]
- 2. The impact of timolol maleate on the ocular tolerability of fixed-combination glaucoma therapies - PMC [pmc.ncbi.nlm.nih.gov]
- 3. Timolol - StatPearls - NCBI Bookshelf [ncbi.nlm.nih.gov]
- 4. Ocular surface alteration after long-term treatment with an antiglaucomatous drug - PubMed [pubmed.ncbi.nlm.nih.gov]
- 5. researchgate.net [researchgate.net]
- 6. Effect of latanoprost and timolol on the histopathology of the human conjunctiva - PMC [pmc.ncbi.nlm.nih.gov]
- 7. Frontiers | Ocular surface disease: a known yet overlooked side effect of topical glaucoma therapy [frontiersin.org]
- 8. Effect of latanoprost and timolol on the histopathology of the human conjunctiva - PubMed [pubmed.ncbi.nlm.nih.gov]
- 9. Effect of continued treatment with timolol maleate on corneal endothelium: a fluorophotometric study - PubMed [pubmed.ncbi.nlm.nih.gov]

- 10. The Multifarious Effects of Various Glaucoma Pharmacotherapy on Corneal Endothelium: A Narrative Review - PMC [pmc.ncbi.nlm.nih.gov]
- 11. [Effect of timolol on central corneal thickness and endothelial cell density]. | Semantic Scholar [semanticscholar.org]
- 12. A Narrative Review of Ocular Surface Disease Related to Anti-Glaucomatous Medications - PMC [pmc.ncbi.nlm.nih.gov]
- 13. Ciliary vasoconstriction after topical adrenergic drugs - PubMed [pubmed.ncbi.nlm.nih.gov]
- 14. Binding of timolol to iris-ciliary body and melanin: an in vitro model for assessing the kinetics and efficacy of long-acting antiglaucoma drugs [pubmed.ncbi.nlm.nih.gov]
- 15. Studies on the mechanism of action of timolol and on the effects of suppression and redirection of aqueous flow on outflow facility - PubMed [pubmed.ncbi.nlm.nih.gov]
- 16. Morphological changes in the trabecular meshwork and Schlemm's canal after treatment with topical intraocular pressure-lowering agents - PMC [pmc.ncbi.nlm.nih.gov]
- 17. iovs.arvojournals.org [iovs.arvojournals.org]
- 18. Effect of timolol on human retinal, choroidal and optic nerve head circulation - PubMed [pubmed.ncbi.nlm.nih.gov]
- 19. iovs.arvojournals.org [iovs.arvojournals.org]
- 20. Optic nerve oxygen tension: the effects of timolol and dorzolamide - PMC [pmc.ncbi.nlm.nih.gov]
- To cite this document: BenchChem. [Long-Term Effects of Timoptic (Timolol) on Ocular Tissues: A Technical Guide]. BenchChem, [2025]. [Online PDF]. Available at: [https://www.benchchem.com/product/b12439992#long-term-effects-of-timoptic-on-ocular-tissues]

Disclaimer & Data Validity:

The information provided in this document is for Research Use Only (RUO) and is strictly not intended for diagnostic or therapeutic procedures. While BenchChem strives to provide accurate protocols, we make no warranties, express or implied, regarding the fitness of this product for every specific experimental setup.

Technical Support: The protocols provided are for reference purposes. Unsure if this reagent suits your experiment? [[Contact our Ph.D. Support Team for a compatibility check](#)]

Need Industrial/Bulk Grade? [Request Custom Synthesis Quote](#)

BenchChem

Our mission is to be the trusted global source of essential and advanced chemicals, empowering scientists and researchers to drive progress in science and industry.

Contact

Address: 3281 E Guasti Rd

Ontario, CA 91761, United States

Phone: (601) 213-4426

Email: info@benchchem.com