

Improving the signal-to-noise ratio in metomidate PET imaging

Author: BenchChem Technical Support Team. **Date:** December 2025

Compound of Interest

Compound Name: Metomidate

Cat. No.: B1676513

[Get Quote](#)

Technical Support Center: Optimizing Metomidate PET Imaging

This technical support center provides troubleshooting guidance and frequently asked questions (FAQs) to assist researchers, scientists, and drug development professionals in improving the signal-to-noise ratio (SNR) of **metomidate** positron emission tomography (PET) imaging.

Troubleshooting Guide

Issue 1: High Background Noise and Poor Tumor-to-Adrenal Contrast

Question: My **metomidate** PET images show high background signal in the adrenal glands, making it difficult to distinguish the target lesion. How can I improve the contrast?

Answer: High background uptake in normal adrenal tissue is a common challenge in **metomidate** PET imaging. The primary strategy to mitigate this is through dexamethasone suppression.

- **Underlying Principle:** **Metomidate** binds to the enzymes CYP11B1 and CYP11B2, which are involved in cortisol and aldosterone synthesis, respectively. Dexamethasone, a synthetic glucocorticoid, suppresses the pituitary-adrenal axis, reducing ACTH-stimulated cortisol production and consequently the expression of CYP11B1 in normal adrenal tissue. This

suppression of uptake in healthy tissue enhances the relative signal from aldosterone-producing adenomas (APAs), which are less sensitive to ACTH suppression.[1][2]

- Recommended Protocol: Pre-treatment with dexamethasone for three days prior to the scan has been shown to improve the signal-to-background ratio.[2][3][4][5] A common regimen is 0.5 mg of dexamethasone administered every six hours for a total of 12 doses.[2] Studies have reported that this pre-treatment can increase the tumor-to-normal adrenal SUVmax ratio by approximately 26%.[5][6]

Issue 2: Low Overall Signal and Noisy Images

Question: The overall signal in my **metomidate** PET scan is low, resulting in noisy images and poor quantitative accuracy. What are the potential causes and solutions?

Answer: Low signal intensity can be attributed to several factors, ranging from the radiotracer itself to image acquisition and reconstruction parameters.

- Radiotracer Integrity and Timing: ^{11}C -**metomidate** has a short half-life of about 20 minutes, which presents logistical challenges.[7]
 - On-site Cyclotron: Production of ^{11}C -**metomidate** requires a local cyclotron.[7]
 - Timeliness: Delays in patient arrival or the production process can lead to significant radioactive decay, resulting in a lower injected dose and consequently, a weaker signal.[7][8] It is crucial to adhere to a strict schedule.
- Image Acquisition Time: Insufficient scan duration will result in low count statistics and increased noise.[9]
 - Longer Acquisition: Increasing the acquisition time per bed position can improve the SNR by capturing more coincidence events.[9] A typical acquisition time is 25-30 minutes, centered over the adrenal glands.[7][8]
- Image Reconstruction Parameters: The choice of reconstruction algorithm significantly impacts image quality.

- Iterative Reconstruction: Employing iterative reconstruction algorithms like Ordered Subsets Expectation Maximization (OSEM) generally yields a better SNR compared to older methods like Filtered Backprojection (FBP).[9]
- Advanced Modeling: Incorporating Time-of-Flight (TOF) and Point Spread Function (PSF) modeling during reconstruction can further enhance image quality and SNR.[9]
- Post-Reconstruction Filtering: Applying a smoothing filter, such as a Gaussian filter, after reconstruction can reduce image noise.[9][10] However, excessive filtering can blur the image and compromise spatial resolution, so the filter parameters should be optimized for your specific protocol.[9]

Frequently Asked Questions (FAQs)

Q1: What is the expected SUVmax in aldosterone-producing adenomas versus normal adrenal tissue?

A1: The standardized uptake value (SUV) can vary between patients and scanners. However, studies have shown a significant difference in ¹¹C-**metomidate** uptake between aldosterone-producing adenomas and normal adrenal tissue, especially after dexamethasone suppression. In one study of patients with primary hyperaldosteronism who underwent AVS-confirmed lateralization, the average SUVmax over the tumor was 21.7, compared to 13.8 in the contralateral normal adrenal gland.[5]

Q2: How does ¹¹C-**metomidate** PET/CT compare to the "gold standard" of Adrenal Vein Sampling (AVS)?

A2: ¹¹C-**metomidate** PET/CT is a non-invasive imaging modality that is being investigated as an alternative to the invasive and technically demanding AVS procedure for lateralizing primary aldosteronism.[2][6][11] While some studies have shown it to be a sensitive and specific alternative to AVS[5], others have found its concordance with AVS to be suboptimal.[1][12] The choice between these methods may depend on local expertise and specific patient characteristics.

Q3: Can patient medication interfere with **metomidate** PET imaging?

A3: Certain medications, particularly those that interfere with the renin-angiotensin-aldosterone system, are typically discontinued before AVS to ensure accurate interpretation.^[4] While less is definitively published on medication interference with **metomidate** PET, it is a critical consideration. Mineralocorticoid receptor antagonists like spironolactone and eplerenone could potentially alter the underlying physiology and should be reviewed as part of the experimental design. One study noted that a previous study did not systematically discontinue MRAs, which may affect **metomidate** uptake.^[1]

Q4: What are the key steps in a typical ¹¹C-**metomidate** PET/CT experimental workflow?

A4: A typical workflow involves patient preparation, radiotracer administration, and image acquisition and analysis. This process is visualized in the workflow diagram below.

Experimental Protocols

Protocol 1: Dexamethasone Suppression for Improved Signal-to-Background Ratio

- Patient Preparation: For three days prior to the PET scan, administer 0.5 mg of dexamethasone orally every six hours.^[2]
- Final Dose: The last dose should be administered on the morning of the scan.
- Confirmation: Ensure patient compliance with the dexamethasone regimen.

Protocol 2: ¹¹C-**Metomidate** PET/CT Image Acquisition

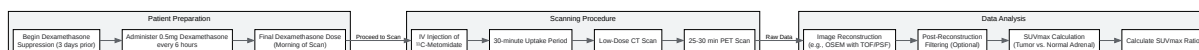- Radiotracer Injection: Administer an intravenous bolus of 150-500 MBq of ¹¹C-**metomidate**.^{[5][13]}
- Uptake Period: Allow for a 30-minute uptake period during which the patient should rest quietly.^{[7][8]}
- Patient Positioning: Position the patient on the scanner bed, typically supine with arms raised above the head if possible.^[8]
- CT Scan: Perform a low-dose CT scan over the adrenal glands for attenuation correction and anatomical localization.^{[7][13]}

- PET Scan: Acquire a static PET emission scan for 25-30 minutes, centered over the adrenal glands.[7][8]

Quantitative Data Summary

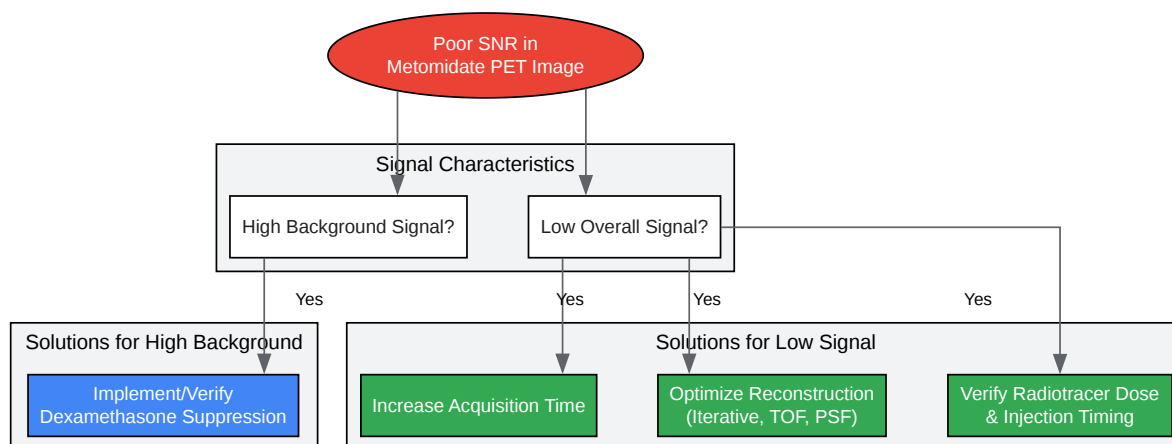
Parameter	Aldosterone-Producing Adenoma (APA)	Normal Adrenal Tissue	Reference
Mean SUVmax (with Dexamethasone)	21.7 ± 1.6	13.8 ± 0.6	[5]
Tumor-to-Normal Adrenal SUVmax Ratio Increase with Dexamethasone	25.6% ± 5.0%	N/A	[5]
Diagnostic Cut-off (SUVmax Ratio)	> 1.25	N/A	[5]

Visualizations



[Click to download full resolution via product page](#)

Caption: Workflow for **Metomidate** PET Imaging.



[Click to download full resolution via product page](#)

Caption: Troubleshooting Logic for Poor SNR.

Need Custom Synthesis?

BenchChem offers custom synthesis for rare earth carbides and specific isotopic labeling.

Email: info@benchchem.com or [Request Quote Online](#).

References

- 1. Functional imaging with ^{11}C -metomidate PET for subtype diagnosis in primary aldosteronism - PMC [pmc.ncbi.nlm.nih.gov]
- 2. Targeted Molecular Imaging in Adrenal Disease—An Emerging Role for Metomidate PET-CT - PMC [pmc.ncbi.nlm.nih.gov]
- 3. njl-admin.nihr.ac.uk [njl-admin.nihr.ac.uk]
- 4. api.repository.cam.ac.uk [api.repository.cam.ac.uk]
- 5. Evaluation of the sensitivity and specificity of (^{11}C) -metomidate positron emission tomography (PET)-CT for lateralizing aldosterone secretion by Conn's adenomas - PubMed

[pubmed.ncbi.nlm.nih.gov]

- 6. academic.oup.com [academic.oup.com]
- 7. sor.org [sor.org]
- 8. PET-CT scan - 11C Metomidate | CUH [cuh.nhs.uk]
- 9. benchchem.com [benchchem.com]
- 10. arxiv.org [arxiv.org]
- 11. pure.johnshopkins.edu [pure.johnshopkins.edu]
- 12. Functional imaging with 11C-metomidate PET for subtype diagnosis in primary aldosteronism - PubMed [pubmed.ncbi.nlm.nih.gov]
- 13. researchgate.net [researchgate.net]
- To cite this document: BenchChem. [Improving the signal-to-noise ratio in metomidate PET imaging]. BenchChem, [2025]. [Online PDF]. Available at: [https://www.benchchem.com/product/b1676513#improving-the-signal-to-noise-ratio-in-metomidate-pet-imaging]

Disclaimer & Data Validity:

The information provided in this document is for Research Use Only (RUO) and is strictly not intended for diagnostic or therapeutic procedures. While BenchChem strives to provide accurate protocols, we make no warranties, express or implied, regarding the fitness of this product for every specific experimental setup.

Technical Support: The protocols provided are for reference purposes. Unsure if this reagent suits your experiment? [[Contact our Ph.D. Support Team for a compatibility check](#)]

Need Industrial/Bulk Grade? [Request Custom Synthesis Quote](#)

BenchChem

Our mission is to be the trusted global source of essential and advanced chemicals, empowering scientists and researchers to drive progress in science and industry.

Contact

Address: 3281 E Guasti Rd

Ontario, CA 91761, United States

Phone: (601) 213-4426

Email: info@benchchem.com