

Image quality degradation in Gadoxetic acid-enhanced MRI

Author: BenchChem Technical Support Team. **Date:** December 2025

Compound of Interest

Compound Name: *Gadoxetic acid*

Cat. No.: *B1262754*

[Get Quote](#)

Technical Support Center: Gadoxetic Acid-Enhanced MRI

This technical support center provides troubleshooting guides and frequently asked questions (FAQs) to address common issues related to image quality degradation in **Gadoxetic acid**-enhanced MRI experiments.

Troubleshooting Guides

Issue 1: Severe Motion Artifacts in the Arterial Phase (Transient Severe Motion - TSM)

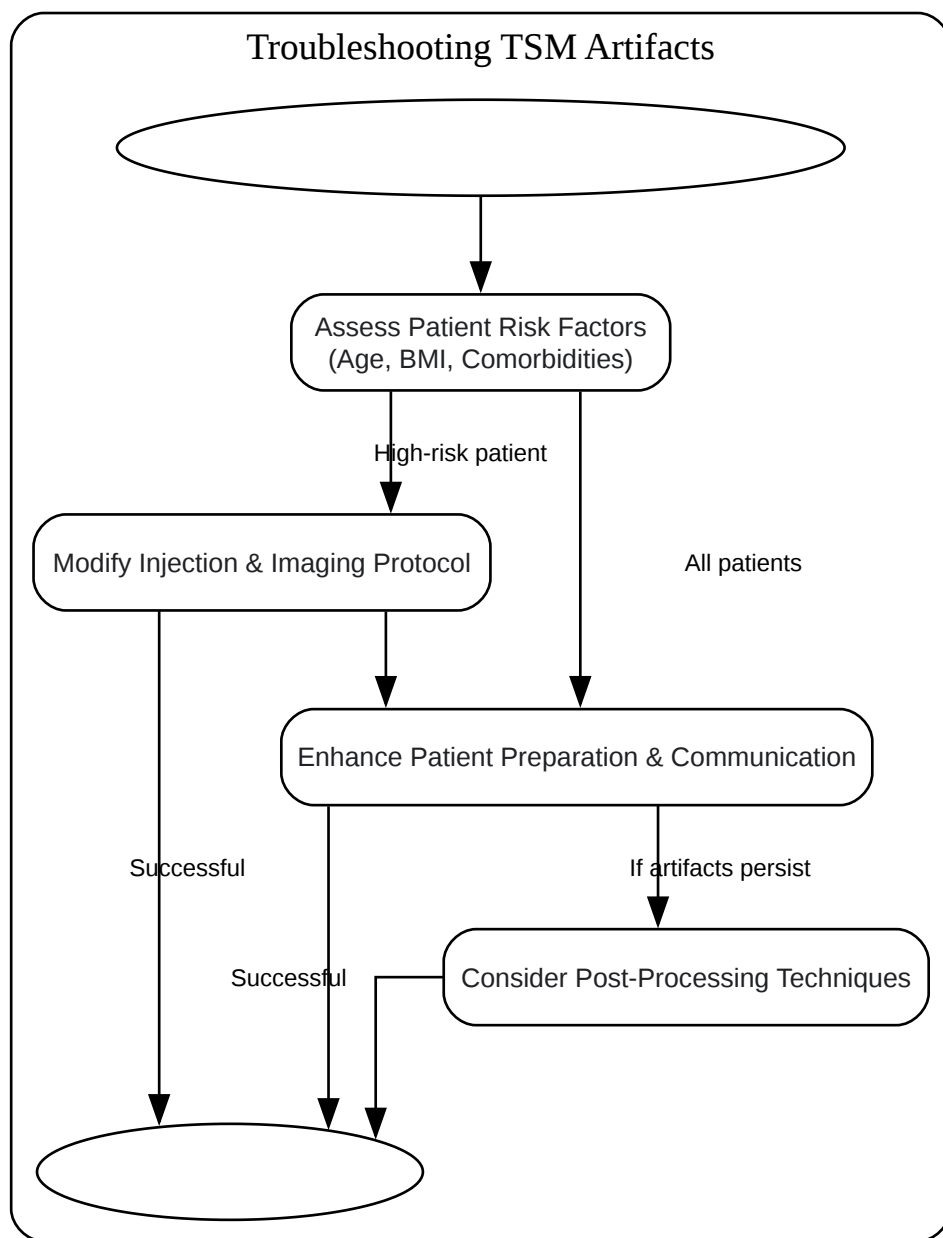
Q1: We are observing significant motion artifacts, particularly in the arterial phase of our **Gadoxetic acid**-enhanced liver MRI scans. What could be the cause, and how can we mitigate this?

A1: The phenomenon you are describing is likely Transient Severe Motion (TSM), a known side effect of **Gadoxetic acid** administration that can lead to significant degradation of image quality, especially during the arterial phase.[1][2] TSM is often caused by involuntary patient movement or difficulty with breath-holding following the contrast injection.[2] The incidence of TSM is reported to be between 5% and 18% in some studies.[1][2]

Several risk factors have been associated with an increased incidence of TSM:

- Older age (≥ 65 years)[2][3][4]
- High Body Mass Index (BMI ≥ 25 kg/m²)[2][4]
- Lower serum albumin[2][3]
- Chronic Obstructive Pulmonary Disease (COPD)[2][4]
- Moderate to severe pleural effusion[2][4]

Troubleshooting Workflow:



[Click to download full resolution via product page](#)

Caption: Workflow for troubleshooting transient severe motion artifacts.

Mitigation Strategies:

- Modify the Injection Protocol:
 - Dilution: Diluting the **Gadoxetic acid** with an equal volume of saline (1:1) and injecting at a slower rate (e.g., 1 ml/s) has been shown to significantly reduce arterial phase artifacts.

[5][6][7]

- Slower Injection Rate: Reducing the injection rate of undiluted **Gadoxetic acid** (e.g., to 1.0 mL/sec) can also help decrease artifacts compared to faster injections.[6][7]
- Warming the Contrast Agent: Warming the **Gadoxetic acid** to body temperature (37°C) before injection has been demonstrated to reduce the severity of arterial phase artifacts.[8]
- Optimize the Imaging Protocol:
 - Multiple Arterial Phases: Acquiring multiple arterial phase images can increase the likelihood of obtaining at least one diagnostic quality image, which can be particularly useful when TSM occurs.[9][10] The use of view-sharing techniques can facilitate this.[10]
 - Motion-Insensitive Sequences: Employing motion-insensitive or motion-corrected MRI sequences, such as radial k-space acquisition (e.g., radial VIBE), can help reduce the impact of patient movement.[11]
 - Navigator-Gated Sequences: For the hepatobiliary phase, navigator-gated 3D T1-weighted sequences can improve image quality compared to standard breath-hold techniques.[12][13]
- Improve Patient Preparation and Communication:
 - Breathing Commands: Training MRI technicians to use modified, patient-adapted breathing commands can significantly reduce respiratory motion artifacts.[14][15]
 - Breath-hold Training: Practicing the breath-hold maneuver with the patient before the contrast injection can improve compliance and reduce the likelihood of motion.[6]
- Post-Processing:
 - Deep Learning-Based Correction: Unsupervised deep learning networks, such as DR-CycleGAN, have shown promise in correcting motion artifacts in arterial phase images.[1]

Issue 2: Suboptimal Image Contrast in the Hepatobiliary Phase (HBP)

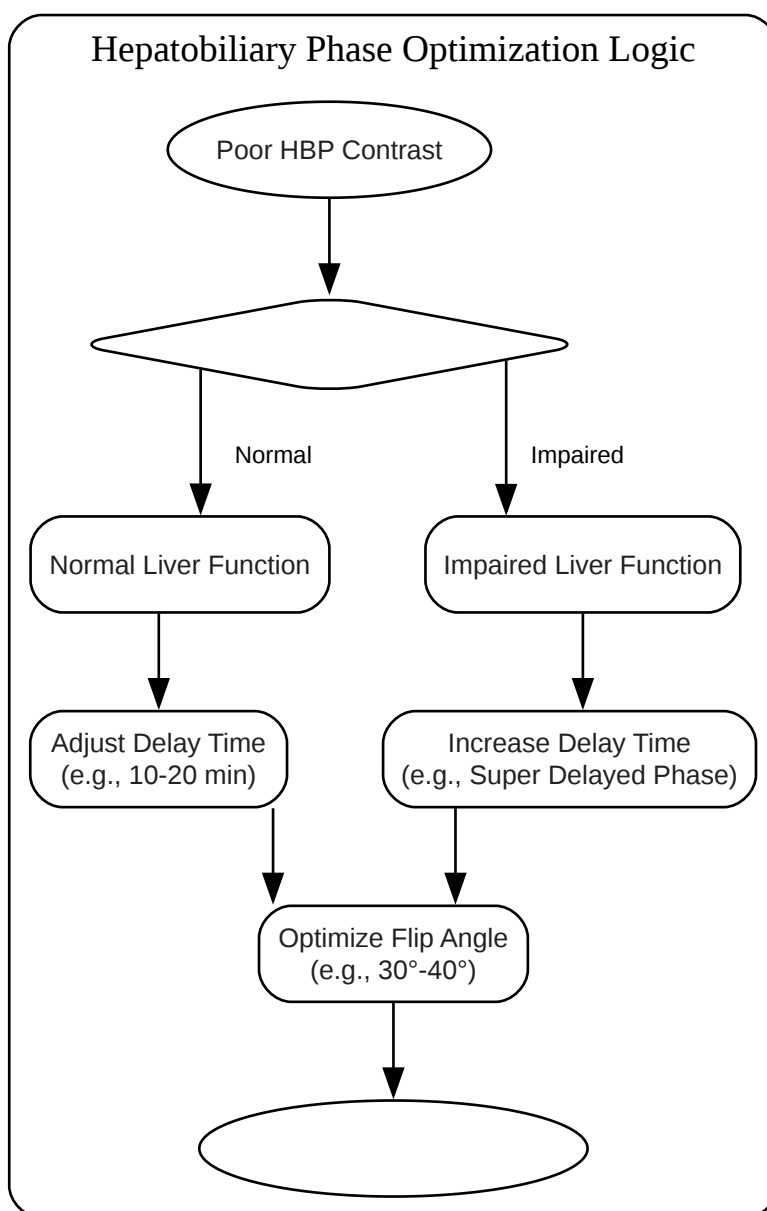
Q2: The contrast between the liver parenchyma and lesions in our hepatobiliary phase images is poor. How can we optimize this?

A2: Suboptimal contrast in the hepatobiliary phase (HBP) can be due to several factors, including incorrect timing of the acquisition and patient-specific factors like impaired liver function.

Optimization Strategies:

- Adjusting the Delay Time:
 - The typical delay for HBP imaging is 20 minutes post-injection.[16][17] However, this may not be optimal for all patients.
 - For patients with normal liver function, a 10-minute delay may be sufficient.[16]
 - In patients with cirrhosis or impaired liver function, a longer delay (e.g., super delayed phase imaging at 60-120 minutes) may be necessary to achieve adequate liver enhancement and improve lesion conspicuity.[18][19]
- Optimizing Flip Angle:
 - Increasing the flip angle (FA) can improve the contrast-to-noise ratio in the HBP. For instance, using a 30° FA at 10 minutes or a 40° FA with navigator-gated sequences has been suggested to be more effective than a standard 10° FA at 20 minutes.[13][16]
- Consider Liver Function:
 - The uptake of **Gadoxetic acid** is dependent on hepatocyte function.[16] In patients with severe liver disease, parenchymal enhancement may be reduced, leading to lower image contrast.[18] In such cases, a "super delayed phase" acquisition can be beneficial.[18][19]

Logical Diagram for HBP Optimization:



[Click to download full resolution via product page](#)

Caption: Decision logic for optimizing hepatobiliary phase image contrast.

Frequently Asked Questions (FAQs)

Q: What is the recommended dose for **Gadoxetic acid**? A: The standard recommended dose is 0.025 mmol/kg of body weight.[\[8\]](#)[\[20\]](#)

Q: Does the injection rate of **Gadoxetic acid** affect tumor enhancement? A: Studies in animal models suggest that while a slower injection rate may improve vascular enhancement, it does not significantly affect arterial tumor enhancement.[\[21\]](#)

Q: Are there alternatives to **Gadoxetic acid** if TSM is a recurrent problem for a patient? A: The Liver Imaging Reporting and Data System (LI-RADS) suggests that extracellular contrast agents may be preferable in certain situations, especially for assessing treatment response, if TSM with **Gadoxetic acid** is a significant issue.[\[2\]](#)

Q: Can deep learning be used to improve image quality? A: Yes, deep learning models, specifically unsupervised networks, are being developed to correct for motion artifacts in **Gadoxetic acid**-enhanced MRI and have shown promising results in improving image quality.[\[1\]](#)

Quantitative Data Summary

Table 1: Impact of Mitigation Strategies on Arterial Phase Artifacts

Strategy	Study Finding	Artifact Score/Incidence (Control)	Artifact Score/Incidence (Intervention)	p-value	Reference
Dilution (1:1 with saline) at 1 ml/s	Significantly reduced AP artifacts.	31% (AP artifacts)	9% (AP artifacts)	<0.05	[5]
Warming (37°C vs. 24°C)	Significantly lower mean artifact score.	1.6 ± 0.9	1.4 ± 0.8	0.017	[8]
Warming (37°C vs. 24°C)	Significantly lower rate of substantial artifacts.	21.1%	11.2%	0.031	[8]
Modified Breathing Command	Significant improvement in image quality scores.	N/A (Traditional command)	N/A (Modified command)	<0.001	[14]
Modified Breathing Command	Decrease in severe/extensive artifacts.	33.3%	6.7%	0.021	[14]
Dilution (2.0 mL/sec) vs. Slow Injection (1.0 mL/sec)	Lower mean artifact score with dilution.	1.95 (Slow Injection)	1.46 (Dilution)	≤.001	[6] [7]
Dilution (2.0 mL/sec) vs. Slow Injection (1.0 mL/sec)	Lower frequency of severe artifact with dilution.	15.1% (Slow Injection)	3.8% (Dilution)	<.001	[6] [7]

Experimental Protocols

Protocol 1: Gadoteric Acid Injection with Dilution for Artifact Reduction

This protocol is adapted from studies demonstrating a reduction in arterial phase artifacts.^[5]
^[22]

- Patient Preparation:
 - Patients should fast for at least four hours prior to the MRI scan.^[13]
 - Explain the breath-hold procedure to the patient and perform practice runs.
- Contrast Agent Preparation:
 - Prepare a 1:1 dilution of **Gadoteric acid** with sterile saline.
 - The final volume will be double the standard **Gadoteric acid** volume.
- Injection:
 - Administer the diluted **Gadoteric acid** intravenously at a rate of 1.0 mL/s.^[5]
 - Follow the contrast injection with a 20 mL saline flush.^[2]
- MRI Acquisition:
 - Scanner: 1.5T or 3.0T MRI system with a phased-array torso coil.^[2]
 - Sequence: Use a 3D T1-weighted spoiled gradient-echo sequence (e.g., 3D-SPGR) for dynamic contrast-enhanced imaging.^[2]
 - Dynamic Phases:
 - Arterial Phase: Acquire about 20-25 seconds post-injection.^[2]
 - Portal Venous Phase: Acquire about 60 seconds post-injection.^[2]

- Transitional Phase: Acquire at 3 minutes post-injection.[2]
- Hepatobiliary Phase: Acquire at 20 minutes post-injection.[2][16]
- Breath-hold: All dynamic phases should be acquired during a single breath-hold of approximately 12-20 seconds.[2][8]

Protocol 2: Optimized Hepatobiliary Phase Imaging

This protocol is designed to enhance liver-to-lesion contrast in the hepatobiliary phase.[12][13][16]

- Patient and Contrast Preparation: Follow the same steps as in Protocol 1 for patient preparation and standard (undiluted) **Gadoxetic acid** administration.
- MRI Acquisition (Hepatobiliary Phase):
 - Timing:
 - Normal Liver Function: Acquire HBP images 10-20 minutes post-injection.[16]
 - Impaired Liver Function: Consider a "super delayed phase" acquisition at 60-120 minutes post-injection in addition to the standard 20-minute HBP.[18][19]
 - Sequence Options:
 - High Flip Angle Breath-Hold: Use a 3D T1-weighted gradient-echo sequence with an increased flip angle (e.g., 30° or 40°) to improve contrast-to-noise ratio.[13][16]
 - Navigator-Gated Sequence: For patients who have difficulty with breath-holding, a navigator-gated 3D T1-weighted sequence can be used to reduce respiratory motion artifacts and may provide superior image quality.[12][13]
 - Image Analysis:
 - Qualitatively assess the clarity of liver parenchymal enhancement and lesion conspicuity.

- Quantitatively, the liver-to-spleen contrast ratio can be calculated to evaluate the degree of hepatic enhancement.[18][19]

Need Custom Synthesis?

BenchChem offers custom synthesis for rare earth carbides and specific isotopic labeling.

Email: info@benchchem.com or [Request Quote Online](#).

References

- 1. Correction of Arterial-Phase Motion Artifacts in Gadoteric Acid-Enhanced Liver MRI Using an Innovative Unsupervised Network [mdpi.com]
- 2. Investigation of transient severe motion artifacts on gadoteric acid-enhanced MRI: frequency and risk factors - PMC [pmc.ncbi.nlm.nih.gov]
- 3. Investigation of transient severe motion artifacts on gadoteric acid-enhanced MRI: frequency and risk factors - PubMed [pubmed.ncbi.nlm.nih.gov]
- 4. Transient severe motion artifacts on gadoteric acid-enhanced MRI: risk factor analysis in 2230 patients - PubMed [pubmed.ncbi.nlm.nih.gov]
- 5. Influence of dilution on arterial-phase artifacts and signal intensity on gadoteric acid-enhanced liver MRI - PubMed [pubmed.ncbi.nlm.nih.gov]
- 6. researchgate.net [researchgate.net]
- 7. Reducing Artifacts during Arterial Phase of Gadoteric Disodium-enhanced MR Imaging: Dilution Method versus Reduced Injection Rate - PubMed [pubmed.ncbi.nlm.nih.gov]
- 8. Effect of warming gadoteric acid on arterial-phase artifacts in dynamic liver MRI: A prospective single-center study - PubMed [pubmed.ncbi.nlm.nih.gov]
- 9. Transient Severe Motion Artifact on Arterial Phase in Gadoteric Acid-Enhanced Liver Magnetic Resonance Imaging: A Systematic Review and Meta-analysis - PubMed [pubmed.ncbi.nlm.nih.gov]
- 10. Artifacts during the arterial phase of gadoteric disodium-enhanced MRI: Multiple arterial phases using view-sharing from two different vendors versus single arterial phase imaging - PubMed [pubmed.ncbi.nlm.nih.gov]
- 11. Gadoteric-Enhanced MRI as a Diagnostic Tool in the Management of Hepatocellular Carcinoma: Report from a 2020 Asia-Pacific Multidisciplinary Expert Meeting - PMC [pmc.ncbi.nlm.nih.gov]

- 12. preprints.org [preprints.org]
- 13. preprints.org [preprints.org]
- 14. Reduction in respiratory motion artefacts on gadoxetate-enhanced MRI after training technicians to apply a simple and more patient-adapted breathing command - PubMed [pubmed.ncbi.nlm.nih.gov]
- 15. researchgate.net [researchgate.net]
- 16. Optimization of hepatobiliary phase imaging in gadoxetic acid-enhanced magnetic resonance imaging: a narrative review - PMC [pmc.ncbi.nlm.nih.gov]
- 17. The MR imaging diagnosis of liver diseases using gadoxetic acid: Emphasis on hepatobiliary phase - PMC [pmc.ncbi.nlm.nih.gov]
- 18. Super delayed phase imaging in gadoxetic acid-enhanced MRI: investigating factors contributing to improved liver contrast - PubMed [pubmed.ncbi.nlm.nih.gov]
- 19. researchgate.net [researchgate.net]
- 20. Troubleshooting Arterial-Phase MR Images of Gadoxetate Disodium-Enhanced Liver - PMC [pmc.ncbi.nlm.nih.gov]
- 21. Experimental studies on artifacts and tumor enhancement on gadoxetic acid-enhanced arterial phase liver MRI in a rabbit VX2 tumor model - PubMed [pubmed.ncbi.nlm.nih.gov]
- 22. Respiratory motion artifacts during arterial phase imaging with gadoxetic acid: Can the injection protocol minimize this drawback? - PubMed [pubmed.ncbi.nlm.nih.gov]
- To cite this document: BenchChem. [Image quality degradation in Gadoxetic acid-enhanced MRI]. BenchChem, [2025]. [Online PDF]. Available at: [https://www.benchchem.com/product/b1262754#image-quality-degradation-in-gadoxetic-acid-enhanced-mri]

Disclaimer & Data Validity:

The information provided in this document is for Research Use Only (RUO) and is strictly not intended for diagnostic or therapeutic procedures. While BenchChem strives to provide accurate protocols, we make no warranties, express or implied, regarding the fitness of this product for every specific experimental setup.

Technical Support: The protocols provided are for reference purposes. Unsure if this reagent suits your experiment? [[Contact our Ph.D. Support Team for a compatibility check](#)]

Need Industrial/Bulk Grade? [Request Custom Synthesis Quote](#)

BenchChem

Our mission is to be the trusted global source of essential and advanced chemicals, empowering scientists and researchers to drive progress in science and industry.

Contact

Address: 3281 E Guasti Rd
Ontario, CA 91761, United States
Phone: (601) 213-4426
Email: info@benchchem.com