

# Identifying and mitigating artifacts in FAPI-4 PET imaging

**Author:** BenchChem Technical Support Team. **Date:** December 2025

## Compound of Interest

Compound Name: FAPI-4

Cat. No.: B607416

[Get Quote](#)

## FAPI-4 PET Imaging Technical Support Center

This technical support center provides troubleshooting guides and frequently asked questions (FAQs) to assist researchers, scientists, and drug development professionals in identifying and mitigating artifacts in Fibroblast Activation Protein Inhibitor (FAPI)-4 Positron Emission Tomography (PET) imaging.

### Troubleshooting Guides

This section addresses specific issues that may arise during **FAPI-4** PET imaging experiments, presented in a question-and-answer format.

Issue: High, non-specific uptake in the abdominal region.

Question: We observe intense **FAPI-4** tracer uptake in the gallbladder of our subject, which is obscuring the view of adjacent tissues. How can we mitigate this?

Answer: High physiological uptake in the gallbladder is a known phenomenon in FAPI-PET imaging. To reduce this artifact, a study has shown that milk consumption after tracer injection can significantly decrease FAPI uptake in the gallbladder.

Recommended Protocol:

- Administer the **FAPI-4** radiotracer to the patient.

- Approximately  $10 \pm 5$  minutes after the tracer injection, have the patient consume 250 mL of milk.
- Proceed with the PET/CT scan at the planned uptake time.

This intervention has been shown to lower the average SUVmean in the gallbladder, potentially improving the diagnostic accuracy for nearby lesions.

Issue: Unexpected focal uptake in non-tumorous bony regions.

Question: Our **FAPI-4** PET scan shows focal uptake in the vertebral bones and joints that does not correlate with suspected metastases. What could be the cause and how should we interpret this?

Answer: Non-specific uptake in degenerative lesions is one of the most common pitfalls in FAPI-PET imaging. FAP is expressed by myofibroblasts involved in tissue remodeling, which is a component of degenerative processes like osteoarthritis.<sup>[1]</sup>

Troubleshooting Steps:

- Correlate with CT/MRI: Carefully examine the corresponding CT or MRI images for signs of degenerative changes, such as osteophytes, joint space narrowing, or subchondral sclerosis.
- Evaluate Patient History: Check the patient's clinical history for known degenerative joint disease or recent trauma.
- Quantitative Analysis: While there can be overlap, benign degenerative lesions often exhibit lower SUVmax values compared to malignant lesions. A study suggested a potential SUVmax cutoff of 5.5 to help differentiate between benign and malignant lesions, though this should be used with caution and in conjunction with other findings.<sup>[2][3]</sup>

Issue: Diffuse or focal uptake in the uterus of a female subject.

Question: We are seeing intense **FAPI-4** uptake in the uterus of a female patient, making it difficult to assess for gynecological malignancies. How can we differentiate this from cancerous tissue?

Answer: High physiological uptake of **FAPI-4** in the uterus is common, particularly in premenopausal women, due to hormonal influences on the endometrium.<sup>[1]</sup> This uptake is often diffuse but can be focal.

Mitigation and Interpretation:

- **Consider Menopausal Status:** FAPI uptake in the uterus is significantly higher in premenopausal women compared to postmenopausal women. In postmenopausal women, uterine uptake is generally low.
- **Clinical Correlation:** Correlate the imaging findings with the patient's menstrual cycle phase, if known, and any history of uterine pathologies like fibroids, which can also show FAPI uptake.
- **Pattern of Uptake:** Physiological uptake is often diffuse and uniform throughout the endometrium. Malignant lesions may present as more focal and intense areas of uptake that disrupt the normal uterine anatomy. However, significant overlap exists, and histopathological correlation is often necessary for definitive diagnosis.

Issue: Linear or patchy uptake in areas of previous surgery or trauma.

Question: A patient who recently underwent surgery shows **FAPI-4** uptake along the surgical scar. Is this indicative of recurrent disease?

Answer: Not necessarily. FAP is highly expressed in activated fibroblasts involved in wound healing and scar formation.<sup>[1]</sup> Therefore, recent surgical sites, trauma sites, and even radiation-treated areas can demonstrate significant **FAPI-4** uptake.

Troubleshooting and Interpretation:

- **Time Since Intervention:** Uptake in scars is typically most intense in the weeks to months following surgery and tends to decrease over time.
- **Location and Pattern:** The uptake should correspond precisely to the known location of the scar or trauma. A linear pattern is common for surgical incisions.

- **Clinical Context:** Review the patient's surgical history and the time elapsed since the procedure. If there is a concern for recurrence, follow-up imaging can be valuable to assess for changes in the intensity and pattern of uptake over time. Benign post-surgical uptake would be expected to decrease or remain stable, while recurrent tumors would likely show increased uptake and growth.

## Frequently Asked Questions (FAQs)

Q1: What patient preparation is required before a **FAPI-4** PET scan to minimize artifacts?

A1: Unlike FDG-PET, fasting is not necessary for FAPI-PET imaging as glucose metabolism does not influence tracer uptake.<sup>[1]</sup> However, to minimize artifacts from bladder activity, patients should be well-hydrated to promote the clearance of the tracer. It is also recommended that patients void immediately before the scan.

Q2: What are the common sites of physiological **FAPI-4** uptake that can be mistaken for pathology?

A2: Besides the uterus and sites of wound healing, physiological or benign **FAPI-4** uptake can be seen in several other areas, including:

- Degenerative joint and bone diseases<sup>[1]</sup>
- Salivary glands
- Thyroid gland
- Nipples
- Inflammatory processes such as pancreatitis and pneumonia<sup>[4]</sup>
- Atherosclerotic plaques<sup>[4]</sup>

Q3: How can motion artifacts be minimized during a **FAPI-4** PET scan?

A3: While specific studies on motion correction in FAPI-PET are limited, general principles for PET/CT apply. Patient comfort is key to minimizing voluntary motion. Immobilization devices can be used if necessary. For respiratory motion, which can affect imaging of the thorax and

upper abdomen, respiratory gating techniques can be employed if available on the scanner. This involves acquiring data in sync with the patient's breathing cycle to reduce blurring and improve lesion detectability.

Q4: Can metallic implants cause artifacts in **FAPI-4** PET/CT imaging?

A4: Yes, metallic implants can cause significant artifacts on the CT portion of the scan, which is used for attenuation correction of the PET data. This can lead to erroneous calculations of tracer concentration in adjacent tissues, appearing as either artificially high or low uptake. If your scanner software includes metal artifact reduction (MAR) algorithms, these should be utilized during the CT reconstruction to improve the accuracy of the PET data.

Q5: What is the optimal uptake time for **FAPI-4** PET imaging?

A5: The optimal uptake time can vary depending on the specific FAPI tracer used (e.g., 68Ga-FAPI-04, 18F-FAPI-74). For 68Ga-labeled FAPI tracers, an uptake time of 20 to 60 minutes is generally recommended. For 18F-labeled compounds, a range of 30 to 90 minutes is often used. Some studies suggest that longer uptake times (e.g., 3 hours) may help differentiate malignant from inflammatory lesions.[5] It is advisable to follow the specific protocol validated for the tracer and imaging system in use.

## Quantitative Data Summary

The following tables summarize the Standardized Uptake Values (SUV) for **FAPI-4** in various non-malignant tissues and conditions, which can serve as a reference for image interpretation.

Table 1: Physiological Uptake of 68Ga-FAPI-04 in Healthy Tissues

Organ/Tissue	Mean SUVmax ( $\pm$ SD)	SUVmax Range
Uterus	7.82 $\pm$ 5.78	1.26 - 24.33
Submandibular Gland	3.53 $\pm$ 1.25	1.46 - 7.83
Nipple	2.13 $\pm$ 0.81	1.12 - 4.88
Gingiva	3.19 $\pm$ 1.41	1.43 - 7.61
Esophagus	2.18 $\pm$ 0.65	1.33 - 3.87

Data sourced from a retrospective study by Qin et al.[4]

Table 2: 68Ga-FAPI-04 Uptake in Benign Lesions

Lesion Type	Mean SUVmax ( $\pm$ SD)	SUVmax Range
Inflammatory Lymph Node	2.75 $\pm$ 1.13	1.37 - 4.91
Pneumonia	3.37 $\pm$ 1.22	1.68 - 6.24
Atherosclerosis	2.85 $\pm$ 0.84	1.49 - 4.65
Pancreatitis	3.41 $\pm$ 3.74	1.27 - 18.11
Osteosclerosis	3.93 $\pm$ 2.22	1.28 - 11.09
Surgical Scar	3.14 $\pm$ 0.98	1.83 - 4.56

Data sourced from a retrospective study by Qin et al.[4]

Table 3: Comparison of 68Ga-FAPI Uptake in Benign vs. Malignant Lesions

Lesion Type	Mean SUVmax
Benign Lesions	4.2
Malignant Lesions	10.6

Data from a study by Kratochwil et al., which suggested a potential SUVmax cutoff of 5.5 for differentiating benign from malignant lesions.[3]

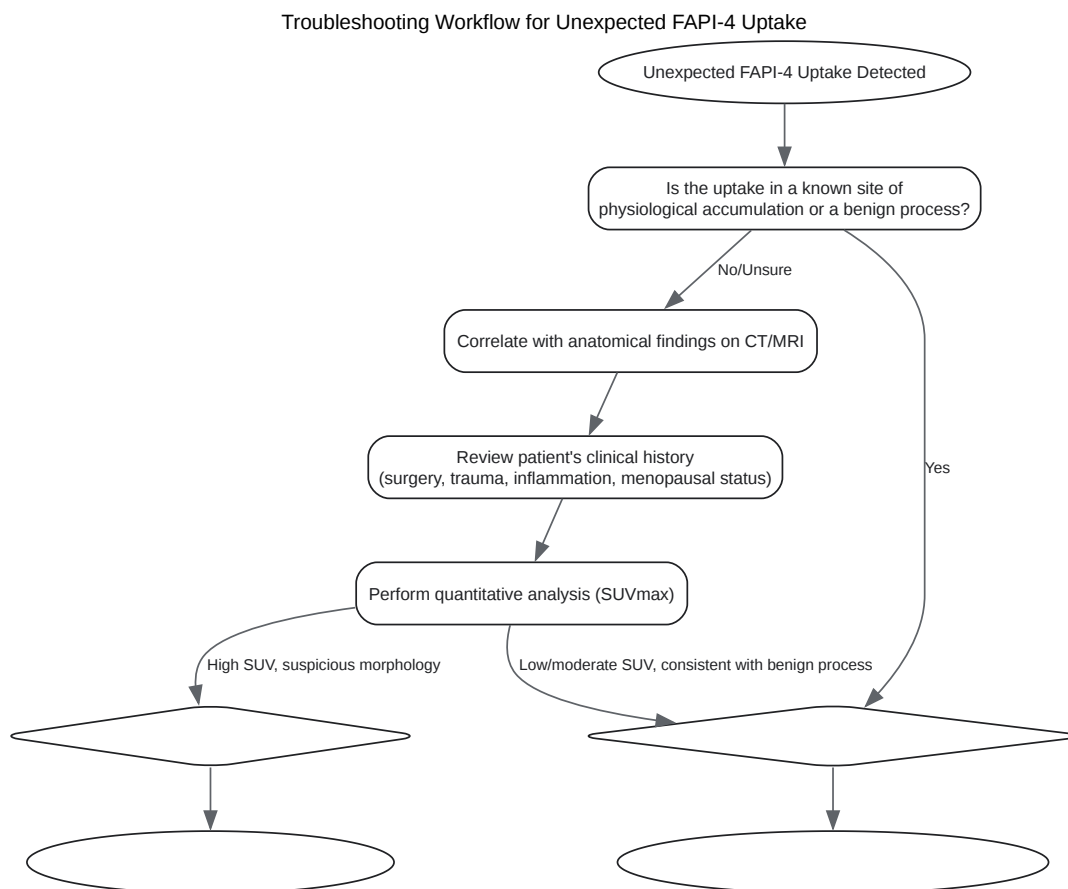
## Experimental Protocols

### Standard Protocol for 68Ga-FAPI-04 PET/CT Imaging

- Patient Preparation:
  - No fasting is required.
  - Ensure the patient is well-hydrated.

- Have the patient void immediately before the scan to minimize bladder artifact.
- Radiotracer Administration:
  - Administer an intravenous injection of 150-250 MBq of <sup>68</sup>Ga-FAPI-04. The exact activity may vary based on local protocols and patient weight.
- Uptake Period:
  - An uptake period of 60 minutes is commonly used. During this time, the patient can rest comfortably.
- Image Acquisition:
  - CT Scan: Perform a low-dose CT scan for attenuation correction and anatomical localization. Typical parameters are 120 kV and 30-100 mAs.
  - PET Scan: Acquire PET data from the vertex to the mid-thigh. The acquisition time is typically 2-3 minutes per bed position.
  - Reconstruction: Reconstruct the PET images using an iterative algorithm (e.g., OSEM) with corrections for attenuation, scatter, and randoms. Time-of-flight (TOF) and point-spread function (PSF) modeling should be used if available to improve image quality.

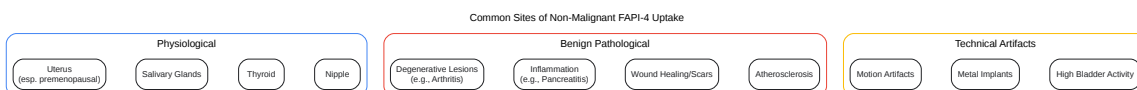
## Visualizations



[Click to download full resolution via product page](#)

Caption: A decision-making workflow for characterizing unexpected **FAPI-4** uptake.

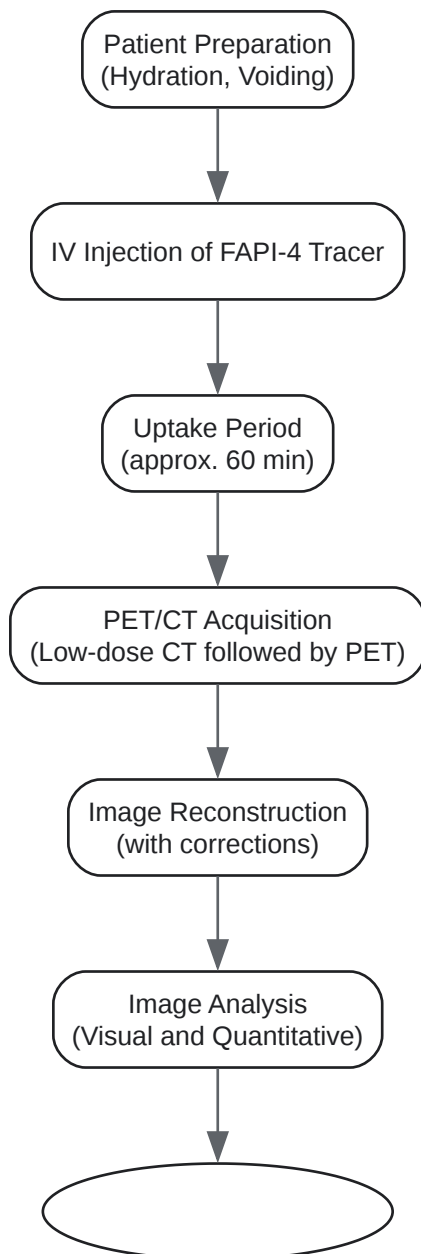




[Click to download full resolution via product page](#)

Caption: Common sources of non-malignant **FAPI-4** uptake categorized by origin.

## Standard FAPI-4 PET/CT Experimental Workflow



[Click to download full resolution via product page](#)

Caption: A typical experimental workflow for a **FAPI-4** PET/CT scan.

**Need Custom Synthesis?**

BenchChem offers custom synthesis for rare earth carbides and specific isotopic labeling.

Email: [info@benchchem.com](mailto:info@benchchem.com) or [Request Quote Online](#).

## References

- 1. Pitfalls and Common Findings in 68Ga-FAPI PET: A Pictorial Analysis - PMC [pmc.ncbi.nlm.nih.gov]
- 2. researchgate.net [researchgate.net]
- 3. Distinguishing Benign and Malignant Findings on [68 Ga]-FAPI PET/CT Based on Quantitative SUV Measurements - PMC [pmc.ncbi.nlm.nih.gov]
- 4. Frontiers | Non-tumoral uptake of 68Ga-FAPI-04 PET: A retrospective study [frontiersin.org]
- 5. semanticscholar.org [semanticscholar.org]
- To cite this document: BenchChem. [Identifying and mitigating artifacts in FAPI-4 PET imaging]. BenchChem, [2025]. [Online PDF]. Available at: [https://www.benchchem.com/product/b607416#identifying-and-mitigating-artifacts-in-fapi-4-pet-imaging]

---

**Disclaimer & Data Validity:**

The information provided in this document is for Research Use Only (RUO) and is strictly not intended for diagnostic or therapeutic procedures. While BenchChem strives to provide accurate protocols, we make no warranties, express or implied, regarding the fitness of this product for every specific experimental setup.

**Technical Support:** The protocols provided are for reference purposes. Unsure if this reagent suits your experiment? [[Contact our Ph.D. Support Team for a compatibility check](#)]

**Need Industrial/Bulk Grade?** [Request Custom Synthesis Quote](#)

# BenchChem

Our mission is to be the trusted global source of essential and advanced chemicals, empowering scientists and researchers to drive progress in science and industry.

## Contact

Address: 3281 E Guasti Rd

Ontario, CA 91761, United States

Phone: (601) 213-4426

Email: [info@benchchem.com](mailto:info@benchchem.com)