

# How to differentiate true pathology from artifact in 2D echo

**Author:** BenchChem Technical Support Team. **Date:** December 2025

## Compound of Interest

Compound Name: M-MoDE-A (2)

Cat. No.: B15144752

[Get Quote](#)

## Technical Support Center: 2D Echocardiography

This technical support center provides troubleshooting guides and frequently asked questions (FAQs) to assist researchers, scientists, and drug development professionals in differentiating true pathology from artifacts in 2D echocardiography.

### Frequently Asked Questions (FAQs)

Q1: What are the fundamental principles for differentiating a true cardiac structure from an artifact?

A1: True anatomical structures are consistent and reproducible across multiple imaging views, whereas artifacts are often view-dependent.[1] Real structures will not cross anatomical boundaries, such as cardiac or vascular walls.[1] Artifacts may have nebulous or indistinct borders, unlike the typically well-defined borders of true structures, even in the case of pathologies like thrombi.[1]

Q2: What are the most common types of artifacts in 2D echocardiography?

A2: Common artifacts in 2D echocardiography can be categorized based on their underlying physical principles:

- Reverberation Artifacts: These appear as multiple, equally spaced echoes behind a strong reflector.[1][2] This category includes "comet-tail" and "ring-down" artifacts.

- **Acoustic Shadowing:** This manifests as a signal void or a dark area behind a highly attenuating structure like calcification or a prosthetic valve.
- **Mirror Image Artifacts:** These are duplications of a structure appearing on the opposite side of a strong, smooth reflector like the pericardium or aorta.
- **Beam Width and Side Lobe Artifacts:** These occur when the ultrasound beam detects objects outside its main axis, causing them to appear within the primary image. This can sometimes be misinterpreted as a dissection flap in the aorta.
- **Near-Field Clutter:** This appears as a hazy or bright area in the near field of the transducer, which can obscure apical structures and be mistaken for a thrombus.

Q3: Can artifacts be useful in clinical diagnosis?

A3: Yes, some artifacts can provide diagnostic clues. For instance, acoustic shadowing can help identify calcified structures or prosthetic materials. Enhancement, the opposite of shadowing, where an area behind a fluid-filled structure appears brighter, can help confirm the cystic nature of a mass. Comet-tail artifacts can be useful in evaluating intimal plaques and detecting certain lesions.

## Troubleshooting Guides

Issue: A suspected mass is observed in the left atrium.

Troubleshooting Steps:

- **Multi-View Interrogation:** Image the left atrium from multiple acoustic windows (e.g., parasternal, apical, subcostal). A true mass should be visible in more than one view, whereas an artifact may only appear in a single plane.
- **Assess Anatomical Boundaries:** Observe if the suspected mass respects the anatomical boundaries of the left atrium. Artifacts like reverberations do not respect these boundaries.
- **Adjust Imaging Settings:**
  - **Gain:** Decrease the overall gain to see if the suspected mass disappears. Artifacts are often gain-dependent.

- **Transducer Frequency:** Switch to a higher frequency transducer for better resolution in the near field, which may help clarify the nature of the structure.
- **Harmonic Imaging:** Utilize harmonic imaging, as it can reduce some artifacts and improve image clarity.
- **Utilize Different Modalities:** Switch to M-mode or use color Doppler. A true intracardiac mass will have a different appearance and flow characteristics compared to an artifact.

Issue: A potential aortic dissection flap is suspected.

#### Troubleshooting Steps:

- **Examine Mobility:** A true dissection flap will exhibit random, independent motion, whereas an artifact, such as a reverberation or side-lobe artifact, will have a more fixed location relative to the aortic wall.
- **Assess Echo Intensity:** A true dissection flap typically has a constant echo intensity. In contrast, the intensity of an artifact may diminish progressively.
- **Employ Color Doppler:** Color Doppler can help differentiate a true flap from an artifact, as the artifact will not typically disrupt blood flow in the same way a true flap would.
- **Change the Imaging Plane:** Altering the transducer position and angulation can help to see if the linear echo persists. Artifacts are often highly dependent on the beam angle.

## Experimental Protocols

Protocol: Standard Operating Procedure for Image Quality Optimization and Artifact Reduction

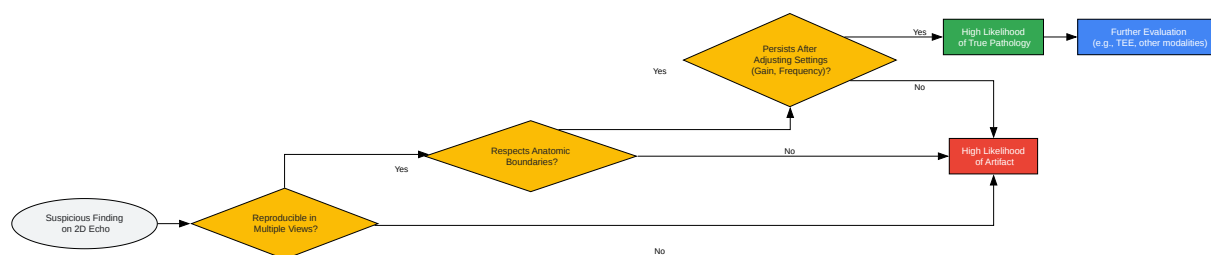
- **Patient Positioning:** Optimize the patient's position (typically left lateral decubitus) to bring the heart closer to the chest wall and improve the acoustic window.
- **Transducer Selection and Placement:**
  - Select the appropriate transducer frequency for the patient's body habitus (higher frequency for better resolution in thinner patients, lower frequency for deeper penetration in obese patients).

- Apply sufficient coupling gel to ensure good skin contact and eliminate air pockets.
- Begin imaging from standard acoustic windows (parasternal, apical, subcostal, and suprasternal).
- Machine Settings Adjustment:
  - Gain: Adjust the time-gain compensation (TGC) to balance the brightness at different depths. Avoid excessive gain, which can create artifactual echoes.
  - Depth: Set the imaging depth to include the entire heart while minimizing empty space beyond the posterior wall.
  - Focus: Position the focal zone at the level of the structure of interest to optimize lateral resolution.
  - Harmonic Imaging: Activate tissue harmonic imaging to reduce near-field clutter and reverberation artifacts.
- Systematic Image Acquisition:
  - Follow a standardized protocol to acquire all recommended views and imaging planes.
  - For any suspected abnormality, meticulously interrogate it in multiple planes and with varied machine settings.
- Equipment Maintenance:
  - Regularly inspect and clean transducers to ensure optimal performance.
  - Ensure the echocardiography machine is calibrated periodically according to the manufacturer's guidelines.

## Quantitative Data Summary

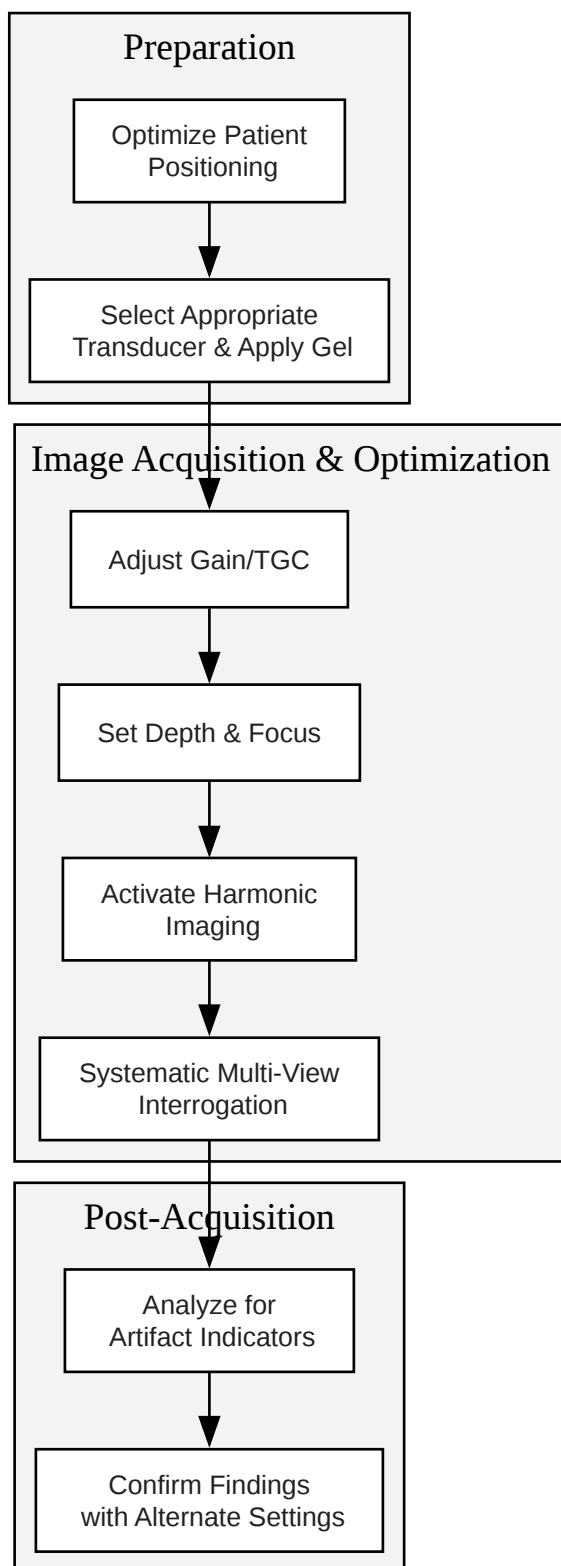
Artifact Type	Common Cause	Key Differentiating Features	Troubleshooting Techniques
Reverberation	Multiple reflections between two strong reflectors.	Appears as multiple, equidistant linear echoes behind the reflector; does not respect anatomical boundaries.	Change transducer angle, decrease near-field gain, use harmonic imaging.
Acoustic Shadowing	Highly attenuating structures (e.g., calcification, prosthetic valves).	Signal void or hypoechoic region posterior to the structure.	Image from a different acoustic window to visualize the obscured region.
Mirror Image	Strong, specular reflector (e.g., pericardium, aorta).	Duplicated image appearing deeper than the true structure, often with opposite motion.	Change imaging plane, decrease gain.
Side Lobe	Ultrasound energy outside the main beam interacting with a strong reflector.	Low-intensity, arc-like echo that may mimic a mass or flap.	Change transducer position, adjust focus.
Near-Field Clutter	High-amplitude oscillations of the piezoelectric crystals.	Hazy, bright echoes in the near field of the image.	Use harmonic imaging, adjust TGC.

## Visual Guides



[Click to download full resolution via product page](#)

Caption: Decision workflow for differentiating artifact from true pathology.



[Click to download full resolution via product page](#)

Caption: Standard protocol for minimizing artifacts during 2D echo acquisition.

**Need Custom Synthesis?**

BenchChem offers custom synthesis for rare earth carbides and specific isotopic labeling.

Email: [info@benchchem.com](mailto:info@benchchem.com) or [Request Quote Online](#).

## References

- 1. Fact or Artifact in Two-Dimensional Echocardiography: Avoiding Misdiagnosis and Missed Diagnosis - PMC [pmc.ncbi.nlm.nih.gov]
- 2. researchgate.net [researchgate.net]
- To cite this document: BenchChem. [How to differentiate true pathology from artifact in 2D echo]. BenchChem, [2025]. [Online PDF]. Available at: [https://www.benchchem.com/product/b15144752#how-to-differentiate-true-pathology-from-artifact-in-2d-echo]

---

**Disclaimer & Data Validity:**

The information provided in this document is for Research Use Only (RUO) and is strictly not intended for diagnostic or therapeutic procedures. While BenchChem strives to provide accurate protocols, we make no warranties, express or implied, regarding the fitness of this product for every specific experimental setup.

**Technical Support:** The protocols provided are for reference purposes. Unsure if this reagent suits your experiment? [[Contact our Ph.D. Support Team for a compatibility check](#)]

**Need Industrial/Bulk Grade?** [Request Custom Synthesis Quote](#)

## BenchChem

Our mission is to be the trusted global source of essential and advanced chemicals, empowering scientists and researchers to drive progress in science and industry.

### Contact

Address: 3281 E Guasti Rd  
Ontario, CA 91761, United States  
Phone: (601) 213-4426  
Email: [info@benchchem.com](mailto:info@benchchem.com)

