

Histopathological comparison of slaframine and pilocarpine on salivary glands

Author: BenchChem Technical Support Team. **Date:** December 2025

Compound of Interest

Compound Name: *Slaframine*

Cat. No.: *B1196289*

[Get Quote](#)

A Histopathological Showdown: Slaframine vs. Pilocarpine on Salivary Glands

For researchers, scientists, and drug development professionals, understanding the nuanced effects of secretagogues on salivary glands is paramount. This guide provides a detailed histopathological comparison of two such agents: **slaframine**, a mycotoxin known for inducing excessive salivation, and pilocarpine, a well-established therapeutic for xerostomia.

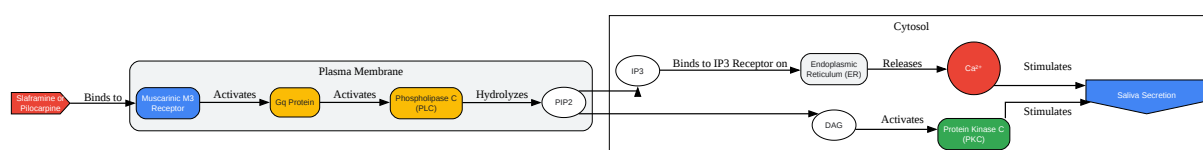
While both **slaframine** and pilocarpine are cholinergic agonists that stimulate salivary secretion, their detailed effects on the microscopic anatomy of salivary glands present a complex picture. This comparison synthesizes available experimental data to illuminate their mechanisms of action, observed histopathological changes, and the experimental protocols used to elicit these findings.

Mechanism of Action: A Tale of Two Muscarinic Agonists

Both **slaframine** and pilocarpine exert their primary effects by acting as agonists at muscarinic acetylcholine receptors (mAChRs), particularly the M3 subtype, which is predominantly expressed in salivary glands.[1][2] Activation of the M3 receptor initiates a signaling cascade that leads to increased intracellular calcium levels, ultimately resulting in the secretion of saliva.

Pilocarpine is a well-characterized parasympathomimetic agent that directly stimulates M3 receptors on salivary acinar cells.[2] **Slaframine**, a mycotoxin produced by the fungus *Rhizoctonia leguminicola*, is bioactivated in the liver to a potent cholinergic agonist that also targets muscarinic receptors, leading to the profound salivation often referred to as "slobbers" in livestock.[3][4]

Signaling Pathway of Muscarinic M3 Receptor Activation



[Click to download full resolution via product page](#)

Caption: Muscarinic M3 Receptor Signaling Pathway for Saliva Secretion.

Histopathological Observations: A Comparative Analysis

Direct comparative histopathological studies between **slaframine** and pilocarpine are scarce in the existing literature. However, by examining studies on individual cholinergic agonists, a comparative picture can be constructed.

Pilocarpine: Histological studies on salivary glands treated with pilocarpine and other cholinergic agonists like carbachol have revealed several key changes. These include:

- **Vacuolization:** Widespread vacuolization in the cytoplasm of both serous and mucous acinar cells has been observed.[5][6] This is often accompanied by the appearance of small vesicles and, in some cases, mitochondrial destruction.[5]

- **Acinar Cell Size:** An increase in the diameter of secretory acini has been reported.
- **Granule Depletion:** Stimulation with pilocarpine can lead to the depletion of secretory granules in serous cells as they release their contents.[5]
- **Cellular Damage:** While often used therapeutically, some studies suggest that prolonged or high-dose stimulation with cholinergic agonists like carbachol can lead to permanent damage to the salivary gland parenchyma.[5]

Slaframine: Detailed histopathological studies on the effects of **slaframine** on salivary glands are limited. The primary focus of most research has been on the clinical sign of excessive salivation in animals.[7] While it is known to be a potent secretagogue acting through muscarinic receptors, specific microscopic changes in salivary gland tissue have not been as thoroughly documented as for pilocarpine. It is plausible that the histopathological effects would be similar to other potent cholinergic agonists, likely involving significant degranulation of acinar cells and potential for cellular stress due to hyperstimulation.

Quantitative Data Summary

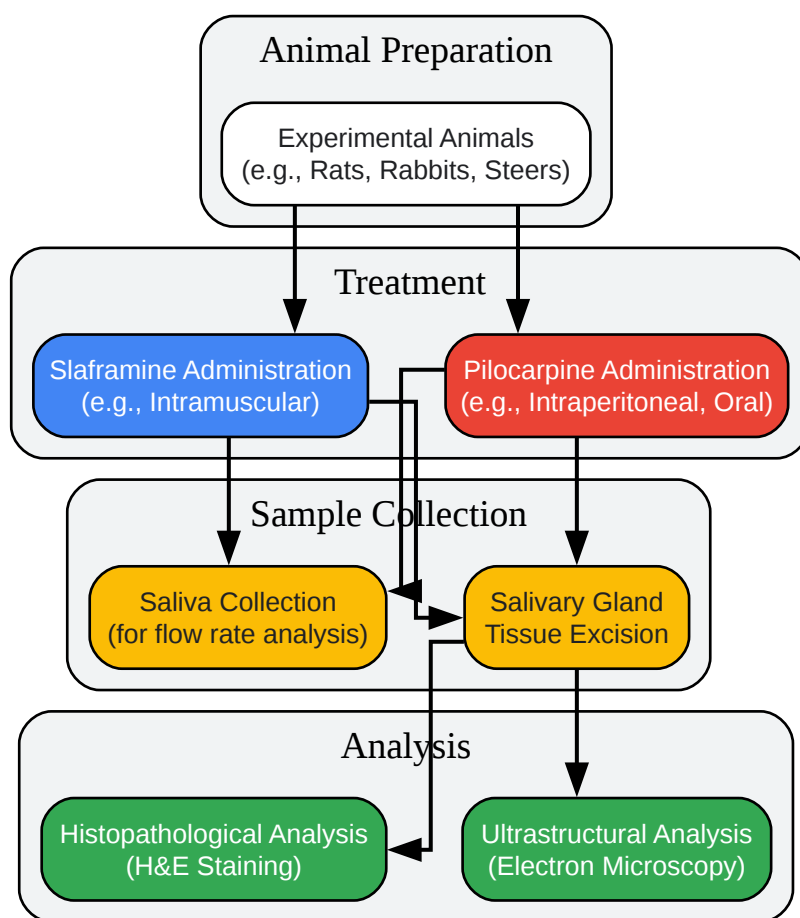
The following table summarizes the quantitative data available from experimental studies on **slaframine** and pilocarpine.

Parameter	Slaframine	Pilocarpine	Reference
Salivary Flow Rate	Increased by 31-70% in steers.	Increased by 2- to 10-fold compared to placebo.	[8][9]
Acinar Diameter	Data not available.	Significantly increased in rabbits.	
Cytoplasmic Vacuolization	Data not available.	Widespread in serous and mucous cells of rats.	[5][6]
Secretory Granule Depletion	Data not available.	Observed in serous cells of rats.	[5]

Experimental Protocols

Detailed methodologies are crucial for the replication and validation of scientific findings. Below are representative experimental protocols for inducing and observing the effects of these secretagogues.

General Experimental Workflow



[Click to download full resolution via product page](#)

Caption: General Experimental Workflow for Salivary Gland Studies.

Slaframine Administration Protocol (Steers)

- Animals: Angus steers with esophageal and ruminal cannulas.

- Drug Administration: Purified **slaframine** administered via single or repeated intramuscular injections at doses ranging from 6 to 24 micrograms/kg body weight.[8]
- Saliva Collection: Saliva collected via esophageal cannula at 15-minute intervals.[8]
- Histopathology: (Details not specified in the reviewed studies).

Pilocarpine Administration and Histology Protocol (Rats/Rabbits)

- Animals: Male Wistar rats or male rabbits.
- Drug Administration: Pilocarpine administered via intraperitoneal injection (in rats) or twice daily intraperitoneal injections at doses of 3mg/kg and 5mg/kg (in rabbits).
- Tissue Collection: At specified time points post-injection, animals are euthanized, and salivary glands (e.g., submandibular, parotid) are excised.
- Tissue Fixation: Glands are fixed in 10% neutral buffered formalin.
- Tissue Processing: Tissues are dehydrated in a graded series of ethanol, cleared in xylene, and embedded in paraffin.
- Sectioning: 5µm thick sections are cut using a microtome.
- Staining: Sections are stained with Hematoxylin and Eosin (H&E) for general morphological examination.
- Microscopy: Stained sections are examined under a light microscope to assess for changes in acinar and ductal morphology, cellular integrity, and inflammatory infiltrate.

Conclusion

Both **slaframine** and pilocarpine are potent cholinergic agonists that stimulate salivary secretion through the M3 muscarinic receptor pathway. Pilocarpine's effects on salivary gland histology are characterized by acinar cell vacuolization and degranulation. While **slaframine** is a powerful secretagogue, a clear gap exists in the literature regarding its specific histopathological impact on salivary gland tissue. Further research is warranted to fully

elucidate the microscopic changes induced by **slaframine** and to enable a more direct and comprehensive comparison with pilocarpine. Such studies would be invaluable for understanding the full spectrum of effects of these compounds and for the development of novel therapies for salivary gland dysfunction.

Need Custom Synthesis?

BenchChem offers custom synthesis for rare earth carbides and specific isotopic labeling.

Email: info@benchchem.com or [Request Quote Online](#).

References

- 1. researchgate.net [researchgate.net]
- 2. benchchem.com [benchchem.com]
- 3. researchgate.net [researchgate.net]
- 4. uknowledge.uky.edu [uknowledge.uky.edu]
- 5. Ultrastructural changes in salivary glands after different adrenergic and cholinergic stimulations. A long-term morphological study in the rat - PubMed [pubmed.ncbi.nlm.nih.gov]
- 6. Salivary gland morphology after alpha-adrenergic and cholinergic stimulation. An ultrastructural study - PubMed [pubmed.ncbi.nlm.nih.gov]
- 7. Slaframine Toxicosis in Animals - Toxicology - MSD Veterinary Manual [msdvetmanual.com]
- 8. Histological and ultrastructural study of the effects of cholinergic and adrenergic agonists on salivary secretion from the lingual epithelium and the lingual gland of the Tokyo Daruma pond frog - PubMed [pubmed.ncbi.nlm.nih.gov]
- 9. Effects of slaframine on ruminant digestive function: resting salivary flow and composition in cattle - PubMed [pubmed.ncbi.nlm.nih.gov]
- To cite this document: BenchChem. [Histopathological comparison of slaframine and pilocarpine on salivary glands]. BenchChem, [2025]. [Online PDF]. Available at: [https://www.benchchem.com/product/b1196289#histopathological-comparison-of-slaframine-and-pilocarpine-on-salivary-glands]

Disclaimer & Data Validity:

The information provided in this document is for Research Use Only (RUO) and is strictly not intended for diagnostic or therapeutic procedures. While BenchChem strives to provide accurate protocols, we make no warranties, express or implied, regarding the fitness of this product for every specific experimental setup.

Technical Support: The protocols provided are for reference purposes. Unsure if this reagent suits your experiment? [[Contact our Ph.D. Support Team for a compatibility check](#)]

Need Industrial/Bulk Grade? [Request Custom Synthesis Quote](#)

BenchChem

Our mission is to be the trusted global source of essential and advanced chemicals, empowering scientists and researchers to drive progress in science and industry.

Contact

Address: 3281 E Guasti Rd
Ontario, CA 91761, United States
Phone: (601) 213-4426
Email: info@benchchem.com