

Gold-195m as a Tracer in Preclinical Animal Models: A Comparative Guide

Author: BenchChem Technical Support Team. **Date:** December 2025

Compound of Interest

Compound Name: Gold-195

Cat. No.: B1194844

[Get Quote](#)

For Researchers, Scientists, and Drug Development Professionals

The selection of an appropriate radiotracer is a critical decision in the design of preclinical imaging studies, directly impacting the quality and translational potential of the data. This guide provides a comprehensive comparison of **Gold-195m** (^{195m}Au) with other commonly used tracers in preclinical animal models, particularly for cardiovascular imaging. The information presented herein is intended to assist researchers in making informed decisions for their specific experimental needs.

Overview of Gold-195m

Gold-195m is a metastable isotope of gold with an exceptionally short half-life of 30.5 seconds. It is produced from a generator containing its parent isotope, Mercury-195m (^{195m}Hg), which has a half-life of 41.6 hours.[1][2] This generator-based production allows for on-demand elution of ^{195m}Au for imaging studies. The primary gamma emission of **Gold-195m** at 262 keV is suitable for imaging with standard gamma cameras.[3]

The key advantage of **Gold-195m** lies in its ultra-short half-life, which allows for rapid, sequential imaging studies with significantly lower radiation dose to the animal compared to longer-lived isotopes. This is particularly beneficial for dynamic studies and for longitudinal experiments requiring multiple imaging sessions in the same animal.

Comparative Analysis of Preclinical Tracers

The performance of **Gold-195m** is best understood in the context of alternative radiotracers used for similar applications. The following tables provide a comparative summary of the key physical and performance characteristics of **Gold-195m** and other common tracers for preclinical cardiac imaging.

Table 1: Physical Properties of Selected Radiotracers

Property	Gold-195m	Technetium-99m	Thallium-201	Rubidium-82
Half-life	30.5 seconds	6.02 hours	73.1 hours	76 seconds
Emission Type	Gamma	Gamma	Gamma (X-ray)	Positron (β+)
Principal Photon Energy	262 keV	140 keV	69-83 keV (X-rays)	511 keV (annihilation)
Imaging Modality	SPECT	SPECT	SPECT	PET
Production	Generator (195mHg parent)	Generator (99Mo parent)	Cyclotron	Generator (82Sr parent)

Table 2: Performance Comparison in Preclinical Models

Performance Metric	Gold-195m	Technetium-99m (Sestamibi/Tetrofosmin)	Thallium-201	Rubidium-82
Temporal Resolution	Excellent (enables rapid dynamic studies)	Good	Poor (long half-life limits dynamic studies)	Excellent (enables rapid dynamic studies)
Spatial Resolution	Good (SPECT)	Good (SPECT)	Fair (lower energy photons)	Excellent (PET)
Radiation Dose	Very Low	Moderate	High	Very Low
Myocardial Extraction	Not specified in preclinical studies	Moderate (Sestamibi: ~60%)[1]	High (~85%)[4]	Moderate
Preclinical Animal Models Used	Dogs[3]	Mice, Rats, Pigs[5][6]	Rats[7]	Rats, Dogs[8][9]
Key Advantage	Ultra-short half-life allows for repeated measurements and low radiation dose.	Widely available and well-characterized.	Good marker of myocardial viability.	High-resolution PET imaging with low radiation dose.
Key Disadvantage	Limited availability and preclinical validation data.	Longer half-life results in higher radiation dose and limits rapid sequential imaging.	High radiation dose and poor image quality due to low energy photons.	Requires a PET scanner and a dedicated generator with a shorter shelf life.

Experimental Protocols

Detailed methodologies are crucial for the replication and validation of preclinical studies. Below are representative experimental protocols for **Gold-195m** and its alternatives.

Gold-195m Cardiac Imaging in a Canine Model

This protocol is based on studies comparing **Gold-195m** and Technetium-99m for first-pass radionuclide angiocardiology in dogs.

- **Animal Preparation:** Anesthetize the dog and position it under a gamma camera.
- **Generator Elution:** Elute the $^{195\text{m}}\text{Hg}/^{195\text{m}}\text{Au}$ generator to obtain 20-25 mCi of $^{195\text{m}}\text{Au}$ in a 2 ml bolus.
- **Tracer Administration:** Inject the $^{195\text{m}}\text{Au}$ bolus intravenously.
- **Image Acquisition:** Perform a first-pass study using a computerized multicrystal gamma camera. Acquire images at short intervals to capture the dynamic passage of the tracer through the heart.
- **Data Analysis:** Calculate parameters such as left ventricular ejection fraction.
- **Comparative Study:** For comparison, a similar first-pass study can be performed on the same animal using Technetium-99m diethylenetriaminepentaacetic acid ($^{99\text{m}}\text{Tc}$ -DTPA).

Technetium-99m Sestamibi Cardiac SPECT Imaging in a Murine Model

This protocol is a representative example for myocardial perfusion imaging in mice.

- **Animal Preparation:** Anesthetize the mouse (e.g., with isoflurane or ketamine/xylazine) and place it on a heated bed to maintain body temperature. Insert a tail-vein catheter for tracer injection.
- **Tracer Administration:** Inject approximately 2.5 mCi of $^{99\text{m}}\text{Tc}$ -Sestamibi via the tail-vein catheter for a rest study. For a stress study, a pharmacological stress agent like dipyridamole is administered prior to a second, higher activity injection (~6.5 mCi).[\[10\]](#)
- **Image Acquisition:** Perform a dynamic SPECT scan for approximately 6 minutes, followed by a longer static scan. ECG gating can be used to acquire images at specific phases of the cardiac cycle.

- **Image Reconstruction and Analysis:** Reconstruct the SPECT data and draw regions of interest (VOIs) over the left ventricular myocardium and blood pool to generate time-activity curves. These curves are used to model myocardial blood flow.

Thallium-201 Myocardial Perfusion and Viability SPECT in a Rodent Model

- **Animal Preparation:** Anesthetize the rodent and position it for imaging.
- **Tracer Administration:** Inject Thallium-201 intravenously. For stress imaging, a vasodilator like adenosine or dipyridamole is administered.[\[4\]](#)
- **Image Acquisition:**
 - **Stress Imaging:** Acquire SPECT images 10-15 minutes after tracer injection at peak stress.
 - **Redistribution Imaging:** Acquire a second set of images 2.5 to 4 hours later to assess for redistribution of the tracer, which indicates viable but ischemic myocardium.[\[11\]](#)
 - **Rest/Viability Imaging:** For viability assessment, a rest injection is given, and images are acquired after 10-15 minutes, with optional delayed imaging at 3-4 or 24 hours.[\[11\]](#)
- **Data Analysis:** Compare stress and rest/redistribution images to identify fixed defects (infarct) versus reversible defects (ischemia).

Rubidium-82 Myocardial Perfusion PET in a Rat Model

This protocol is adapted from a feasibility study of ^{82}Rb -PET in rats.[\[8\]](#)

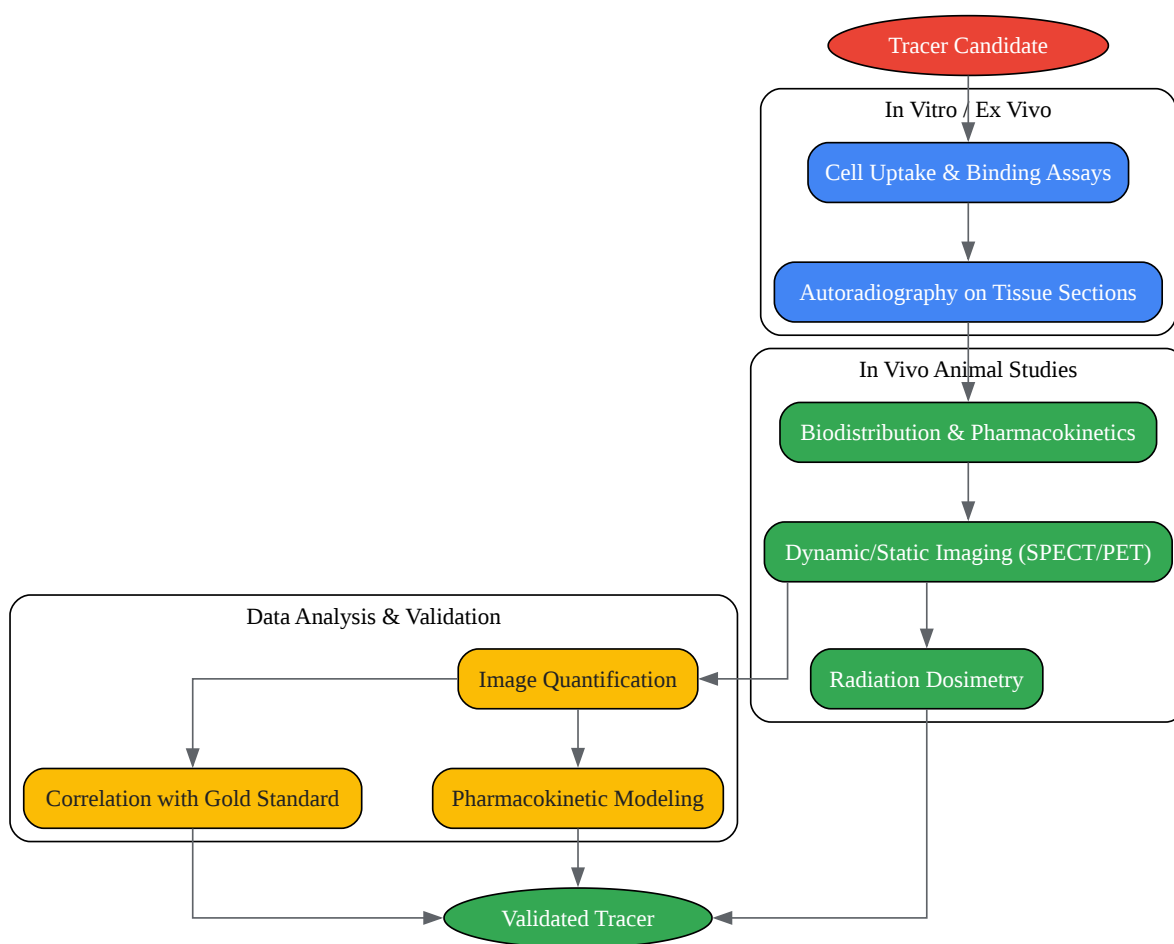
- **Animal Preparation:** Anesthetize the rat (e.g., with sevoflurane) and place a catheter in the tail vein. Position the animal in a preclinical PET/CT scanner.
- **Tracer Administration:** Infuse approximately 40 MBq of ^{82}Rb over 4-5 seconds from a clinical ^{82}Rb generator.
- **Image Acquisition:** Begin a dynamic PET acquisition simultaneously with the tracer infusion and continue for approximately 5 minutes. A CT scan can be performed for attenuation

correction and anatomical localization.[8]

- Data Analysis: Reconstruct the dynamic PET data to visualize myocardial perfusion. In infarct models, the images can delineate the area of reduced tracer uptake.

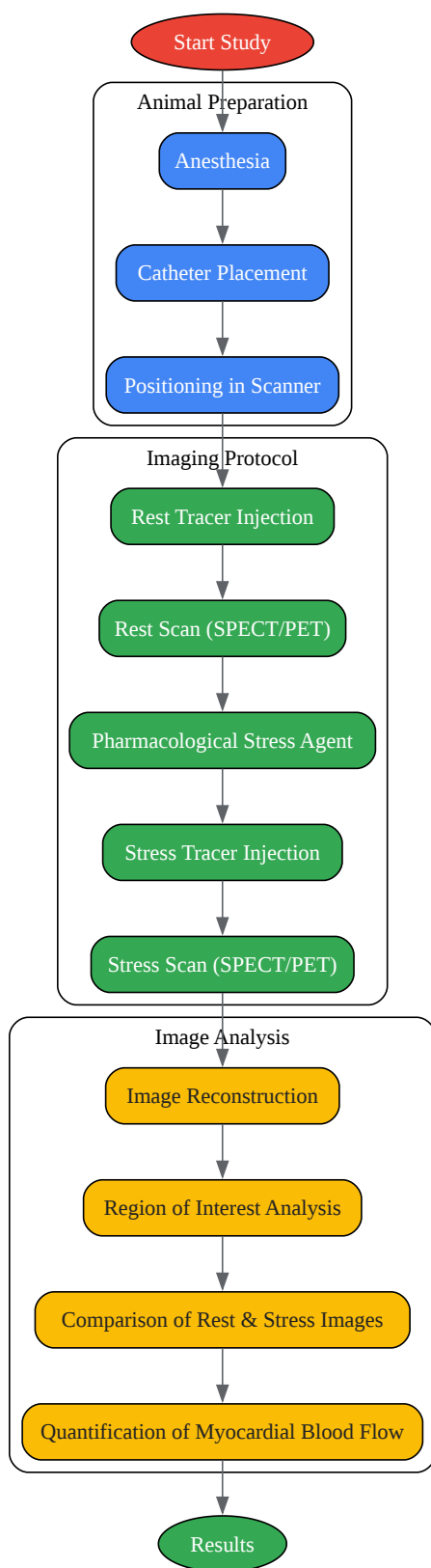
Visualizing Workflows and Relationships

To better illustrate the processes involved in tracer validation and application, the following diagrams are provided in the DOT language for Graphviz.



[Click to download full resolution via product page](#)

Caption: General workflow for preclinical validation of a novel radiotracer.



[Click to download full resolution via product page](#)

Caption: Typical workflow for a preclinical cardiac perfusion imaging study.

Conclusion

Gold-195m presents a compelling option for preclinical imaging, particularly for dynamic cardiovascular studies where low radiation dose and the ability to perform rapid, repeated measurements are paramount. Its primary limitation is the relative scarcity of comprehensive validation data in common preclinical models compared to well-established tracers like Technetium-99m sestamibi.

The choice of tracer ultimately depends on the specific research question, the available imaging instrumentation (SPECT vs. PET), and the design of the preclinical study. For longitudinal studies requiring frequent imaging, the very low radiation burden of **Gold-195m** makes it an attractive, albeit less validated, candidate. For standard myocardial perfusion studies, Technetium-99m based agents remain a reliable and well-characterized option. For studies demanding the highest spatial resolution and quantitative accuracy, PET tracers such as Rubidium-82 are superior, provided the necessary equipment is available. Researchers should carefully weigh the advantages and disadvantages of each tracer in the context of their experimental goals.

Need Custom Synthesis?

BenchChem offers custom synthesis for rare earth carbides and specific isotopic labeling.

Email: info@benchchem.com or [Request Quote Online](#).

References

- 1. jnm.snmjournals.org [jnm.snmjournals.org]
- 2. Gold-195m, an ultra-short-lived generator-produced radionuclide: clinical application in sequential first pass ventriculography - PubMed [pubmed.ncbi.nlm.nih.gov]
- 3. A 195Hgm-195Aum generator for use in first-pass nuclear angiocardiology - PubMed [pubmed.ncbi.nlm.nih.gov]
- 4. Feasibility of positron range correction in 82-Rubidium cardiac PET/CT - PMC [pmc.ncbi.nlm.nih.gov]
- 5. Review: comparison of PET rubidium-82 with conventional SPECT myocardial perfusion imaging - PMC [pmc.ncbi.nlm.nih.gov]

- 6. Cardiac Radionuclide Imaging in Rodents: A Review of Methods, Results, and Factors at Play - PMC [pmc.ncbi.nlm.nih.gov]
- 7. Rubidium-82 PET imaging is feasible in a rat myocardial infarction model - PubMed [pubmed.ncbi.nlm.nih.gov]
- 8. Story of Rubidium-82 and Advantages for Myocardial Perfusion PET Imaging - PMC [pmc.ncbi.nlm.nih.gov]
- 9. portal.fis.tum.de [portal.fis.tum.de]
- 10. A Novel Experimental Rat Model for the In Vivo Assessment of Myocardial Ischemia Based on Single Photon Emission Computed Tomography - PMC [pmc.ncbi.nlm.nih.gov]
- 11. Perfusion imaging using rubidium-82 (82Rb) PET in rats with myocardial infarction: First small animal cardiac 82Rb-PET - PMC [pmc.ncbi.nlm.nih.gov]
- To cite this document: BenchChem. [Gold-195m as a Tracer in Preclinical Animal Models: A Comparative Guide]. BenchChem, [2025]. [Online PDF]. Available at: [https://www.benchchem.com/product/b1194844#validation-of-gold-195-as-a-tracer-in-preclinical-animal-models]

Disclaimer & Data Validity:

The information provided in this document is for Research Use Only (RUO) and is strictly not intended for diagnostic or therapeutic procedures. While BenchChem strives to provide accurate protocols, we make no warranties, express or implied, regarding the fitness of this product for every specific experimental setup.

Technical Support: The protocols provided are for reference purposes. Unsure if this reagent suits your experiment? [[Contact our Ph.D. Support Team for a compatibility check](#)]

Need Industrial/Bulk Grade? [Request Custom Synthesis Quote](#)

BenchChem

Our mission is to be the trusted global source of essential and advanced chemicals, empowering scientists and researchers to drive progress in science and industry.

Contact

Address: 3281 E Guasti Rd

Ontario, CA 91761, United States

Phone: (601) 213-4426

Email: info@benchchem.com

