

# Fluciclovine (18F) Image Interpretation: A Technical Support Center

**Author:** BenchChem Technical Support Team. **Date:** December 2025

## Compound of Interest

Compound Name: *Fluciclovine (18F)*

Cat. No.: *B1218386*

[Get Quote](#)

This technical support center provides troubleshooting guides and frequently asked questions (FAQs) to address common challenges encountered during **Fluciclovine (18F)** PET/CT image interpretation. The information is tailored for researchers, scientists, and drug development professionals to ensure accurate and consistent experimental outcomes.

## Troubleshooting Guides

This section provides solutions to specific problems that may arise during the **Fluciclovine (18F)** imaging workflow, from patient preparation to image analysis.

**Question:** What are the critical patient preparation steps to avoid altered biodistribution of **Fluciclovine (18F)**?

**Answer:** Proper patient preparation is crucial for accurate **Fluciclovine (18F)** image interpretation. Failure to adhere to guidelines can lead to altered biodistribution and potential misinterpretation.

- **Fasting:** Patients should fast for at least four hours before the scan.<sup>[1]</sup> Food intake can alter plasma amino acid levels, potentially affecting tracer uptake.
- **Exercise:** Strenuous physical activity should be avoided for at least one day prior to imaging. <sup>[1]</sup> Exercise can increase muscle uptake of **Fluciclovine (18F)**, which may obscure adjacent lesions.<sup>[1][2]</sup>

- Voiding: Patients should be encouraged to void before the scan begins to minimize urinary activity that could interfere with the pelvic region assessment.[3]

Question: How can artifacts related to the injection and scanning procedure be minimized?

Answer: Several procedural factors can introduce artifacts in **Fluciclovine (18F)** PET/CT images.

- Injection Site: It is preferable to inject the tracer into the right arm.[2][4] Stasis in the left axillary vein could be misinterpreted as a metastatic lymph node (Virchow's node).[2]
- Patient Positioning: The patient should be positioned supine with their arms above their head if possible.[2][4] If this is not tolerable, an alternative arm position can be used, but the potential for artifacts should be noted.[3]
- Breathing: Patients should be instructed to breathe shallowly during both CT and PET acquisition to prevent respiratory motion artifacts.[5]
- Contrast Media: If intravenous or oral contrast is used for the CT scan, it may cause attenuation correction artifacts.[5] When possible, obtain the contrast-enhanced CT images after the PET acquisition.[5]

Question: My images show high muscle uptake. What could be the cause and how do I interpret the scan?

Answer: Increased muscle uptake is a known potential pitfall.

- Cause: This is often due to the patient not avoiding significant exercise for at least a day before the scan.[1]
- Interpretation: If high muscle uptake is observed, this should be taken into account during image interpretation as it may alter the biodistribution and potentially mask nearby lesions.[2] The clinical history regarding recent physical activity is crucial.

## Frequently Asked Questions (FAQs)

This section addresses common questions regarding the interpretation of **Fluciclovine (18F)** PET/CT images.

## Physiological and Benign Uptake

Question: What are the common sites of physiological **Fluciclovine (18F)** uptake?

Answer: Understanding the normal biodistribution of **Fluciclovine (18F)** is essential to avoid misinterpreting physiological uptake as malignant disease. Common sites include:

- Liver and Pancreas: These organs typically show the highest physiological uptake.[4][6]
- Bone Marrow: Heterogeneous uptake in the bone marrow is normal.[7]
- Salivary Glands and Pituitary Gland: Mild uptake is physiologic.[4][8]
- Muscles: Variable, typically low-level uptake is seen.[8]
- Bowel: Variable activity can be present in the bowel.[4]
- Celiac Ganglia: Physiological uptake in the celiac ganglia can occur and may be mistaken for metastatic lymphadenopathy.[9]

Question: How can I differentiate between benign prostatic hyperplasia (BPH) and prostate cancer?

Answer: Differentiating BPH from prostate cancer can be challenging as both can demonstrate **Fluciclovine (18F)** uptake.

- SUV overlap: Studies have shown a significant overlap in the standardized uptake values (SUV) between BPH and prostate cancer.[7][10] In one study, the mean SUVmax in prostate cancer was  $4.5 \pm 0.5$ , while in BPH it was  $4.3 \pm 0.6$ . [7]
- Adjunctive Imaging: Combining **Fluciclovine (18F)** PET with multiparametric MRI (mpMRI) has been shown to increase the positive predictive value for detecting primary prostate cancer.[4][7]

Question: What is the significance of uptake in inguinal lymph nodes?

Answer: Uptake in inguinal lymph nodes is a common finding.

- Benign Reactive Nodes: Mild, symmetric uptake in inguinal lymph nodes is often considered benign and reactive.[5][11]
- Suspicious Uptake: Unilateral or intense uptake, especially in the context of a clear pattern of disease extending from the pelvis, should be considered suspicious.[4][5]

### Image Interpretation and Reporting

Question: What are the general criteria for interpreting a **Fluciclovine (18F)** PET/CT scan as positive for recurrent prostate cancer?

Answer: Interpretation is primarily visual and qualitative, comparing suspicious lesions to background activity.[12]

- Prostate Bed/Local Recurrence: Any focal uptake in the prostatectomy bed that is greater than the surrounding background is considered suspicious.[4]
- Lymph Nodes: For larger lesions ( $\geq 1$  cm), uptake equal to or greater than bone marrow is suspicious. For smaller lesions ( $< 1$  cm), focal uptake greater than the blood pool is considered suspicious.[2]
- Bone Lesions: Focal uptake that is clearly visualized on maximum intensity projection (MIP) images is considered suspicious for metastatic disease.[4][7] It is important to note that densely sclerotic lesions may not show significant uptake.[4][7]

Question: How does the Prostate-Specific Antigen (PSA) level affect the detection rate of **Fluciclovine (18F)** PET/CT?

Answer: The detection rate of **Fluciclovine (18F)** PET/CT is directly correlated with the patient's PSA level.[8] Generally, the higher the PSA, the higher the likelihood of a positive scan.[13] However, positive scans can still occur at low PSA levels, particularly with a rapid PSA doubling time.[4]

PSA Level (ng/mL)	Positive Scan Rate
< 0.5	Up to 53% <a href="#">[13]</a>
< 1.0	37.5% <a href="#">[4]</a>
1.0 to 2.0	77.8% <a href="#">[4]</a>
> 2.0 to 5.0	91.7% <a href="#">[4]</a>
≥ 5.0	94% <a href="#">[14]</a>
> 5.0	83.3% <a href="#">[4]</a>

Question: Can **Fluciclovine (18F)** be used to image other cancers besides prostate cancer?

Answer: Yes, **Fluciclovine (18F)** uptake is not specific to prostate cancer. It targets upregulated amino acid transport, a hallmark of many malignancies.[\[10\]](#)[\[15\]](#) It has been investigated in other cancers, including breast cancer and glioma.[\[6\]](#)[\[16\]](#) Incidentally detected neoplasms have been reported on **Fluciclovine (18F)** PET/CT scans performed for prostate cancer.[\[15\]](#)

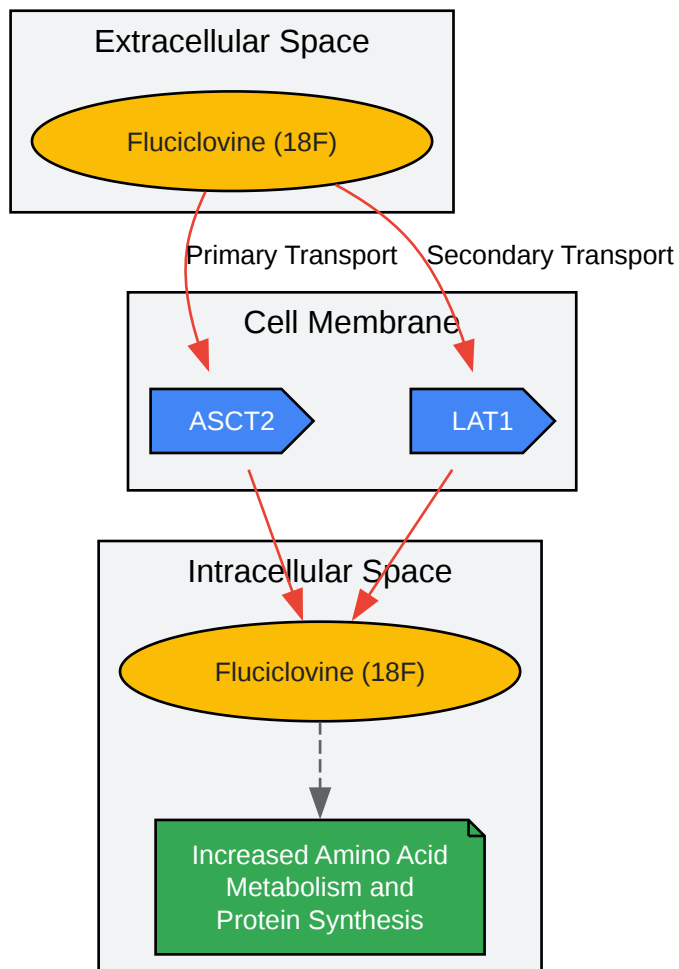
## Experimental Protocols

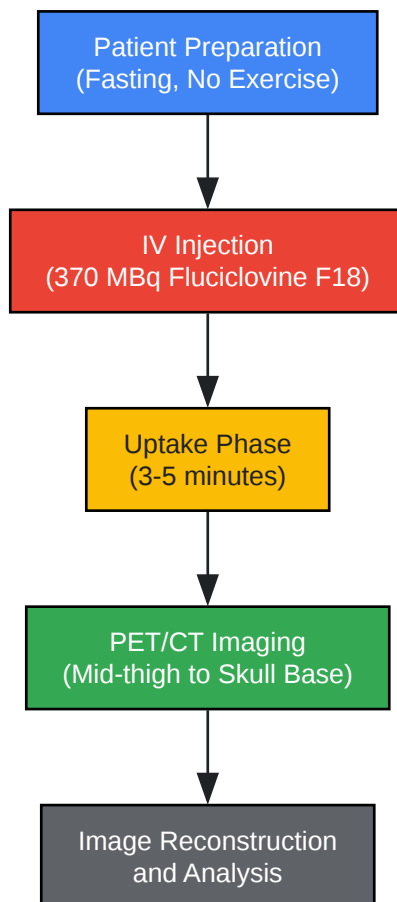
Detailed Methodology for a Standard **Fluciclovine (18F)** PET/CT Scan

- Patient Preparation:
  - No significant exercise for at least 24 hours.[\[1\]](#)
  - Fast for a minimum of 4 hours (water and medications are permitted).[\[1\]](#)
  - Encourage the patient to void immediately before the scan.[\[3\]](#)
- Dose Administration:
  - Administer a 370 MBq (10 mCi) intravenous bolus of **Fluciclovine (18F)**.[\[2\]](#)
  - Inject into the right arm if possible to avoid potential misinterpretation of venous stasis on the left.[\[2\]](#)[\[4\]](#)

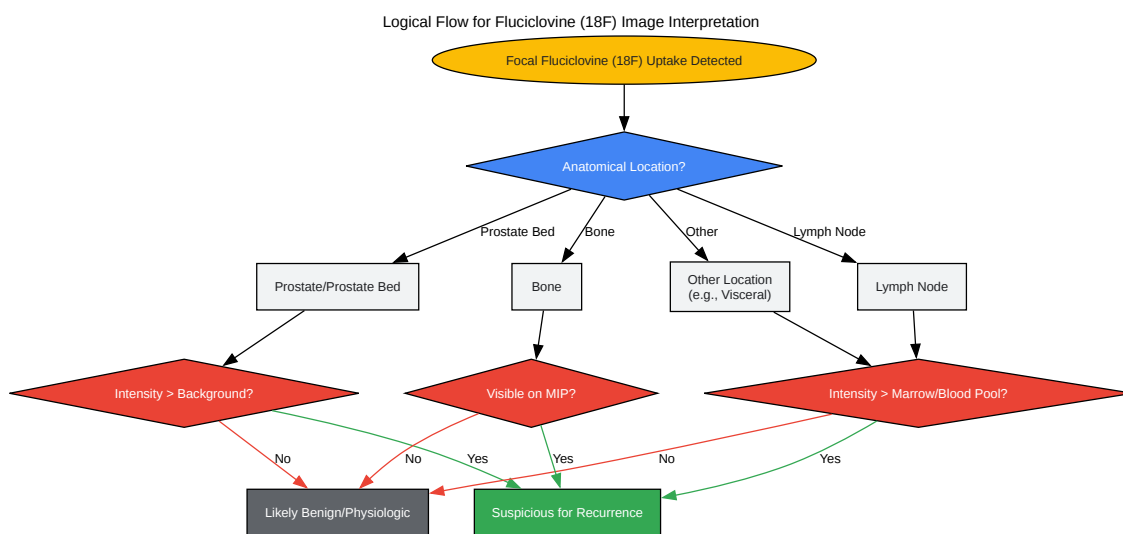
- Follow the injection with a flush of sterile 0.9% sodium chloride.[\[2\]](#)[\[4\]](#)
- Image Acquisition:
  - Position the patient supine with arms above the head.[\[2\]](#)
  - Begin PET scanning 3 to 5 minutes after the injection.[\[2\]](#)
  - Acquire images from the mid-thigh to the base of the skull.[\[2\]](#)[\[5\]](#)
  - A high-quality CT scan for attenuation correction and anatomical localization is recommended.[\[2\]](#)
  - Typical total scan time is 20 to 30 minutes.[\[2\]](#)

## Visualizations

Fluciclovine ( $^{18}\text{F}$ ) Cellular Uptake Pathway

Fluciclovine ( $^{18}\text{F}$ ) PET/CT Experimental Workflow





[Click to download full resolution via product page](#)

#### Need Custom Synthesis?

BenchChem offers custom synthesis for rare earth carbides and specific isotopic labeling.

Email: [info@benchchem.com](mailto:info@benchchem.com) or [Request Quote Online](#).

## References

- 1. [snmmi.org](http://snmmi.org) [[snmmi.org](http://snmmi.org)]
- 2. [axumin.com](http://axumin.com) [[axumin.com](http://axumin.com)]
- 3. [radiology.unm.edu](http://radiology.unm.edu) [[radiology.unm.edu](http://radiology.unm.edu)]
- 4. [med.emory.edu](http://med.emory.edu) [[med.emory.edu](http://med.emory.edu)]
- 5. [tech.snmjournals.org](http://tech.snmjournals.org) [[tech.snmjournals.org](http://tech.snmjournals.org)]
- 6. Characterising 18F-fluciclovine uptake in breast cancer through the use of dynamic PET/CT imaging - PMC [[pmc.ncbi.nlm.nih.gov](http://pmc.ncbi.nlm.nih.gov)]
- 7. Update on 18F-Fluciclovine PET for Prostate Cancer Imaging - PMC [[pmc.ncbi.nlm.nih.gov](http://pmc.ncbi.nlm.nih.gov)]
- 8. Understanding and Improving 18F-Fluciclovine PET/CT Reports: A Guide for Physicians Treating Patients with Biochemical Recurrence of Prostate Cancer - PMC [[pmc.ncbi.nlm.nih.gov](http://pmc.ncbi.nlm.nih.gov)]
- 9. 18F-Fluciclovine Uptake in Celiac Ganglia: A Pitfall in Prostate Cancer PET Imaging - PubMed [[pubmed.ncbi.nlm.nih.gov](http://pubmed.ncbi.nlm.nih.gov)]
- 10. 18F-Fluciclovine Positron Emission Tomography in Prostate Cancer: A Systematic Review and Diagnostic Meta-Analysis - PMC [[pmc.ncbi.nlm.nih.gov](http://pmc.ncbi.nlm.nih.gov)]
- 11. When PSMA PET Is Negative: 18F-Fluciclovine in BCR of PC | GU Oncology Now [[guoncologynow.com](http://guoncologynow.com)]
- 12. [researchgate.net](http://researchgate.net) [[researchgate.net](http://researchgate.net)]
- 13. 18F-Fluciclovine PET/CT performance in biochemical recurrence of prostate cancer: a systematic review - PMC [[pmc.ncbi.nlm.nih.gov](http://pmc.ncbi.nlm.nih.gov)]
- 14. [urologytimes.com](http://urologytimes.com) [[urologytimes.com](http://urologytimes.com)]
- 15. [jnm.snmjournals.org](http://jnm.snmjournals.org) [[jnm.snmjournals.org](http://jnm.snmjournals.org)]
- 16. [researchgate.net](http://researchgate.net) [[researchgate.net](http://researchgate.net)]
- To cite this document: BenchChem. [Fluciclovine (18F) Image Interpretation: A Technical Support Center]. BenchChem, [2025]. [Online PDF]. Available at: [<https://www.benchchem.com/product/b1218386#overcoming-challenges-in-fluciclovine-18f-image-interpretation>]

---

### Disclaimer & Data Validity:

The information provided in this document is for Research Use Only (RUO) and is strictly not intended for diagnostic or therapeutic procedures. While BenchChem strives to provide

accurate protocols, we make no warranties, express or implied, regarding the fitness of this product for every specific experimental setup.

**Technical Support:** The protocols provided are for reference purposes. Unsure if this reagent suits your experiment? [[Contact our Ph.D. Support Team for a compatibility check](#)]

**Need Industrial/Bulk Grade?** [Request Custom Synthesis Quote](#)

## BenchChem

Our mission is to be the trusted global source of essential and advanced chemicals, empowering scientists and researchers to drive progress in science and industry.

### Contact

Address: 3281 E Guasti Rd  
Ontario, CA 91761, United States  
Phone: (601) 213-4426  
Email: [info@benchchem.com](mailto:info@benchchem.com)