

False-positive findings on Ga-68 Dotatate scans and their causes

Author: BenchChem Technical Support Team. **Date:** December 2025

Compound of Interest

Compound Name: Dotatate

Cat. No.: B15554293

[Get Quote](#)

Technical Support Center: Ga-68 DOTATATE PET/CT

This technical support center provides troubleshooting guides and frequently asked questions (FAQs) regarding false-positive findings on Gallium-68 (Ga-68) DOTATATE PET/CT scans. The information is intended for researchers, scientists, and drug development professionals.

Frequently Asked Questions (FAQs)

Q1: What are the common causes of false-positive findings on a Ga-68 DOTATATE scan?

False-positive findings on Ga-68 DOTATATE scans can be broadly categorized into three main groups:

- **Physiological Biodistribution:** High expression of somatostatin receptors (SSTRs) in certain normal tissues leads to intense tracer uptake that can sometimes be mistaken for pathology.
- **Inflammatory and Infectious Processes:** Activated white blood cells, particularly macrophages and leukocytes, can express SSTRs, leading to Ga-68 DOTATATE accumulation at sites of inflammation or infection.^[1]
- **Benign Tumors:** A variety of benign (non-cancerous) tumors can also express SSTRs and therefore show uptake on a DOTATATE scan.

Q2: Which normal organs show high physiological uptake of Ga-68 DOTATATE?

Several organs normally demonstrate significant Ga-68 DOTATATE uptake due to high SSTR expression. The most prominent of these include:

- Spleen: Typically shows the highest uptake in the body.
- Kidneys: Involved in the excretion of the radiotracer.
- Adrenal Glands: All five SSTR subtypes are present in the adrenal glands.[2]
- Pituitary Gland: Exhibits avid uptake.[1]
- Liver and Pancreas: The liver shows moderate uptake, while the pancreas can show heterogeneous activity, particularly in the uncinate process, which has a higher expression of SSTR2.[1][2]
- Thyroid and Salivary Glands: Also demonstrate moderate uptake.[1][2]

It is crucial to be aware of this normal biodistribution to avoid misinterpretation of scan results.
[1]

Q3: Can inflammation cause a false-positive Ga-68 DOTATATE scan?

Yes, active inflammatory processes are a known cause of false-positive findings.[1]

Somatostatin receptors are expressed on activated white blood cells, leading to tracer accumulation in conditions such as:

- Reactive or inflammatory lymph nodes[3]
- Prostatitis[1]
- Post-surgical inflammation[3]
- Radiation-induced inflammation[1]
- Granulomatous diseases like sarcoidosis[4]

- Infections (e.g., *Cryptococcus neoformans*)[5]
- Arthritis[3]
- Atherosclerotic plaques[1]

The intensity of uptake in inflammatory lesions is often low-grade.[5]

Q4: Which benign tumors can show uptake on a Ga-68 DOTATATE scan?

Several benign tumors have been reported to show Ga-68 DOTATATE avidity, which can lead to false-positive interpretations. These include:

- Meningioma: A common intracranial tumor that often expresses SSTRs.[3]
- Vertebral Hemangioma: A benign tumor of the vertebrae.[6]
- Fibrous Dysplasia: A bone disorder that can mimic bone metastases.[3]
- Accessory Spleens (Splenunculi) and Splenosis: Due to the high SSTR expression in splenic tissue.[1][3]
- Breast Fibroadenoma: Can demonstrate mild uptake.[3]
- Gynecomastia: Benign breast tissue enlargement in males has been reported to show uptake.[7][8]

Q5: How can I differentiate a true-positive from a false-positive finding?

Differentiating true-positive from false-positive findings requires a multi-faceted approach:

- Correlate with Anatomical Imaging: Careful review of the co-registered CT or MRI is essential. Morphological features of the lesion can provide clues to its nature.
- Consider the Clinical Context: The patient's history, symptoms, and other laboratory findings are crucial for accurate interpretation.

- Evaluate the Intensity of Uptake (SUVmax): While there is overlap, the intensity of uptake in malignant lesions is often significantly higher than in inflammatory or many benign conditions.[5][9]
- Follow-up Imaging: In equivocal cases, follow-up imaging can help to assess the stability or resolution of the finding.
- Biopsy: Histopathological confirmation remains the gold standard for definitive diagnosis.

Troubleshooting Guides

Guide 1: Unexpected Uptake in the Pancreas

- Issue: Focal uptake is observed in the uncinate process of the pancreas.
- Troubleshooting Steps:
 - Evaluate Morphology on CT/MRI: Is there a discrete, enhancing mass, or does the uptake correspond to normal-appearing pancreatic tissue?
 - Assess Uptake Pattern: Uptake in the uncinate process is a common physiological variant and is often ill-defined.[1] In contrast, neuroendocrine tumors of the pancreas are typically well-circumscribed.
 - Clinical Correlation: Does the patient have symptoms or biochemical markers suggestive of a pancreatic neuroendocrine tumor?
 - Consider Endoscopic Ultrasound (EUS): If suspicion remains high, EUS with fine-needle aspiration can provide a definitive diagnosis.

Guide 2: Multiple Small Foci of Uptake in Bones

- Issue: Several small areas of increased tracer uptake are seen in the skeletal system.
- Troubleshooting Steps:
 - Examine the CT Component: Look for corresponding lytic or sclerotic lesions. Degenerative changes, fractures, or benign bone lesions like fibrous dysplasia can also show uptake.[3][10]

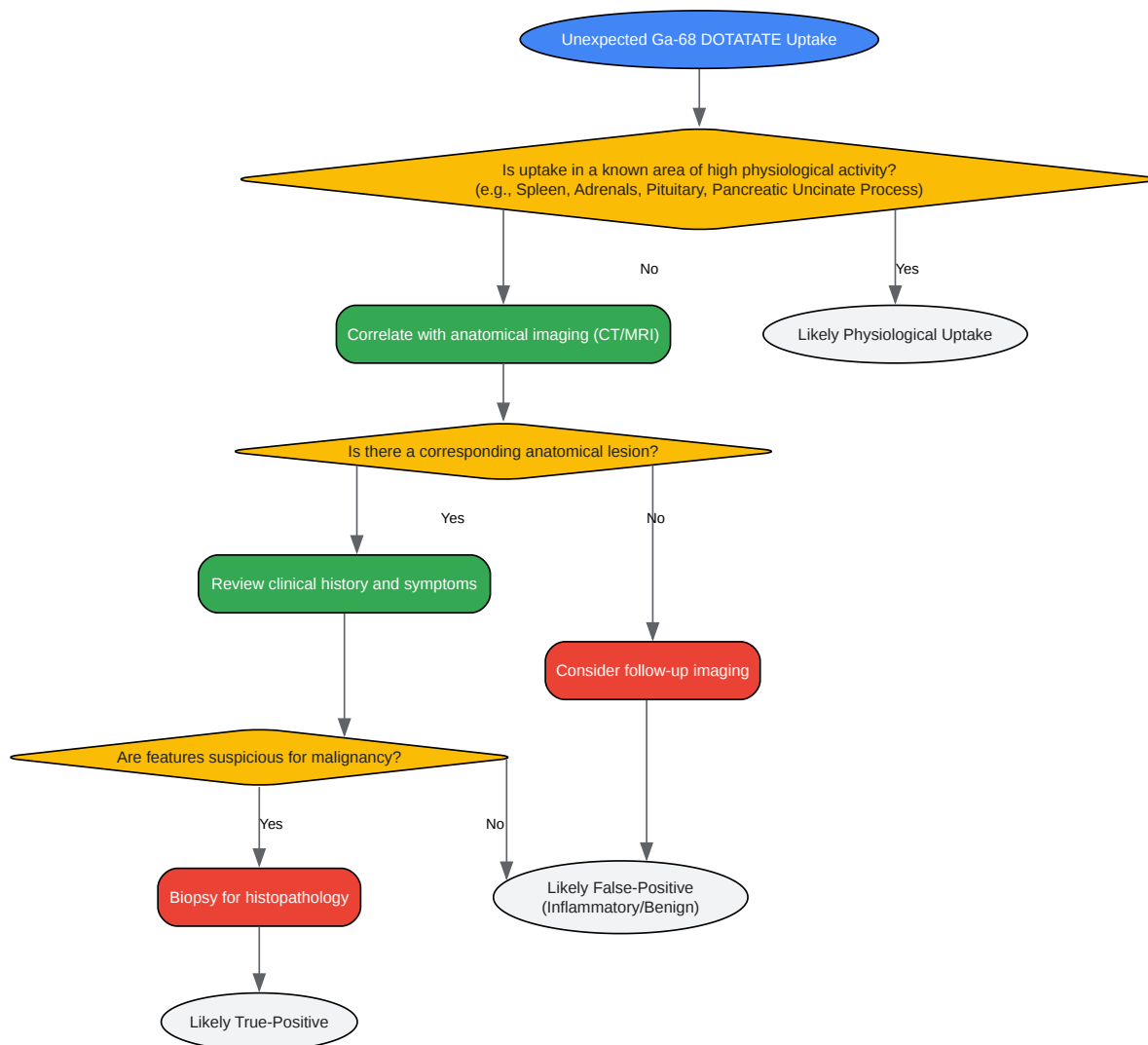- Review Patient History: Has the patient had recent trauma or surgery? Is there a history of arthritis?[3]
- Consider Other Imaging Modalities: A bone scan or MRI may help to further characterize the lesions.
- Biopsy: If metastatic disease is suspected and would alter management, a biopsy of an accessible lesion may be necessary.

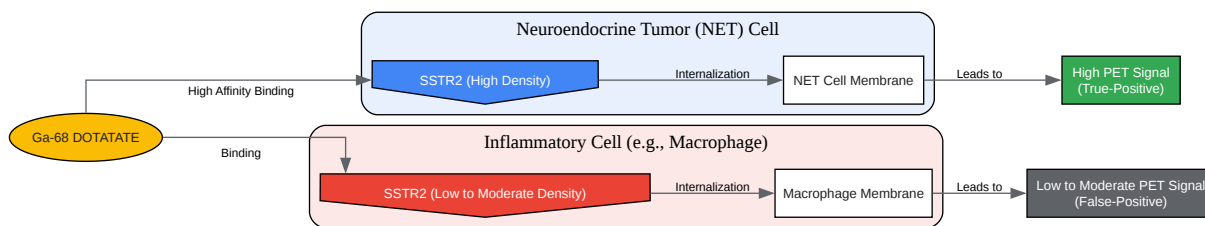
Data Presentation

Table 1: Standardized Uptake Values (SUVmax) in Normal Organs and False-Positive Findings

Tissue/Lesion Type	Mean SUVmax (Range)	Reference
Normal Organs		
Spleen	24.67	[3]
Kidneys	14.30	[3]
Adrenal Glands	13.73	[3]
Pituitary Gland	9.74	[3]
Liver	9.12	[3]
Pancreas (Head)	4.94	[2]
Pancreas (Body)	4.46	[2]
Thyroid Gland	1.48 - 10.97	[2]
False-Positive Benign Tumors		
Meningioma	Significant Uptake	[3]
Fibrous Dysplasia	Significant Uptake	[3]
Breast Fibroadenoma	Mild Uptake	[3]
False-Positive Inflammatory Conditions		
Post-surgical Inflammation	Faint to Mild Uptake	[3]
Reactive Lymph Nodes	Faint to Mild Uptake	[3]
Arthritis	Faint to Mild Uptake	[3]

Visualizations





[Click to download full resolution via product page](#)

Need Custom Synthesis?

BenchChem offers custom synthesis for rare earth carbides and specific isotopic labeling.

Email: info@benchchem.com or [Request Quote Online](#).

References

1. Frontiers | Normal Variants, Pitfalls and Artifacts in Ga-68 DOTATATE PET/CT Imaging [frontiersin.org]
2. Physiological Biodistribution of 68Ga-DOTA-TATE in Normal Subjects - PMC [pmc.ncbi.nlm.nih.gov]
3. Physiological and tumoral uptake of (68)Ga-DOTATATE: standardized uptake values and challenges in interpretation - PubMed [pubmed.ncbi.nlm.nih.gov]
4. radiopaedia.org [radiopaedia.org]
5. atsjournals.org [atsjournals.org]
6. False Positive Findings of 68Ga-DOTATOC PET/CT: A Systematic Review - PMC [pmc.ncbi.nlm.nih.gov]
7. Normal Variants, Pitfalls and Artifacts in Ga-68 DOTATATE PET/CT Imaging - PMC [pmc.ncbi.nlm.nih.gov]
8. researchgate.net [researchgate.net]
9. webcir.org [webcir.org]

- 10. tech.snmjournals.org [tech.snmjournals.org]
- To cite this document: BenchChem. [False-positive findings on Ga-68 Dotatate scans and their causes]. BenchChem, [2025]. [Online PDF]. Available at: [https://www.benchchem.com/product/b15554293#false-positive-findings-on-ga-68-dotatate-scans-and-their-causes]

Disclaimer & Data Validity:

The information provided in this document is for Research Use Only (RUO) and is strictly not intended for diagnostic or therapeutic procedures. While BenchChem strives to provide accurate protocols, we make no warranties, express or implied, regarding the fitness of this product for every specific experimental setup.

Technical Support: The protocols provided are for reference purposes. Unsure if this reagent suits your experiment? [[Contact our Ph.D. Support Team for a compatibility check](#)]

Need Industrial/Bulk Grade? [Request Custom Synthesis Quote](#)

BenchChem

Our mission is to be the trusted global source of essential and advanced chemicals, empowering scientists and researchers to drive progress in science and industry.

Contact

Address: 3281 E Guasti Rd
Ontario, CA 91761, United States
Phone: (601) 213-4426
Email: info@benchchem.com