

Evaluating the Diagnostic Accuracy of Indium-111 WBC Scan: A Comparative Guide

Author: BenchChem Technical Support Team. **Date:** December 2025

Compound of Interest

Compound Name: Indium-111

Cat. No.: B102479

[Get Quote](#)

For Researchers, Scientists, and Drug Development Professionals

The **Indium-111** (In-111) labeled white blood cell (WBC) scan is a cornerstone in nuclear medicine for diagnosing occult infections. This guide provides an objective comparison of the In-111 WBC scan with other prominent imaging modalities, supported by experimental data to aid in the selection of the most appropriate diagnostic tool for various clinical and research applications.

Overview of Indium-111 WBC Scintigraphy

In-111 WBC scintigraphy leverages the natural inflammatory response of the body. Leukocytes, primarily neutrophils, are extracted from the patient's blood, labeled with the radioisotope **Indium-111** oxine, and then reinjected. These radiolabeled cells migrate to and accumulate at sites of infection or inflammation, allowing for visualization via a gamma camera.^{[1][2]} This technique is particularly valuable for detecting infections in locations where other imaging modalities may be inconclusive.^[1]

Comparative Diagnostic Accuracy

The diagnostic performance of any imaging technique is paramount. The following table summarizes the sensitivity, specificity, and accuracy of the In-111 WBC scan in comparison to other common radionuclide imaging techniques for various infectious and inflammatory conditions.

Imaging Modality	Condition	Sensitivity (%)	Specificity (%)	Accuracy (%)
Indium-111 WBC Scan	Skeletal Infection (General)	83	90	88[3]
Osteomyelitis (Acute)	90-95	-	-[4]	
Osteomyelitis (Complicated)	97	82	92[5]	
Prosthetic Joint Infection	74-92	68-92	-[1]	
Diabetic Foot Osteomyelitis	100	70	86[6]	
Intra-abdominal Abscess	95	91	-[7]	
Fever of Unknown Origin	81	87	85[3]	
Gallium-67 Citrate Scan	Occult Sepsis	81	-	-[8]
Chronic Bone Infection	80	83	-[9]	
Technetium-99m HMPAO-WBC Scan	Intra-abdominal Sepsis (4-hour)	100	62	-[10]
Pelvic Inflammatory Disease	100	90	-[7]	
Knee Prosthesis Infection	84	52	-[7]	
FDG-PET/CT	Prosthetic Joint Infection	95	93	-[1]

Bloodstream Infections	91	88	-[11]
Large Vessel Vasculitis	77-92	89-100	-[12]

Experimental Protocols

Detailed methodologies are crucial for the reproducibility and interpretation of experimental results. Below are the generalized protocols for the key imaging techniques discussed.

Indium-111 WBC Scan Protocol

- **Blood Collection:** 40 to 80 mL of whole blood is aseptically collected from the patient using a large-bore needle to minimize cell damage.[1]
- **Leukocyte Separation:** The collected blood is processed to separate the white blood cells from red blood cells and plasma. This is typically achieved through sedimentation, sometimes aided by agents like hetastarch.
- **Radiolabeling:** The isolated leukocytes are incubated with **Indium-111** oxine (approximately 20 MBq).[13] The lipophilic In-111 oxine complex passively diffuses across the WBC membrane, where the In-111 dissociates and binds to intracellular components.
- **Quality Control:** A sample of the labeled cells is assessed for labeling efficiency.
- **Re-injection:** The In-111 labeled WBCs are carefully re-injected into the patient. It is critical to ensure the patient receives their own cells.[14]
- **Imaging:** Planar and SPECT (Single Photon Emission Computed Tomography) images are typically acquired 18 to 24 hours post-injection, allowing sufficient time for the labeled cells to migrate to the site of infection.[1][14] In some cases, earlier imaging at 4 hours may be performed.[15]

Gallium-67 Citrate Scan Protocol

- Radiopharmaceutical Administration: The patient is injected intravenously with 111-222 MBq (3-6 mCi) of Gallium-67 citrate.[16]
- Imaging Schedule: Imaging is performed at 24, 48, and sometimes 72 hours post-injection using a gamma camera equipped with a medium-energy collimator.[16][17]
- Patient Preparation: To minimize bowel artifact, laxatives may be administered as Gallium-67 is excreted through the gastrointestinal tract.[18]

Technetium-99m HMPAO-WBC Scan Protocol

The initial steps of blood collection and leukocyte separation are similar to the In-111 WBC scan.

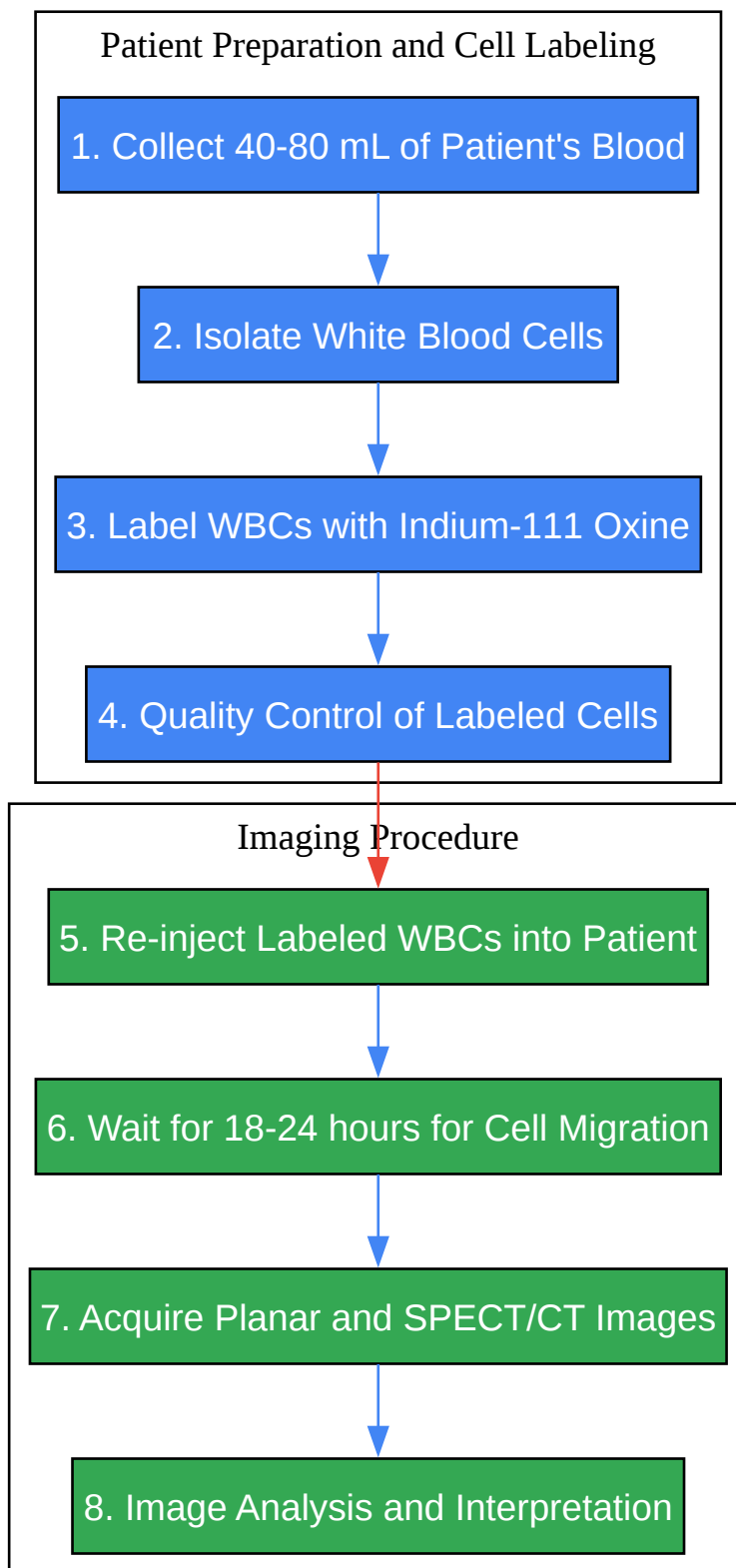
- Radiolabeling: The isolated white blood cells are labeled with Technetium-99m (Tc-99m) hexamethylpropyleneamine oxime (HMPAO).
- Re-injection: The Tc-99m HMPAO-labeled WBCs are re-injected into the patient.
- Imaging: Imaging is performed much earlier than with In-111, typically at 1 to 4 hours post-injection.[19] This is due to the shorter half-life of Tc-99m (6 hours) compared to In-111 (2.8 days).[14][20]

18F-FDG PET/CT Protocol

- Patient Preparation: Patients are required to fast for at least 6 hours to lower blood glucose levels and reduce myocardial glucose uptake.
- Radiopharmaceutical Administration: The patient is injected with 18F-Fluorodeoxyglucose (FDG), a glucose analog.
- Uptake Period: There is an uptake period of approximately 60 minutes to allow for the distribution of FDG throughout the body.
- Imaging: A whole-body PET/CT scan is performed. The PET component detects the metabolic activity of FDG uptake, while the CT provides anatomical localization.

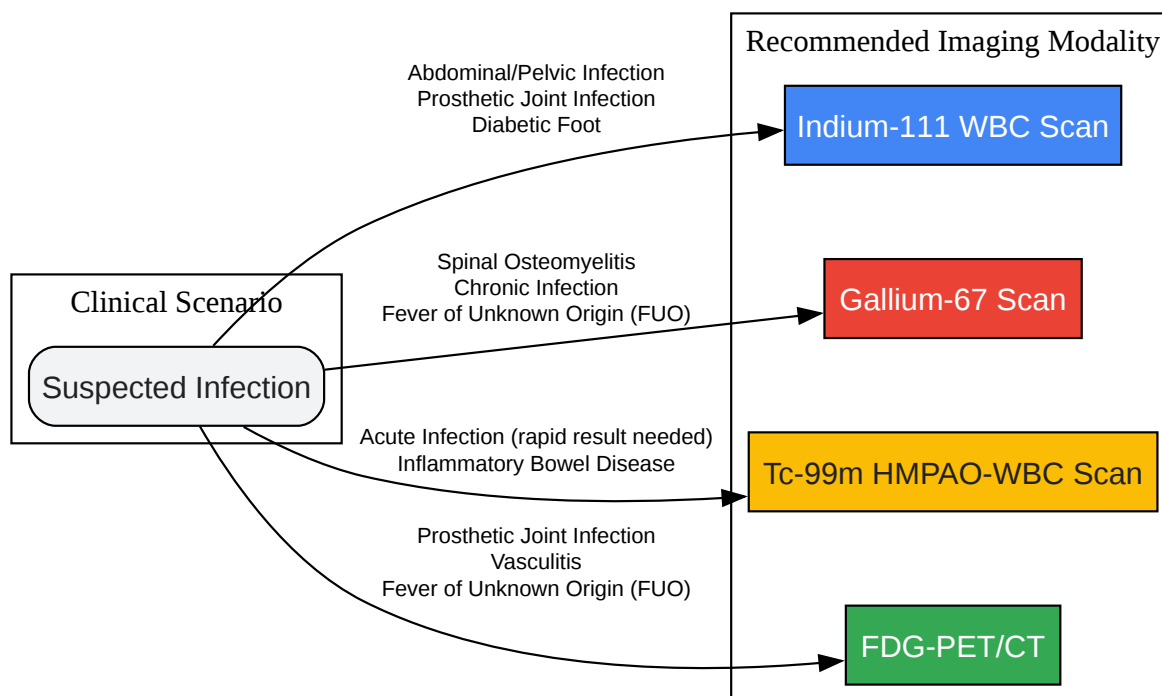
Visualizing the Process and Decision Making

To better understand the workflow and the clinical decision-making process, the following diagrams are provided.



[Click to download full resolution via product page](#)

Indium-111 WBC Scan Experimental Workflow

[Click to download full resolution via product page](#)

Choice of Imaging Modality Based on Clinical Indication

Discussion and Comparison

Indium-111 WBC Scan

The In-111 WBC scan is highly specific for localizing neutrophilic inflammation, making it a robust tool for diagnosing bacterial infections.[1] Its long half-life allows for delayed imaging, which can be advantageous in chronic or low-grade infections.[1] A significant advantage in abdominal imaging is the minimal physiological bowel excretion of In-111 labeled leukocytes, reducing the likelihood of false positives compared to Tc-99m HMPAO-WBC scans.[1][10] However, the procedure is labor-intensive, involves handling of blood products, and delivers a

relatively high radiation dose to the patient.[1] Furthermore, its sensitivity may be reduced in chronic infections, particularly in spinal conditions like vertebral osteomyelitis.[1]

Gallium-67 Citrate Scan

Gallium-67 citrate accumulates at sites of inflammation, infection, and neoplasia. It is particularly useful for evaluating spinal osteomyelitis, lung infections, and chronic infections, where In-111 WBC scans may be less sensitive.[2] However, its specificity is lower than that of the In-111 WBC scan due to its uptake in non-infectious inflammatory processes and tumors.[2] [4] Normal physiological uptake in the liver, spleen, bone, and bowel can also complicate image interpretation.[17]

Technetium-99m HMPAO-WBC Scan

The primary advantage of the Tc-99m HMPAO-WBC scan is the ability to perform imaging much sooner after injection, providing faster results.[21] The lower radiation dose and superior image quality compared to In-111 are also significant benefits.[1][20] However, its utility in abdominal and pelvic imaging is limited by normal physiological excretion into the gastrointestinal and urinary tracts, which can lead to false-positive results.[1][10]

FDG-PET/CT

FDG-PET/CT has emerged as a powerful tool for imaging infection and inflammation due to its high sensitivity and excellent spatial resolution.[1][22] It has shown superior diagnostic accuracy in certain conditions, such as prosthetic joint infections and vasculitis.[1][12] The ability to provide both metabolic and anatomical information in a single scan is a major advantage. However, FDG uptake is not specific to infection and can be seen in sterile inflammation, post-surgical changes, and tumors, potentially leading to lower specificity compared to WBC scans in some scenarios.[12]

Conclusion

The **Indium-111** WBC scan remains a valuable and highly specific tool for the diagnosis of occult infections, particularly in the abdomen, pelvis, and in cases of prosthetic joint and diabetic foot infections. However, the choice of imaging modality should be tailored to the specific clinical scenario. For rapid diagnosis of acute infections, a Tc-99m HMPAO-WBC scan may be preferred. In cases of suspected spinal or chronic infections, a Gallium-67 scan might

be more appropriate. For superior sensitivity and anatomical localization, particularly in prosthetic joint infections and vasculitis, FDG-PET/CT is increasingly becoming the modality of choice. Understanding the strengths and limitations of each technique, as outlined in this guide, is essential for accurate diagnosis and effective patient management in both clinical and research settings.

Need Custom Synthesis?

BenchChem offers custom synthesis for rare earth carbides and specific isotopic labeling.

Email: info@benchchem.com or [Request Quote Online](#).

References

- 1. Indium-111 White Blood Cell Scan - StatPearls - NCBI Bookshelf [ncbi.nlm.nih.gov]
- 2. Indium-111 WBC scan - Wikipedia [en.wikipedia.org]
- 3. Diagnostic sensitivity and specificity of the radionuclide (indium)-labeled leukocyte scan - PubMed [pubmed.ncbi.nlm.nih.gov]
- 4. auntminnie.com [auntminnie.com]
- 5. researchgate.net [researchgate.net]
- 6. Prospective study of bone, indium-111-labeled white blood cell, and gallium-67 scanning for the evaluation of osteomyelitis in the diabetic foot - PubMed [pubmed.ncbi.nlm.nih.gov]
- 7. droracle.ai [droracle.ai]
- 8. Comparisons of scintigraphy with In-111 leukocytes and Ga-67 in the diagnosis of occult sepsis - PubMed [pubmed.ncbi.nlm.nih.gov]
- 9. Subacute and chronic bone infections: diagnosis using In-111, Ga-67 and Tc-99m MDP bone scintigraphy, and radiography - PubMed [pubmed.ncbi.nlm.nih.gov]
- 10. Comparison of technetium-99m-HM-PAO leukocytes with indium-111-oxine leukocytes for localizing intraabdominal sepsis - PubMed [pubmed.ncbi.nlm.nih.gov]
- 11. EANM/SNMMI guideline/procedure standard for [18F]FDG hybrid PET use in infection and inflammation in adults v2.0 - PMC [pmc.ncbi.nlm.nih.gov]
- 12. FDG-PET/CT in infections: the imaging method of choice? - PMC [pmc.ncbi.nlm.nih.gov]
- 13. Guidelines for the labelling of leucocytes with 111In-oxine - PMC [pmc.ncbi.nlm.nih.gov]

- 14. radiopaedia.org [radiopaedia.org]
- 15. apps.ausrad.com [apps.ausrad.com]
- 16. radiopaedia.org [radiopaedia.org]
- 17. Scintigraphic Diagnosis of Inflammation and Infection | Radiology Key [radiologykey.com]
- 18. nuclearmed.org [nuclearmed.org]
- 19. medfordradiology.com [medfordradiology.com]
- 20. radiopaedia.org [radiopaedia.org]
- 21. academic.oup.com [academic.oup.com]
- 22. jnm.snmjournals.org [jnm.snmjournals.org]
- To cite this document: BenchChem. [Evaluating the Diagnostic Accuracy of Indium-111 WBC Scan: A Comparative Guide]. BenchChem, [2025]. [Online PDF]. Available at: [https://www.benchchem.com/product/b102479#evaluating-the-diagnostic-accuracy-of-indium-111-wbc-scan]

Disclaimer & Data Validity:

The information provided in this document is for Research Use Only (RUO) and is strictly not intended for diagnostic or therapeutic procedures. While BenchChem strives to provide accurate protocols, we make no warranties, express or implied, regarding the fitness of this product for every specific experimental setup.

Technical Support: The protocols provided are for reference purposes. Unsure if this reagent suits your experiment? [[Contact our Ph.D. Support Team for a compatibility check](#)]

Need Industrial/Bulk Grade? [Request Custom Synthesis Quote](#)

BenchChem

Our mission is to be the trusted global source of essential and advanced chemicals, empowering scientists and researchers to drive progress in science and industry.

Contact

Address: 3281 E Guasti Rd

Ontario, CA 91761, United States

Phone: (601) 213-4426

Email: info@benchchem.com

