

Enhancing patient comfort and recovery after a vitreous tap procedure.

Author: BenchChem Technical Support Team. **Date:** December 2025

Compound of Interest

Compound Name: CP-67015

Cat. No.: B1669555

[Get Quote](#)

Technical Support Center: Post-Vitreous Tap Patient Management

This guide provides researchers, scientists, and drug development professionals with essential information for enhancing patient comfort and managing recovery following a vitreous tap procedure.

Frequently Asked Questions (FAQs)

Q1: What are the most common patient-reported symptoms immediately following a vitreous tap?

A: Immediately after a vitreous tap, patients most commonly report mild to moderate eye discomfort, a gritty or foreign body sensation, and slightly blurred vision.^{[1][2][3]} The eyelid may be swollen or bruised, which typically resolves within a few days.^[4] While significant pain is uncommon, a slight ache is a frequent symptom.^[1]

Q2: What is the expected recovery timeline for a patient after a vitreous tap?

A: A vitreous tap is less invasive than a full vitrectomy, so recovery is generally quicker. Mild discomfort and irritation usually subside within 24-48 hours.^{[3][4]} Blurred vision may persist for a few days as the eye's internal environment stabilizes.^[5] Most patients can resume light activities and desk work within one to two days, with a return to all normal activities expected within a week, provided no complications arise.^{[6][7]}

Q3: How can patient comfort and pain be quantitatively assessed in a clinical research setting?

A: Patient comfort and pain can be quantified using a standardized Visual Analog Scale (VAS). A prospective study on vitreoretinal surgery utilized a VAS to have patients rate their eye pain, nausea, and sedation at 2 and 5 hours post-surgery.[8] Another study on 20-gauge vitrectomy used a pain scoring system where patients rated their pain from 0 (no pain) to 10 (unbearable pain), with scores of 1-3 considered mild, 4-6 moderate, and 7-10 severe.[9] These scales provide reproducible data for analysis.

Q4: What are the critical signs that differentiate sterile post-procedural inflammation from infectious endophthalmitis?

A: Differentiating sterile inflammation from infectious endophthalmitis is critical. Infectious endophthalmitis typically presents with more severe and worsening pain, significant decrease in visual acuity, and profound anterior chamber and vitreous inflammation.[10] Sterile inflammation is often less severe and may show improvement with topical corticosteroids.[11] [12] The onset of symptoms for infectious endophthalmitis is often between 1 and 6 days post-procedure, whereas sterile inflammation can appear more acutely, sometimes within 12 to 48 hours.[10][12] A definitive diagnosis requires a vitreous tap for culture and analysis.[12]

Troubleshooting Guides

Issue: Persistent or Worsening Ocular Pain

If a patient reports pain that is severe or worsening after the first 24 hours, it is a critical indicator that requires immediate investigation.

- **Assess Pain Level:** Quantify the pain using a standardized pain scale.
- **Examine the Eye:** Look for signs of increased inflammation, such as significant redness, corneal edema, or hypopyon (a layer of white blood cells in the anterior chamber).[12][13]
- **Measure Intraocular Pressure (IOP):** Elevated IOP can be a source of significant pain and can be caused by inflammation or retained viscoelastic material from other procedures.[13] [14]

- Consider Endophthalmitis: Worsening pain is a key symptom of infectious endophthalmitis. [10] A follow-up vitreous tap for culture may be warranted if there is a high degree of suspicion.[12]

Issue: Unexpected Decrease in Visual Acuity

A significant drop in vision beyond mild blurriness is abnormal and requires troubleshooting.

- Rule out Media Opacities: Assess for vitreous hemorrhage or severe inflammation that could be obscuring the visual axis.[13] An ultrasound B-scan can be used if the view of the retina is poor.[12]
- Evaluate for Retinal Complications: Although rare for a simple vitreous tap, iatrogenic retinal breaks or detachment can occur, especially if there was pre-existing retinal pathology.[15]
- Check for Corneal Edema: Significant inflammation can lead to corneal edema, which can degrade vision.[13][16] This is often associated with elevated IOP.

Data Presentation

Table 1: Post-Operative Pain Assessment after Vitreoretinal Surgery

Time Point	Percentage of Patients Reporting Pain	Average Pain Score (0-10 Scale)	Percentage Requiring Analgesia	Notes
2-5 Hours	56%	Not specified	48% (27% required narcotics)	Data from a study on 185 patients after various vitreoretinal surgeries.[8]
Day 1	49.4%	1.30 (SD: 1.60)	4.6% (4 of 87 patients)	Data from a study on 87 patients after 20-gauge vitrectomy.[9]
Day 3	44.8%	1.03 (SD: 1.38)	2.3% (2 of 87 patients)	Pain was generally mild and well-tolerated by most patients.[9]
Day 7	35.6%	0.62 (SD: 1.03)	0%	Pain scores progressively decreased over the first week.[9]

Note: Data is derived from vitrectomy procedures, which are more invasive than a vitreous tap. Pain levels after a vitreous tap are expected to be on the lower end of these ranges.

Experimental Protocols

Protocol 1: Assessment of Ocular Pain using a Visual Analog Scale (VAS)

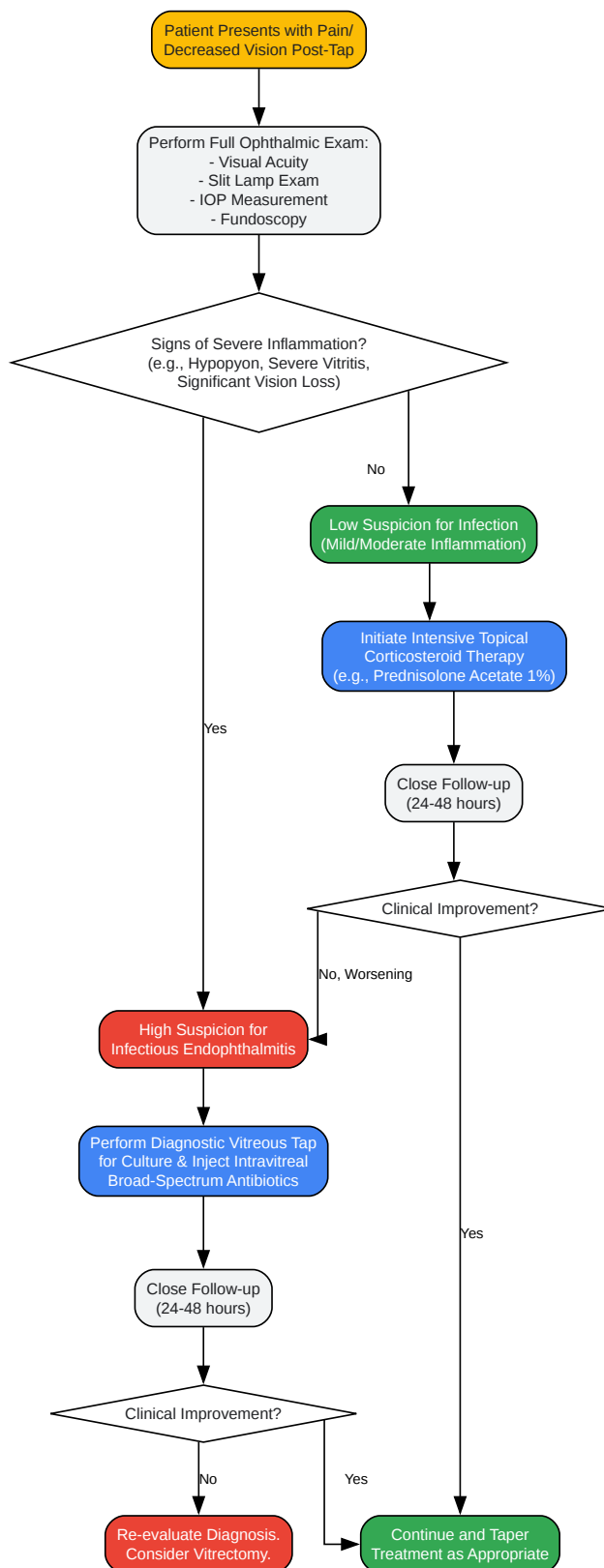
- Objective: To quantitatively measure a patient's subjective pain level.
- Methodology:

- Provide the patient with a 10 cm line, anchored at one end with "No Pain" and at the other with "Worst Imaginable Pain."
- Instruct the patient to mark a point on the line that corresponds to their current level of pain.
- Measure the distance in millimeters from the "No Pain" anchor to the patient's mark. This value (0-100) is the pain score.
- Perform this assessment at baseline (pre-procedure) and at set intervals post-procedure (e.g., 2 hours, 24 hours, 3 days, 1 week).

Protocol 2: Clinical Grading of Anterior Chamber Inflammation

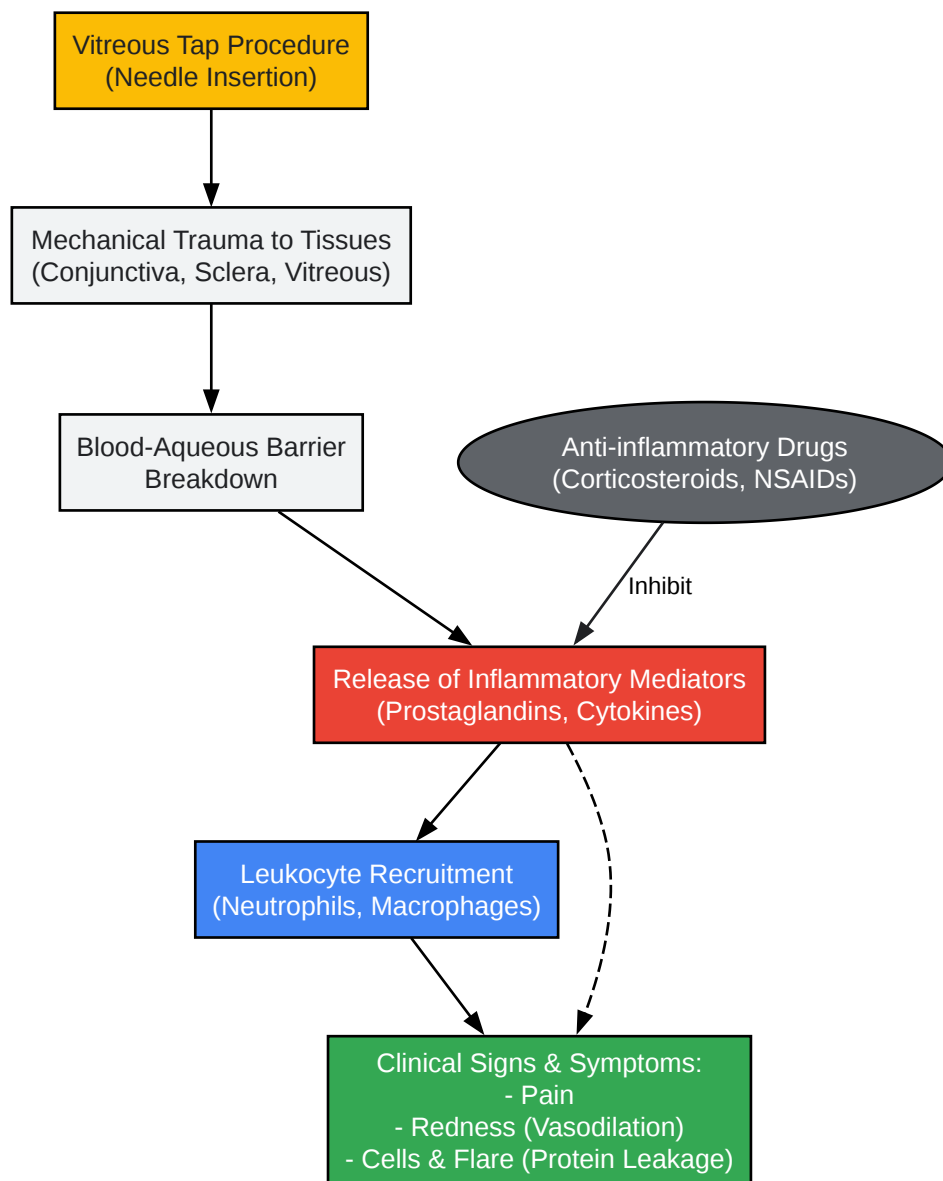
- Objective: To semi-quantitatively assess the level of intraocular inflammation.
- Methodology (based on the Standardization of Uveitis Nomenclature - SUN - working group):
 - Using a slit-lamp biomicroscope with a high-magnification, 1x1 mm beam of light, count the number of cells in the anterior chamber.
 - Grade 0: <1 cell
 - Grade 0.5+: 1-5 cells
 - Grade 1+: 6-15 cells
 - Grade 2+: 16-25 cells
 - Grade 3+: 26-50 cells
 - Grade 4+: >50 cells
 - Assess for aqueous flare (protein leakage) and grade from 0 (none) to 4+ (intense, with fibrin).
 - Record these grades at each follow-up visit to track the inflammatory response.

Visualizations



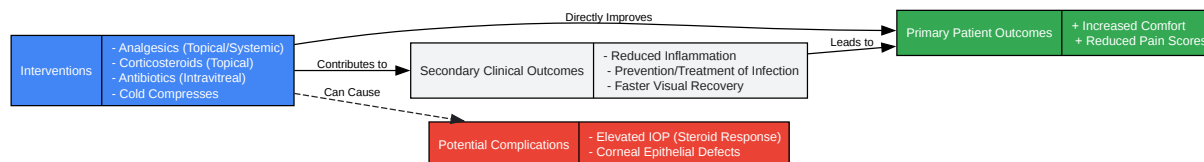
[Click to download full resolution via product page](#)

Caption: Workflow for differentiating infectious vs. sterile inflammation.



[Click to download full resolution via product page](#)

Caption: Simplified signaling pathway of post-procedural inflammation.



[Click to download full resolution via product page](#)

Caption: Logical relationship between interventions and patient outcomes.

Need Custom Synthesis?

BenchChem offers custom synthesis for rare earth carbides and specific isotopic labeling.

Email: info@benchchem.com or [Request Quote Online](#).

References

- 1. retinadoctor.com.au [retinadoctor.com.au]
- 2. Recovery After Vitrectomy: An Overview [pristyncare.com]
- 3. m.youtube.com [m.youtube.com]
- 4. Health Library - Tan Tock Seng Hospital [ttsh.com.sg]
- 5. Vitrectomy: What to Expect at Home [myhealth.alberta.ca]
- 6. You are being redirected... [rvaf.com]
- 7. You are being redirected... [rvaf.com]
- 8. Eye pain after vitreoretinal surgery: a prospective study of 185 patients - PubMed [pubmed.ncbi.nlm.nih.gov]
- 9. A prospective study on postoperative discomfort after 20-gauge pars plana vitrectomy - PMC [pmc.ncbi.nlm.nih.gov]
- 10. aao.org [aao.org]
- 11. Vitreous Inflammation Associated with Intravitreal Anti-VEGF Pharmacotherapy - PMC [pmc.ncbi.nlm.nih.gov]

- 12. reviewofophthalmology.com [reviewofophthalmology.com]
- 13. Complications - VBS Academy [vba.vitbucklesociety.org]
- 14. crstoday.com [crstoday.com]
- 15. retinafoundation.com [retinafoundation.com]
- 16. Complications in Retinal Surgery: A review of Corneal Changes following Vitreoretinal Procedures - PMC [pmc.ncbi.nlm.nih.gov]
- To cite this document: BenchChem. [Enhancing patient comfort and recovery after a vitreous tap procedure.]. BenchChem, [2025]. [Online PDF]. Available at: [https://www.benchchem.com/product/b1669555#enhancing-patient-comfort-and-recovery-after-a-vitreous-tap-procedure]

Disclaimer & Data Validity:

The information provided in this document is for Research Use Only (RUO) and is strictly not intended for diagnostic or therapeutic procedures. While BenchChem strives to provide accurate protocols, we make no warranties, express or implied, regarding the fitness of this product for every specific experimental setup.

Technical Support: The protocols provided are for reference purposes. Unsure if this reagent suits your experiment? [[Contact our Ph.D. Support Team for a compatibility check](#)]

Need Industrial/Bulk Grade? [Request Custom Synthesis Quote](#)

BenchChem

Our mission is to be the trusted global source of essential and advanced chemicals, empowering scientists and researchers to drive progress in science and industry.

Contact

Address: 3281 E Guasti Rd
Ontario, CA 91761, United States
Phone: (601) 213-4426
Email: info@benchchem.com