

Endovaginal Ultrasound in the Initial Investigation of Female Infertility: A Technical Guide

Author: BenchChem Technical Support Team. **Date:** December 2025

Compound of Interest

Compound Name: FR 76830

Cat. No.: B1674034

[Get Quote](#)

Introduction

The initial investigation of female infertility requires a meticulous and systematic evaluation of the reproductive organs. Endovaginal ultrasound, also known as transvaginal ultrasound (TVS), has become an indispensable, first-line imaging modality in this process.^{[1][2]} Its ability to provide high-resolution images of the pelvic organs makes it a powerful, non-invasive, and cost-effective tool for assessing uterine, ovarian, and tubal factors contributing to infertility.^{[2][3]} Unlike transabdominal ultrasound, the transvaginal approach places the high-frequency transducer in close proximity to the uterus and ovaries, enabling detailed visualization of their morphology and function.^{[2][4]} This technical guide provides an in-depth overview of the core endovaginal ultrasound methodologies used in the initial workup of female infertility, tailored for researchers, scientists, and drug development professionals.

Core Methodologies and Experimental Protocols

A comprehensive infertility investigation utilizes several specialized endovaginal ultrasound techniques. The initial scan provides a baseline assessment of the pelvic anatomy, after which more specific protocols may be employed.^[5]

Standard 2D Endovaginal Ultrasound: Baseline Assessment

The standard 2D ultrasound is the foundational examination in the infertility workup. It systematically evaluates the uterus, endometrium, ovaries, and adnexa.[5]

Experimental Protocol:

- Patient Preparation: The examination is performed with an empty bladder to optimize visualization.[2]
- Timing: For general assessment, the timing is flexible. However, for specific evaluations like antral follicle count, the early follicular phase (days 2-4 of the menstrual cycle) is optimal.[6]
- Procedure:
 - A high-frequency (≥ 7 MHz) transvaginal ultrasound transducer is covered with a sterile probe cover and lubricating gel.[2][7]
 - The probe is inserted into the vagina to obtain clear images of the pelvic organs.[4]
 - Uterine Assessment: The uterus is evaluated in both sagittal and transverse planes to measure its dimensions (length, width, anteroposterior diameter) and assess the myometrium for abnormalities such as fibroids or adenomyosis.[5][8]
 - Endometrial Assessment: The endometrial thickness is measured from the outer edge to the outer edge in the midsagittal plane.[5][9] Its pattern (e.g., trilaminar or echogenic) is documented, as this changes throughout the menstrual cycle.[10]
 - Ovarian Assessment: Both ovaries are identified and their volume is calculated. The presence of any cysts or masses is noted.[5]
 - Adnexal and Cul-de-sac Evaluation: The adnexa are examined for abnormalities like hydrosalpinges (fluid-filled fallopian tubes), and the cul-de-sac is checked for free fluid.[2][5]

Antral Follicle Count (AFC) for Ovarian Reserve Assessment

The Antral Follicle Count (AFC) is a key sonographic marker for estimating ovarian reserve, which reflects the quantity of the remaining egg pool.[6][11] It is a strong predictor of ovarian response to gonadotropin stimulation in assisted reproductive technology (ART).[6][12]

Experimental Protocol:

- Patient Preparation: No special preparation is required beyond an empty bladder.
- Timing: The AFC is best performed in the early follicular phase of the menstrual cycle (days 2-4).[6]
- Procedure:
 - Using a high-frequency transvaginal transducer (≥ 7 MHz), each ovary is systematically scanned from the outer to the inner margin.[7]
 - All antral follicles measuring 2-10 mm in diameter in both ovaries are counted.[13]
 - The count can be performed using real-time 2D ultrasound, stored 2D cine-loops, or 3D datasets.[13] While real-time scanning allows for maneuvers to differentiate follicles from other structures, 3D techniques can reduce scanning time and inter-observer variability.[7][13]
 - The total AFC is the sum of the follicles in both ovaries.

Saline Infusion Sonohysterography (SIS) for Uterine Cavity Evaluation

SIS, or sonohysterography, is a specialized procedure that enhances the visualization of the endometrial cavity.[14] By introducing sterile saline, it can delineate subtle intrauterine pathologies like polyps, submucosal fibroids, adhesions, or congenital anomalies that might be missed on a standard ultrasound.[15][16][17]

Experimental Protocol:

- Patient Preparation: The procedure should not be performed if pregnancy or active pelvic infection is suspected.[18] Some practitioners may recommend a pre-procedure analgesic

like ibuprofen.[18]

- Timing: SIS is typically performed in the early follicular phase, after menstruation has ceased (usually days 5-9), to ensure a thin endometrium and avoid disrupting a potential pregnancy. [14][15]
- Procedure:
 - A baseline transvaginal ultrasound is performed.
 - A speculum is placed in the vagina, and the cervix is cleansed with an antiseptic solution. [15]
 - A thin, flexible catheter is inserted through the cervix into the uterine cavity.[17]
 - The speculum is removed, and the transvaginal ultrasound probe is reinserted.
 - Sterile saline is slowly infused through the catheter while real-time ultrasound imaging is performed.[17] The saline distends the uterine cavity, outlining any intracavitary lesions. [16]
 - The entire procedure typically takes less than 30 minutes.[14][16]

Doppler Ultrasonography for Receptivity Assessment

Color and pulsed Doppler ultrasound are used to non-invasively assess blood flow to the uterus and endometrium, which is considered essential for successful embryo implantation.[19] [20]

Experimental Protocol:

- Patient Preparation: Standard preparation for a transvaginal ultrasound.
- Timing: This assessment is often performed on the day of hCG administration or embryo transfer in ART cycles.
- Procedure:

- A transvaginal ultrasound probe with Doppler capabilities is used.
- Uterine Artery Doppler: The uterine arteries are identified at the level of the internal cervical os. The Pulsatility Index (PI) and Resistance Index (RI) are measured. Lower impedance (lower PI/RI) is generally associated with better endometrial receptivity.[20][21]
- Endometrial/Subendometrial Blood Flow: The color Doppler gate is placed over the endometrium and subendometrial region to visualize vascularity.[5] Flow can be qualitatively graded or quantitatively assessed using 3D power Doppler to calculate vascularization indices (VI, FI, VFI).[21] The presence of multifocal blood flow within the endometrium is considered a favorable sign.[10][22]

3D Ultrasonography for Uterine Anomalies

Three-dimensional (3D) ultrasound provides a detailed assessment of uterine morphology and is superior to 2D ultrasound for diagnosing and classifying congenital Müllerian duct anomalies (MDAs).[23] The key advantage is its ability to generate a coronal view of the uterus, which is crucial for differentiating between anomalies like septate and bicornuate uteri.[23][24]

Experimental Protocol:

- Patient Preparation: Standard preparation for a transvaginal ultrasound.
- Timing: Can be performed at any time, but the mid-luteal phase is often preferred due to the thicker, more distinct endometrium.
- Procedure:
 - A standard 2D transvaginal scan is performed first to assess the uterine position.[25]
 - A 3D volume acquisition is performed in the sagittal plane of the uterus, ensuring the entire uterus from the fundus to the cervix is included in the volume box.[26]
 - The acquired volume is then manipulated using multiplanar reconstruction software to obtain a true coronal view.
 - This view allows for precise assessment of both the external uterine fundal contour and the internal shape of the endometrial cavity, which is essential for classification according

to ESHRE/ESGE or ASRM guidelines.[\[25\]](#)[\[27\]](#)

Data Presentation: Quantitative Analysis

Summarizing quantitative data from ultrasound assessments is crucial for clinical decision-making and research.

Parameter	Technique	Measurement/Finding	Clinical Significance in Infertility	Reference(s)
Ovarian Reserve	2D/3D TVS	Antral Follicle Count (AFC)	Predicts ovarian response to stimulation. A low count may indicate diminished ovarian reserve.	[6]
Uterine Cavity	SIS	Presence/Absence of Polyps, Fibroids, Adhesions	Identifies structural issues that can impair implantation.	[15][16]
Uterine Anomalies	3D TVS	ESHRE/ESGE Classification (U0-U6)	Accurate diagnosis of congenital anomalies (e.g., septate uterus) that can cause recurrent pregnancy loss.	[27]
Interobserver Reproducibility (Kappa)	Uterine Classification (Overall): $k = 0.73$	[27]		
Interobserver Reproducibility (ICC)	Uterine Wall Thickness: ICC = 0.93 Cavity Indentation: ICC = 0.93	[27]		
Endometrial Receptivity	2D TVS	Endometrial Thickness	An adequate thickness (often cited as >7 mm)	[19][28]

is considered necessary for implantation, though this is debated.

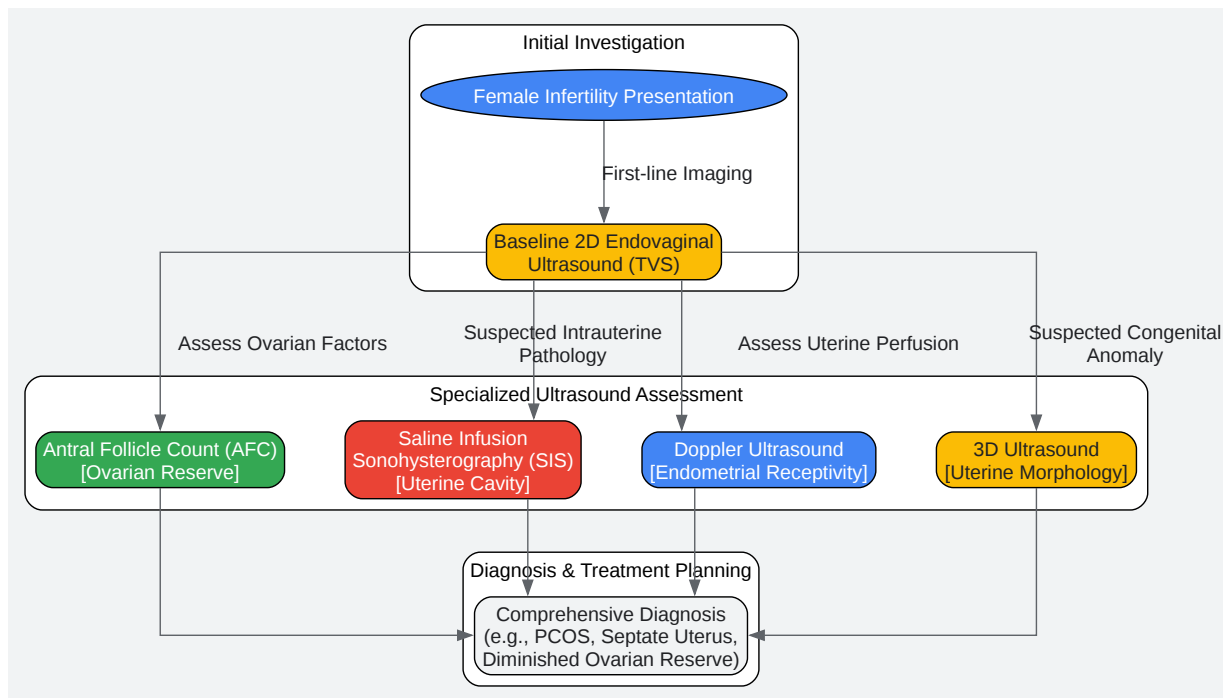
2D TVS	Endometrial Pattern	A trilaminar ("triple-line") pattern in the late follicular phase is associated with better receptivity.	[10][21]
Doppler US	Uterine Artery Pulsatility Index (PI)	High PI may indicate high impedance to blood flow, which is unfavorable for implantation.	[20][22]
Diagnostic Accuracy	TVS	Polycystic Ovary Syndrome (PCOS)	85% accuracy in identifying PCOS characteristics. [29]
3D TVS	Uterine Anomalies	92% accuracy in detecting uterine anomalies.	[29]

Signaling Pathways and Logical Relationships

Endovaginal ultrasound provides morphological and physiological data that reflects underlying molecular and cellular processes. The logical workflow of an investigation and the signaling pathways influencing endometrial receptivity can be visualized.

Logical Workflow Diagram

The following diagram illustrates the central role of endovaginal ultrasound in the initial infertility workup, branching into specialized investigations based on initial findings.

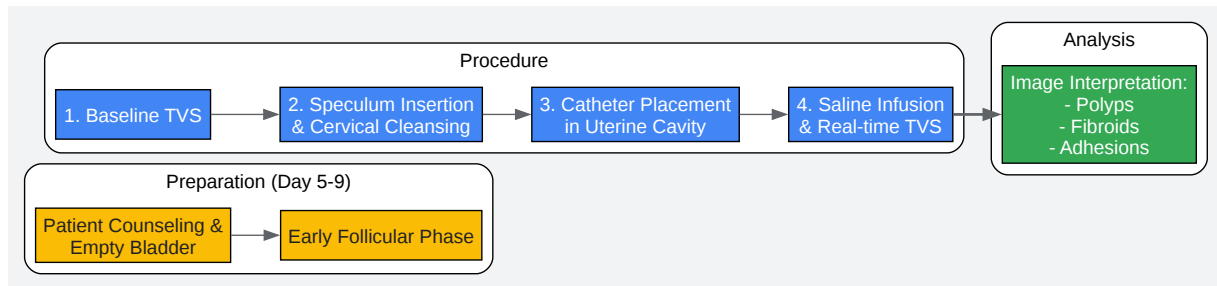


[Click to download full resolution via product page](#)

Initial infertility investigation workflow using ultrasound.

Experimental Workflow: Saline Infusion Sonohysterography (SIS)

This diagram details the sequential steps involved in performing an SIS procedure.

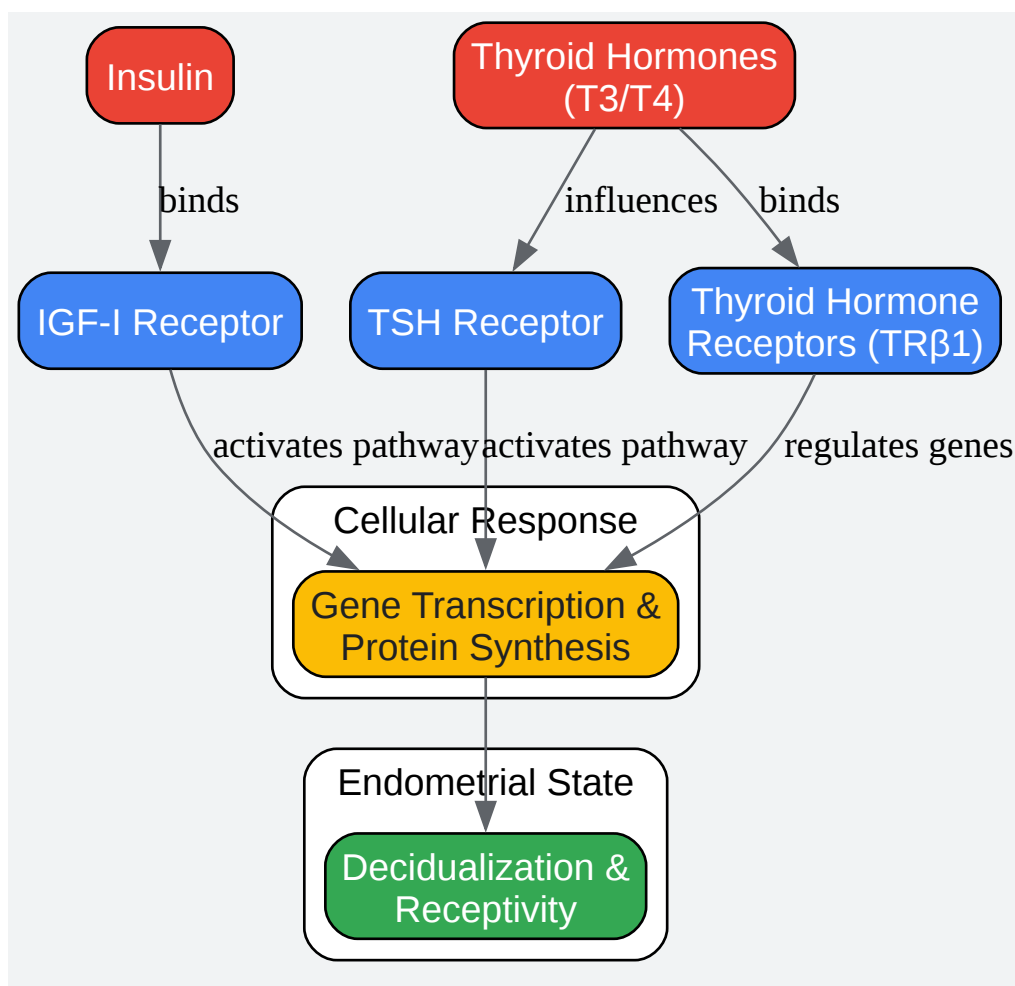


[Click to download full resolution via product page](#)

Step-by-step workflow for the SIS procedure.

Signaling Pathways in Endometrial Development

Ovarian stimulation during ART can alter hormonal levels, impacting endometrial signaling pathways crucial for receptivity. Research indicates that insulin and thyroid hormone signaling pathways may be affected.[30] This diagram conceptualizes these influences.



[Click to download full resolution via product page](#)

Need Custom Synthesis?

BenchChem offers custom synthesis for rare earth carbides and specific isotopic labeling.

Email: info@benchchem.com or [Request Quote Online](#).

References

- 1. researchgate.net [researchgate.net]
- 2. Transvaginal ultrasonography and female infertility | GLOWM [glowm.com]
- 3. mjcu.journals.ekb.eg [mjcu.journals.ekb.eg]
- 4. Sonography Transvaginal Assessment, Protocols, and Interpretation - StatPearls - NCBI Bookshelf [ncbi.nlm.nih.gov]

- 5. Sonography Gynecology Infertility Assessment, Protocols, and Interpretation - StatPearls - NCBI Bookshelf [ncbi.nlm.nih.gov]
- 6. Ultrasound assessment of antral follicle count (Chapter 28) - Ultrasonography in Gynecology [cambridge.org]
- 7. portal.research.lu.se [portal.research.lu.se]
- 8. aium.org [aium.org]
- 9. dsjuog.com [dsjuog.com]
- 10. m.youtube.com [m.youtube.com]
- 11. Role of Transvaginal Sonography in the Diagnosis of Female Infertility: A Comprehensive Review - PMC [pmc.ncbi.nlm.nih.gov]
- 12. researchgate.net [researchgate.net]
- 13. researchgate.net [researchgate.net]
- 14. Saline Infusion Sonohysterography (SIS) - InsideRadiology [insideradiology.com.au]
- 15. Saline Infusion Sonohysterogram (SIS) Overview | FIH [ivfcenterhawaii.com]
- 16. Saline Infusion Sonohysterogram (SIS) - Fertility Evaluation in Houston [inovifertility.com]
- 17. veritasfertility.com [veritasfertility.com]
- 18. Saline infusion sonohysterogram (SHG) patient education fact sheet | ReproductiveFacts.org [reproductivefacts.org]
- 19. dsjuog.com [dsjuog.com]
- 20. scispace.com [scispace.com]
- 21. droracle.ai [droracle.ai]
- 22. Ultrasonography and Doppler Study to Predict Uterine Receptivity in Infertile Patients Undergoing Embryo Transfer - PMC [pmc.ncbi.nlm.nih.gov]
- 23. Application of 3D Ultrasonography in Detection of Uterine Abnormalities - PMC [pmc.ncbi.nlm.nih.gov]
- 24. researchgate.net [researchgate.net]
- 25. volusonclub.net [volusonclub.net]
- 26. ijrcog.org [ijrcog.org]
- 27. Classification of Uterine Anomalies by 3-Dimensional Ultrasonography Using ESHRE/ESGE Criteria: Interobserver Variability - PubMed [pubmed.ncbi.nlm.nih.gov]
- 28. dsjuog.com [dsjuog.com]

- 29. msjonline.org [msjonline.org]
- 30. Endometrial signaling pathways during ovarian stimulation for assisted reproduction technology - PubMed [pubmed.ncbi.nlm.nih.gov]
- To cite this document: BenchChem. [Endovaginal Ultrasound in the Initial Investigation of Female Infertility: A Technical Guide]. BenchChem, [2025]. [Online PDF]. Available at: [https://www.benchchem.com/product/b1674034#endovaginal-ultrasound-in-the-initial-investigation-of-female-infertility]

Disclaimer & Data Validity:

The information provided in this document is for Research Use Only (RUO) and is strictly not intended for diagnostic or therapeutic procedures. While BenchChem strives to provide accurate protocols, we make no warranties, express or implied, regarding the fitness of this product for every specific experimental setup.

Technical Support: The protocols provided are for reference purposes. Unsure if this reagent suits your experiment? [[Contact our Ph.D. Support Team for a compatibility check](#)]

Need Industrial/Bulk Grade? [Request Custom Synthesis Quote](#)

BenchChem

Our mission is to be the trusted global source of essential and advanced chemicals, empowering scientists and researchers to drive progress in science and industry.

Contact

Address: 3281 E Guasti Rd

Ontario, CA 91761, United States

Phone: (601) 213-4426

Email: info@benchchem.com