

Early Studies on Oxyphenisatin Acetate Hepatotoxicity: A Technical Guide

Author: BenchChem Technical Support Team. **Date:** December 2025

Compound of Interest

Compound Name: Oxyphenisatin Acetate

Cat. No.: B1678119

[Get Quote](#)

For Researchers, Scientists, and Drug Development Professionals

Introduction

Oxyphenisatin acetate was a widely used laxative in the mid-20th century. However, numerous reports emerged in the late 1960s and early 1970s linking the drug to severe liver toxicity, often presenting as acute hepatitis or a more insidious chronic active hepatitis.^[1] This led to its eventual withdrawal from the market in many countries. This technical guide provides an in-depth review of the early clinical studies that characterized the hepatotoxicity of **oxyphenisatin acetate**, with a focus on the clinical data, diagnostic methods of the era, and the pathological findings. Due to the withdrawal of the drug, extensive mechanistic studies are lacking; therefore, this guide focuses on the critical clinical evidence that led to its discontinuation.

Clinical and Pathological Features of Oxyphenisatin Acetate-Induced Hepatotoxicity

The predominant form of liver injury reported with **oxyphenisatin acetate** was chronic active hepatitis, a condition characterized by ongoing liver inflammation that can lead to cirrhosis.^[1] ^[2] An acute hepatitis-like presentation also occurred.^[1] The onset of symptoms was often insidious, developing after one to two years of daily ingestion of laxatives containing the compound.

Key Clinical Manifestations:

- Jaundice: A common presenting sign.
- Fatigue and Malaise: Non-specific symptoms that often preceded jaundice.
- Hepatomegaly: Enlargement of the liver was a frequent finding on physical examination.
- Splenomegaly and Spider Angiomas: These were occasionally observed, suggesting progression to more chronic liver disease.

Biochemical Findings:

The biochemical abnormalities reflected hepatocellular damage. Key findings from early case series are summarized in the tables below.

Table 1: Summary of Patient Characteristics and Dosage from Early Studies

Study (Year)	Number of Patients	Age Range (years)	Gender (Female:Male)	Daily Dosage of Oxyphenisatin Acetate	Duration of Ingestion
Reynolds et al. (1971)	6	Not specified	Not specified	Not specified	1 to 2 years
Willing and Hecker (1971)	Not specified	Adult, Aged	Predominantly Female	Not specified	Not specified
Cooksley et al. (1973)	29 (prospective)	Adult, Aged	Not specified	Not specified	Not specified
Gjone et al. (1972)	5	Not specified	Not specified	Not specified	> 6 months

Specific dosage information was often not detailed in the initial reports, as many patients were taking proprietary laxative mixtures.

Table 2: Summary of Biochemical Findings in Patients with **Oxyphenisatin Acetate**-Induced Hepatotoxicity

Study (Year)	Serum Transaminases (SGOT/AST, SGPT/ALT)	Serum Alkaline Phosphatase (ALP)	Serum Bilirubin	Serum Globulins	Autoantibodies
Reynolds et al. (1971)	Increased 10 to 40 times the upper limit of normal	Not consistently elevated	Elevated	Raised	Positive LE-cell test, antinuclear antibody, and smooth-muscle antibody present in some patients.
Willing and Hecker (1971)	Elevated	Elevated	Elevated	Not specified	Not specified
Cooksley et al. (1973)	Elevated Aspartate Aminotransferase (AST)	Not specified	Elevated	Not specified	Not specified
Gjone et al. (1972)	Increased (SGOT, SGPT)	Not specified	Increased	Increased	LE-factor positive, ANF positive, and SMA positive in some patients.

Histopathological Findings:

Liver biopsies were a crucial diagnostic tool in these early studies. The histological picture was often indistinguishable from other forms of chronic active hepatitis. Key features included:

- **Piecemeal Necrosis:** Destruction of liver cells at the interface between the portal tracts and the liver lobules.
- **Portal Tract Infiltration:** The portal tracts were heavily infiltrated with inflammatory cells, predominantly lymphocytes and plasma cells.
- **Fibrosis and Cirrhosis:** In advanced cases, there was evidence of scarring (fibrosis) and the development of cirrhosis.
- **Hepatocellular Damage:** Ballooning degeneration and acidophilic bodies (a sign of apoptosis) were also described.

Clinical and Diagnostic Protocols of the Era

The investigation of patients with suspected **oxyphenisatin acetate** hepatotoxicity in the early 1970s relied on a combination of clinical assessment, biochemical tests, and liver histology.

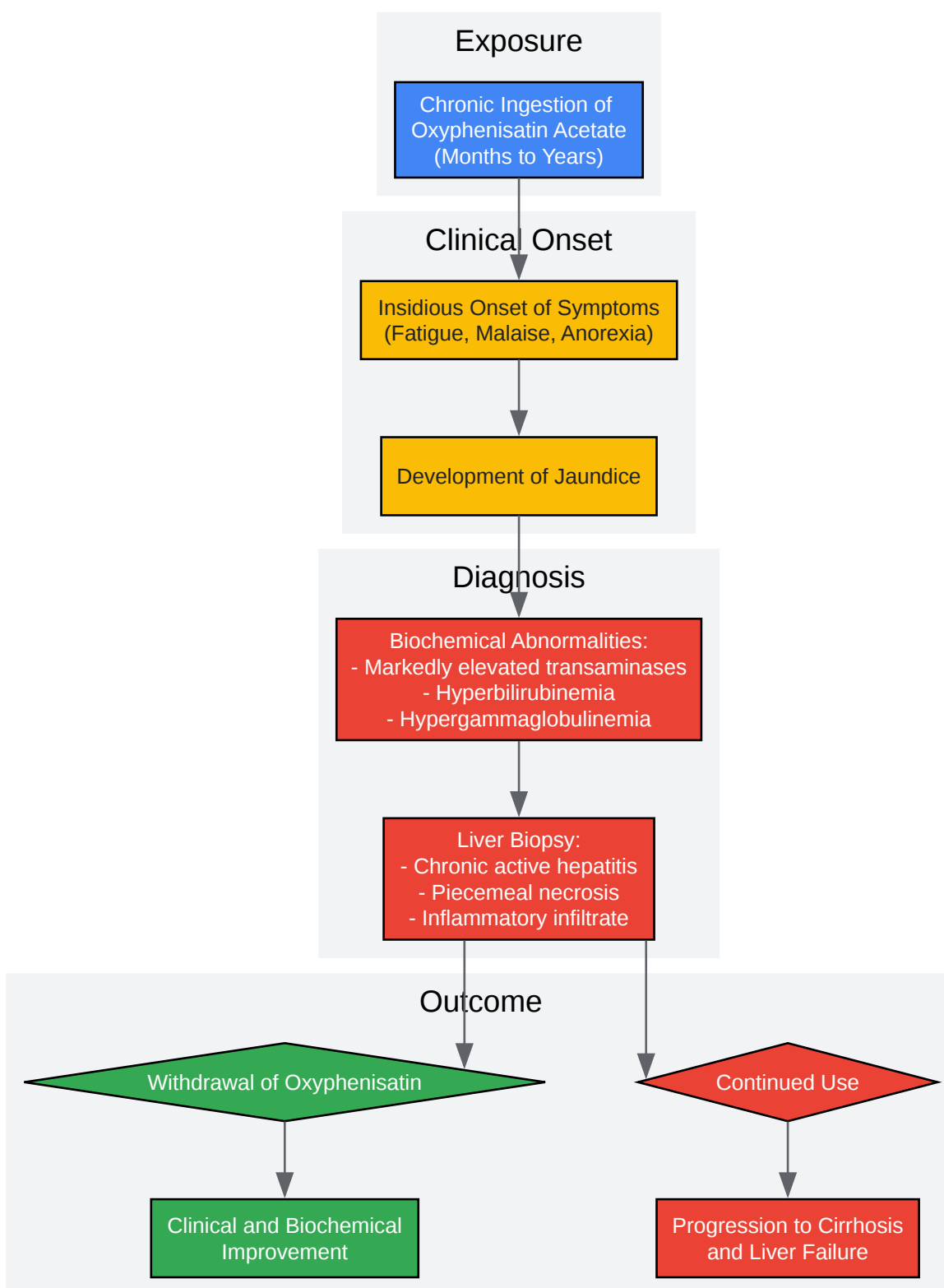
Experimental Protocols: Clinical Diagnostic and Monitoring Procedures

- **Biochemical Analysis:**
 - **Sample:** Serum was the primary sample used for biochemical tests.
 - **Liver Function Tests:** The panel of tests typically included:
 - **Serum Transaminases:** Serum glutamic-oxaloacetic transaminase (SGOT), now known as aspartate aminotransferase (AST), and serum glutamic-pyruvic transaminase (SGPT), now known as alanine aminotransferase (ALT), were the key markers of hepatocellular injury.
 - **Alkaline Phosphatase (ALP):** A marker of cholestasis.
 - **Serum Bilirubin:** To quantify the severity of jaundice.

- Serum Proteins: Total protein, albumin, and globulins were measured to assess the synthetic function of the liver and to detect hypergammaglobulinemia, a common feature of chronic active hepatitis.
- Autoantibody Testing: Tests for antinuclear antibodies (ANA), smooth muscle antibodies (SMA), and the LE cell phenomenon were performed to investigate an autoimmune component, as the clinical picture often resembled autoimmune hepatitis.
- Liver Biopsy and Histological Examination:
 - Procedure: A percutaneous liver biopsy was the standard method for obtaining liver tissue.
 - Tissue Processing: The biopsy specimens were fixed (commonly in formalin), embedded in paraffin, sectioned, and stained with a variety of histological stains.
 - Staining: Hematoxylin and eosin (H&E) was the primary stain for assessing the overall liver architecture and inflammatory infiltrate. Special stains for connective tissue (e.g., Masson's trichrome) were used to evaluate the degree of fibrosis.
 - Microscopic Examination: A pathologist would then examine the stained sections under a microscope to identify the characteristic features of chronic active hepatitis, as described above.
- Drug Challenge Studies:
 - In some cases, after a patient had recovered upon withdrawal of the drug, a "challenge" with oxyphenisatin was performed under close medical supervision.^[3] A subsequent sharp rise in serum transaminase levels was considered strong evidence of causality. This practice is now generally considered unethical.

Logical Progression of Oxyphenisatin Acetate Hepatotoxicity

The following diagram illustrates the typical clinical pathway of a patient with **oxyphenisatin acetate**-induced liver injury, based on the descriptions in the early case reports.



[Click to download full resolution via product page](#)

Caption: Clinical pathway of **Oxyphenisatin Acetate** hepatotoxicity.

Proposed Mechanisms of Toxicity

The exact mechanisms by which **oxyphenisatin acetate** causes liver injury have not been elucidated through experimental studies. However, the clinical features, particularly the presence of autoantibodies and a histological picture resembling autoimmune hepatitis in some cases, led early investigators to hypothesize that an immune-mediated mechanism was involved. The long latency period between starting the drug and the onset of liver disease is also consistent with an immunological reaction. It is possible that metabolites of **oxyphenisatin acetate** could act as haptens, binding to liver proteins and triggering an autoimmune response in susceptible individuals.

Conclusion

The early clinical studies from the 1970s were pivotal in identifying **oxyphenisatin acetate** as a significant cause of drug-induced liver injury, primarily in the form of chronic active hepatitis. The collective evidence from numerous case reports and a few prospective studies established a clear association between the long-term use of this laxative and severe, sometimes progressive, liver disease. While the precise molecular mechanisms of its hepatotoxicity remain undefined due to a lack of dedicated experimental research following its market withdrawal, the clinical data serves as a crucial historical example of idiosyncratic drug-induced liver injury. This technical guide, by summarizing the key clinical and pathological findings from this early literature, provides a valuable resource for understanding the hepatotoxic potential of this compound and serves as a reminder of the importance of post-marketing surveillance for adverse drug reactions.

Need Custom Synthesis?

BenchChem offers custom synthesis for rare earth carbides and specific isotopic labeling.

Email: info@benchchem.com or [Request Quote Online](#).

References

- 1. smj.sma.org.sg [smj.sma.org.sg]
- 2. Chronic active and lupoid hepatitis caused by a laxative, oxyphenisatin - PubMed [pubmed.ncbi.nlm.nih.gov]

- 3. Chronic Active and Lupoid Hepatitis Caused by a Laxative, Oxyphenisatin | Scilit [scilit.com]
- To cite this document: BenchChem. [Early Studies on Oxyphenisatin Acetate Hepatotoxicity: A Technical Guide]. BenchChem, [2025]. [Online PDF]. Available at: [https://www.benchchem.com/product/b1678119#early-studies-on-oxyphenisatin-acetate-hepatotoxicity]

Disclaimer & Data Validity:

The information provided in this document is for Research Use Only (RUO) and is strictly not intended for diagnostic or therapeutic procedures. While BenchChem strives to provide accurate protocols, we make no warranties, express or implied, regarding the fitness of this product for every specific experimental setup.

Technical Support: The protocols provided are for reference purposes. Unsure if this reagent suits your experiment? [[Contact our Ph.D. Support Team for a compatibility check](#)]

Need Industrial/Bulk Grade? [Request Custom Synthesis Quote](#)

BenchChem

Our mission is to be the trusted global source of essential and advanced chemicals, empowering scientists and researchers to drive progress in science and industry.

Contact

Address: 3281 E Guasti Rd
Ontario, CA 91761, United States
Phone: (601) 213-4426
Email: info@benchchem.com