

EOB-DTPA Enhanced MRI: A Cost-Effectiveness Analysis in Liver Imaging

Author: BenchChem Technical Support Team. **Date:** December 2025

Compound of Interest

Compound Name: *Eob-dtpa*

Cat. No.: *B3021170*

[Get Quote](#)

A comprehensive guide for researchers and drug development professionals on the economic and diagnostic value of Eovist®/Primovist® (gadoxetate disodium) in the detection and characterization of focal liver lesions.

Gadoxetic acid (Gd-**EOB-DTPA**), a hepatobiliary-specific MRI contrast agent, has demonstrated significant advantages in liver imaging. Its unique property of being taken up by hepatocytes allows for a combined dynamic and hepatobiliary phase examination, enhancing the detection and characterization of liver lesions. This guide provides an objective comparison of the cost-effectiveness of **EOB-DTPA** enhanced MRI against other imaging modalities, supported by experimental data and detailed methodologies.

Superior Diagnostic Accuracy Drives Cost-Effectiveness

Numerous studies have highlighted the superior diagnostic performance of **EOB-DTPA** MRI, which translates into its cost-effectiveness. The enhanced accuracy often reduces the need for further diagnostic procedures, leading to overall cost savings.

For the detection of colorectal liver metastases, **EOB-DTPA** MRI has shown higher diagnostic accuracy and sensitivity compared to contrast-enhanced PET/CT, particularly for lesions smaller than 1 cm.^[1] A meta-analysis of 13 studies confirmed a high sensitivity (93%) and specificity (95%) for detecting liver metastases.^[1] When compared with multidetector

computed tomography (MDCT), **EOB-DTPA** MRI detected 93% of metastases under 1 cm, while MDCT detected only 41.9% in patients who had received neoadjuvant chemotherapy.[1]

In the context of hepatocellular carcinoma (HCC), **EOB-DTPA** MRI provides higher diagnostic certainty, minimizing the need for additional confirmatory diagnostic procedures.[2] This is particularly true for lesions smaller than 20 mm, where the diagnostic accuracy is significantly improved compared to dynamic contrast-enhanced MRI (DCE-MRI) and contrast-enhanced CT (DCE-CT).[3]

Comparative Cost Analysis

While the initial cost of an **EOB-DTPA** enhanced MRI may be higher than other imaging modalities, its superior diagnostic accuracy often leads to downstream cost savings. This is primarily achieved by reducing the need for additional imaging and preventing unnecessary surgeries.

A study evaluating patients with suspected colorectal liver metastases in Germany, Italy, and Sweden found that an initial diagnostic strategy with **EOB-DTPA** MRI was cost-saving compared to extracellular contrast-media (ECA)-MRI and had similar or lower total costs compared to MDCT.[4][5] The need for further imaging was significantly lower after an initial **EOB-DTPA** MRI (8.6%) compared to ECA-MRI (18.5%) and MDCT (23.5%).[5] The VALUE study further supported these findings, showing that initial imaging with **EOB-DTPA** MRI resulted in cost savings compared to ECA-MRI and was less costly than CE-MDCT in most participating countries due to a reduced need for additional imaging.[6]

For suspected HCC, economic evaluations in South Korea and Thailand demonstrated that **EOB-DTPA** MRI as the initial imaging procedure resulted in cost savings for the payer compared to MDCT and ECA-MRI.[2] A similar study in China found that the total diagnosis and treatment cost per patient was lower with initial **EOB-DTPA** MRI compared to ECA-MRI and comparable to MDCT.[7]

The following tables summarize the quantitative data on cost-effectiveness and diagnostic accuracy from various studies.

Table 1: Cost-Effectiveness Comparison for Colorectal Liver Metastases

Country	Initial Imaging Modality	Total Cost per Patient (Diagnostic Workup, Intraoperative Changes, Unnecessary Surgery)	Need for Further Imaging	Rate of Unnecessary Surgery
Sweden	EOB-DTPA MRI	€959	8.6%	5.7%
ECA-MRI	€1,123	18.5%	8.6%	
MDCT	€1,044	23.5%	8.3%	
Italy & Germany	EOB-DTPA MRI	Cost-saving vs. ECA-MRI, similar cost to MDCT	8.6%	5.7%
ECA-MRI	-	18.5%	8.6%	
MDCT	-	23.5%	8.3%	

Data sourced from Zech et al. (2009) and related analyses.[\[4\]](#)[\[5\]](#)

Table 2: Cost-Effectiveness Comparison for Suspected Hepatocellular Carcinoma (HCC)

Country	Perspective	Initial Imaging Modality	Total Cost per Patient to Confirmed Treatment Decision
South Korea	Payer	EOB-DTPA MRI	USD \$3,087
MDCT	USD \$3,205		
ECA-MRI	USD \$3,403		
Hospital	EOB-DTPA MRI	USD \$2,289	
MDCT	USD \$2,320		
ECA-MRI	USD \$2,528		
Thailand	Payer	EOB-DTPA MRI	USD \$702
MDCT	USD \$931		
ECA-MRI	USD \$873		
Hospital	EOB-DTPA MRI	USD \$1,106	
MDCT	USD \$1,178		
ECA-MRI	USD \$1,087		
China	-	EOB-DTPA MRI	¥30,360
MDCT	¥30,803		
ECA-MRI	¥31,465		

Data sourced from studies by Lee et al. (2016) and He et al. (2018).[\[2\]](#)[\[7\]](#)

Table 3: Diagnostic Accuracy for Detection of Liver Lesions

Lesion Type	Comparison Modalities	Sensitivity	Specificity
Colorectal Metastases	EOB-DTPA MRI vs. CE-PET/CT	Significantly Higher	-
EOB-DTPA MRI vs. CE-CT & CE-US (<1 cm lesions)	Significantly Greater	No Significant Difference	
Hepatocellular Carcinoma (<20 mm)	EOB-DTPA MRI vs. DCE-MRI & DCE-CT	Significantly Improved	Significantly Improved
Hepatocellular Carcinoma (Post-TACE)	EOB-DTPA MRI vs. CECT	93.9% vs. 51.5%	100% vs. 60.0%

Data compiled from multiple sources.[\[1\]](#)[\[3\]](#)[\[8\]](#)

Quality-Adjusted Life Years (QALYs)

Cost-effectiveness is also measured in terms of Quality-Adjusted Life Years (QALYs), which considers both the quantity and quality of life gained from a healthcare intervention.[\[9\]](#) For early-stage HCC, a study in Korea reported higher QALYs for **EOB-DTPA** MRI (5.52) compared to MDCT (5.08).[\[10\]](#) Another analysis on detecting resectable colorectal liver metastases found that MRI (in general) was the dominant strategy, leading to overall costs of 40,863.65 and 8.50 QALYs, compared to CE – CT (40,863.65 and 8.50 QALYs, compared to CE – CT (42,874.02 and 8.47 QALYs) and PET/CT (\$43,216.74 and 8.48 QALYs).[\[11\]](#)[\[12\]](#)

Experimental Protocols

The cost-effectiveness and diagnostic accuracy of **EOB-DTPA** MRI are underpinned by specific imaging protocols. While protocols may vary slightly between institutions, a general methodology is as follows:

Patient Population: Patients with known or suspected focal liver lesions, such as hepatocellular carcinoma or liver metastases from colorectal cancer.

Imaging Procedure:

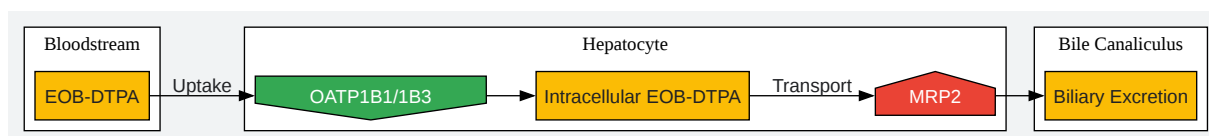
- Pre-contrast Imaging: T1-weighted and T2-weighted sequences are acquired.
- Contrast Administration: A dose of 0.025 mmol/kg of gadoxetate disodium is injected intravenously.[13]
- Dynamic Phase Imaging: Arterial, portal venous, and transitional phases are captured immediately following contrast injection to assess the vascular characteristics of lesions.[13]
- Hepatobiliary Phase Imaging: This phase is typically acquired 20 minutes after contrast injection.[13][14] The uptake of **EOB-DTPA** by hepatocytes leads to enhancement of normal liver parenchyma, making non-enhancing or hypo-enhancing lesions more conspicuous.

Data Analysis:

- Economic Evaluation: Decision-tree or Markov models are commonly used to simulate the clinical pathway from initial diagnosis to treatment.[2][5][11] These models incorporate probabilities for different outcomes (e.g., correct diagnosis, need for further imaging, unnecessary surgery) and associated costs.[2][5]
- Diagnostic Accuracy: Sensitivity, specificity, positive predictive value (PPV), and negative predictive value (NPV) are calculated by comparing imaging findings with a reference standard, which is often histopathological analysis of resected specimens or long-term follow-up.[3][15]

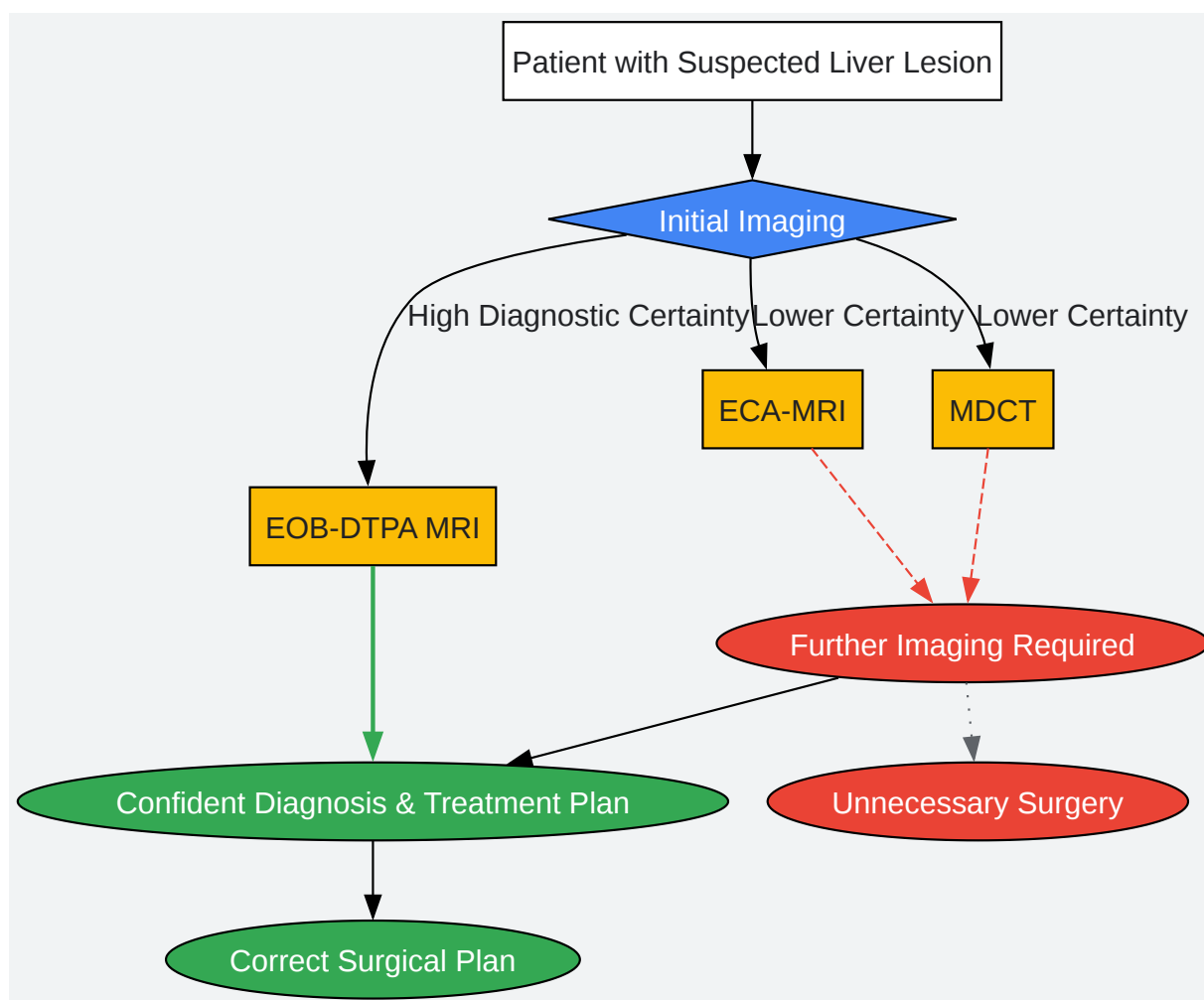
Visualizing the Science Behind EOB-DTPA MRI

To better understand the mechanisms and workflows discussed, the following diagrams have been generated.



[Click to download full resolution via product page](#)

Caption: **EOB-DTPA** uptake and excretion pathway in a normal hepatocyte.



[Click to download full resolution via product page](#)

Caption: Simplified diagnostic workflow and outcomes with different initial imaging modalities.

EOB-DTPA MRI	ECA-MRI	MDCT
+ Higher Initial Cost	- Moderate Initial Cost	- Lower Initial Cost
+ Superior Diagnostic Accuracy	- Lower Diagnostic Accuracy vs. EOB	- Lower Diagnostic Accuracy vs. MRI
+ Reduced Need for Further Imaging	- Higher Need for Further Imaging	- Highest Need for Further Imaging
+ Fewer Unnecessary Surgeries	- More Unnecessary Surgeries	- More Unnecessary Surgeries
= Overall Cost-Effective	= Less Cost-Effective	= Less Cost-Effective

[Click to download full resolution via product page](#)

Caption: Logical comparison of the cost-effectiveness attributes of liver imaging modalities.

Mechanism of Action of EOB-DTPA

Gadoxetate disodium is a gadolinium-based contrast agent that exhibits a dual mechanism of action.^[16] After intravenous injection, it initially distributes in the extracellular space, allowing for dynamic phase imaging similar to conventional contrast agents. Subsequently, approximately 50% of the injected dose is selectively taken up by functional hepatocytes via organic anion-transporting polypeptides (OATPs), specifically OATP1B1 and OATP1B3.^{[16][17]} This hepatocyte-specific uptake results in the enhancement of normal liver parenchyma in the hepatobiliary phase. Most malignant liver lesions, including metastases and many HCCs, lack functional hepatocytes or these specific transporters and therefore do not accumulate the contrast agent, appearing as hypointense areas against the bright liver background.^[16]

Conclusion

The evidence strongly suggests that while the upfront cost of **EOB-DTPA** enhanced MRI may be higher than other imaging modalities, its superior diagnostic accuracy, particularly for small lesions, leads to significant downstream cost savings. By reducing the need for additional imaging and preventing unnecessary invasive procedures, **EOB-DTPA** MRI represents a cost-effective initial imaging strategy for the evaluation of focal liver lesions in appropriate patient populations. For researchers and drug development professionals, understanding the economic and clinical value of advanced imaging techniques like **EOB-DTPA** MRI is crucial for designing efficient clinical trials and health economic models.

Need Custom Synthesis?

BenchChem offers custom synthesis for rare earth carbides and specific isotopic labeling.

Email: info@benchchem.com or [Request Quote Online](#).

References

- 1. Gd-EOB-DTPA-Enhanced MRI for Detection of Liver Metastases from Colorectal Cancer: A Surgeon's Perspective! - PMC [pmc.ncbi.nlm.nih.gov]
- 2. Health economic evaluation of Gd-EOB-DTPA MRI vs ECCM-MRI and multi-detector computed tomography in patients with suspected hepatocellular carcinoma in Thailand and South Korea - PubMed [pubmed.ncbi.nlm.nih.gov]
- 3. Diagnostic Accuracy of Gd-EOB-DTPA for Detection Hepatocellular Carcinoma (HCC): A Comparative Study with Dynamic Contrast Enhanced Magnetic Resonance Imaging (MRI) and Dynamic Contrast Enhanced Computed Tomography (CT) - PMC [pmc.ncbi.nlm.nih.gov]
- 4. auntminnieeurope.com [auntminnieeurope.com]
- 5. Health-economic evaluation of three imaging strategies in patients with suspected colorectal liver metastases: Gd-EOB-DTPA-enhanced MRI vs. extracellular contrast media-enhanced MRI and 3-phase MDCT in Germany, Italy and Sweden - PubMed [pubmed.ncbi.nlm.nih.gov]
- 6. Cost evaluation of gadoxetic acid-enhanced magnetic resonance imaging in the diagnosis of colorectal-cancer metastasis in the liver: Results from the VALUE Trial - PMC [pmc.ncbi.nlm.nih.gov]
- 7. Health economic assessment of Gd-EOB-DTPA MRI versus ECCM-MRI and multi-detector CT for diagnosis of hepatocellular carcinoma in China - PMC [pmc.ncbi.nlm.nih.gov]
- 8. A controlled study of Gd-EOB-DTPA-enhanced MRI compared with enhanced CT in assessing lesion status after TACE for hepatocellular carcinoma - PMC [pmc.ncbi.nlm.nih.gov]
- 9. radiopaedia.org [radiopaedia.org]
- 10. Gadoxetate-Enhanced MRI as a Diagnostic Tool in the Management of Hepatocellular Carcinoma: Report from a 2020 Asia-Pacific Multidisciplinary Expert Meeting - PMC [pmc.ncbi.nlm.nih.gov]
- 11. researchgate.net [researchgate.net]
- 12. frontiersin.org [frontiersin.org]

- 13. The Diagnostic Performance of Liver MRI without Intravenous Contrast for Detecting Hepatocellular Carcinoma: A Case-Controlled Feasibility Study - PMC [pmc.ncbi.nlm.nih.gov]
- 14. radiopaedia.org [radiopaedia.org]
- 15. ovid.com [ovid.com]
- 16. What is the mechanism of Gadoxetate Disodium? [synapse.patsnap.com]
- 17. medscape.com [medscape.com]
- To cite this document: BenchChem. [EOB-DTPA Enhanced MRI: A Cost-Effectiveness Analysis in Liver Imaging]. BenchChem, [2025]. [Online PDF]. Available at: [https://www.benchchem.com/product/b3021170#comparative-cost-effectiveness-of-eob-dtpa-mri-in-liver-imaging]

Disclaimer & Data Validity:

The information provided in this document is for Research Use Only (RUO) and is strictly not intended for diagnostic or therapeutic procedures. While BenchChem strives to provide accurate protocols, we make no warranties, express or implied, regarding the fitness of this product for every specific experimental setup.

Technical Support: The protocols provided are for reference purposes. Unsure if this reagent suits your experiment? [[Contact our Ph.D. Support Team for a compatibility check](#)]

Need Industrial/Bulk Grade? [Request Custom Synthesis Quote](#)

BenchChem

Our mission is to be the trusted global source of essential and advanced chemicals, empowering scientists and researchers to drive progress in science and industry.

Contact

Address: 3281 E Guasti Rd
Ontario, CA 91761, United States
Phone: (601) 213-4426
Email: info@benchchem.com